



Acta Scientiarum. Biological Sciences

ISSN: 1679-9283

eduem@uem.br

Universidade Estadual de Maringá

Brasil

Aversi-Ferreira, Tales Alexandre; Pereira-de-Paula, Jarbas; de Souza Lima-e-Silva, Mário; Silva, Zenon

Anatomy of the arteries of the arm of *Cebus libidinosus* (Rylands et al., 2000) monkeys

Acta Scientiarum. Biological Sciences, vol. 29, núm. 3, 2007, pp. 247-254

Universidade Estadual de Maringá

.png, Brasil

Available in: <http://www.redalyc.org/articulo.oa?id=187115762002>

- How to cite
- Complete issue
- More information about this article
- Journal's homepage in redalyc.org

redalyc.org

Scientific Information System

Network of Scientific Journals from Latin America, the Caribbean, Spain and Portugal

Non-profit academic project, developed under the open access initiative

# Anatomy of the arteries of the arm of *Cebus libidinosus* (Rylands *et al.*, 2000) monkeys

Tales Alexandre Aversi-Ferreira\*, Jarbas Pereira-de-Paula, Mário de Souza Lima-e-Silva and Zenon Silva

Laboratório de Neurociências e Comportamento de Primatas, Instituto de Ciências Biológicas III, Universidade Federal de Goiás, Campus II (Samambaia), 74001-970, Goiânia, Goiás, Brasil. \*Author for correspondence. E-mail: [aversiferreira@yahoo.com.br](mailto:aversiferreira@yahoo.com.br)

**ABSTRACT.** The *Cebus* monkey displays a high capacity for adaptation to urban environments, and its high level of encephalization has generated great interest by scientific community to study it. The study of the vascularization of the arm of *Cebus* is important because of its arboreal habits. Twenty-four animals donated by Ibama (Brazilian Institute for the Environment and Renewable Natural Resources) from the city of Sete Lagoas, Minas Gerais State, Brazil, and housed in the anatomy collections of the Federal University of Uberlândia (UFU) and the Federal University of Goiás (UFG) were used. The arterial system of these animals was injected with coloring latex, after which the arteries were dissected using stereoscopic microscope or the naked eye. In general terms, the findings on the brachial vessels of the *Cebus* monkey are identical to those found in humans and in other primates. In specific terms, the most outstanding variation was the small size or the absence of the brachial artery in *Cebus*. The arterial model of *Cebus* corroborates its arboreal behavior and constant use of its thoracic limbs.

**Key words:** anatomy, *Cebus libidinosus*, arteries of the arm.

**RESUMO. Anatomia das artérias do braço do macaco *Cebus libidinosus* (Rylands *et al.*, 2000).** O macaco *Cebus* possui alta capacidade de adaptação em ambientes urbanos e o seu elevado índice de encefalização tem gerado grande interesse por parte da comunidade científica em estudá-lo. A importância do estudo da vascularização do braço desses animais é em virtude do seu hábito arbóreo. Foram usados 24 animais doados pelo Instituto Brasileiro do Meio Ambiente (Ibama) de Sete Lagoas, Estado de Minas Gerais, Brasil, depositados nas coleções anatômicas da Universidade Federal de Uberlândia (UFU) e Universidade Federal de Goiás (UFG). O sistema arterial dos espécimes foi injetado com látex corado e, posteriormente, as artérias foram dissecadas com o auxílio de microscópio estereoscópico ou a olhos desarmados. Em termos gerais, os achados em *Cebus* acerca de vasos braquiais são idênticos aos encontrados em humanos e outros primatas. Em termos específicos, o fato marcante foi a ocorrência de uma curta artéria braquial, que em alguns casos pode estar ausente, nos *Cebus*. O modelo arterial braquial em *Cebus* corrobora seu comportamento arbóreo e constante uso dos membros torácicos.

**Palavras-chave:** anatomia, *Cebus libidinosus*, artérias do braço.

## Introduction

There are similarities between monkeys and humans in their bodily structure, biped nature and in the presence of five fingers in each hand (Champneys, 1871). Monkeys are very close to humans under phylogenetic, morphologic, physiological and biochemical aspects. Such aspects justify the choice of the *Cebus* monkey for anatomical and behavioral studies. The *Cebus* genus features the largest geographical distribution among neotropical primate species, and according to Lopes (2004) is observed from Colombia and Venezuela all the way to northern Argentina; inhabits tropical, subtropical and riverside

forests, as well as savannah and semi-arid regions in Brazil. Cognitive and very skilled, they display an immense capacity to handle tools for obtaining food and amusement, and such activities are observed in both captivity and in the wild (Breseida and Ottoni, 2001; Resende and Ottoni, 2002).

These animals show social habits of food division among members of the group, similarly to humans and chimpanzees (Waal, 2005). Knowledge of their macroscopic internal structure will provide data for histological and biochemical studies, as well as aiding in ethological studies and the preservation of the species. Some studies regarding encephalic

vascularization (Ferreira and Prada, 2001; Silva and Ferreira, 2002a; Silva and Ferreira, 2002b; Neto and Ferreira, 2002; Silva and Ferreira, 2003; Silva *et al.*, 2003) and vascularization of the submandibular gland (Oliveira *et al.*, 2000) of *Cebus* have been carried out; however, there is no data available on limb vascularization. We have been studying the limb structures of capuchin monkeys (Aversi-Ferreira *et al.*, 2005a; Aversi-Ferreira *et al.*, 2005b; Aversi-Ferreira *et al.*, 2006; Aversi-Ferreira *et al.*, 2007); and studies on the cortical physiology were also carried out (Lima *et al.*, 2003).

For this study, we characterized anatomically the main vessels and their branches located in the arm of the *Cebus* monkey, taking into consideration their frequency, number, origin and distribution. The data was related with these same vessels found in specialized literature in humans (Gray, 1988; Williams *et al.*, 1979; Hollinshead, 1980; Keen, 1961; Karlsson and Niechajev, 1982; Testut and Latarjet, 1958), in specialized literature on other non-human primates (Glidden and Garis, 1936; Urbanowicz and Zaluska, 1966) and also on domestic animals, mainly cats and dogs (Sapra and Dhingra, 1974; Ghoshal and Getty, 1970). The data generated by the anatomical analysis was used as one of the justifications for the brachial motor plasticity of those animals associated with aspects of their behavior.

### Material and methods

In this study, 24 *Cebus libidinosus* (Rylands *et al.*, 2000) monkeys were used (12 females and 12 males), all healthy adults, with deviations as for size and age. They were provided by Ibama (Brazilian Institute for the Environment and Renewable Natural Resources), from the city of Sete Lagoas, Minas Gerais State in 1970, and housed at the anatomy collection of the Federal University of Goiás (UFG). All animals were prepped with injections of Neoprene 601A latex (DuPont) on the femoral artery. The animals were carefully dissected using the naked eye or with the aid of 10x stereoscopic magnification.

### Results

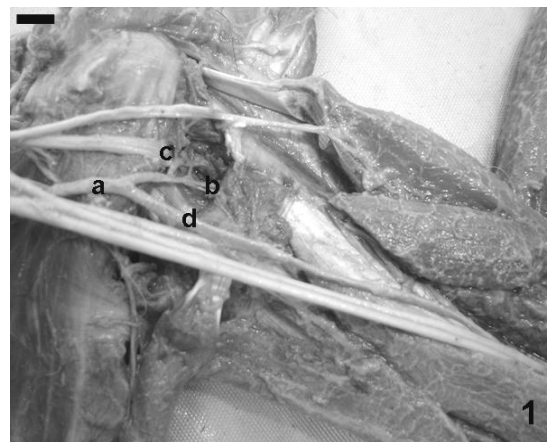
The dissection and description of the arteries that irrigate the thoracic limb of the *Cebus* monkey begins at the point where the subclavian artery emerges underneath the anterior scalene muscle, including, therefore, branches of the third part of the subclavian artery, although some of these vessels are not specific to the thoracic limb, but rather

pertain to the thoracic wall. The continuation of the axillary artery is the brachial artery, which in *Cebus* can be absent or be very short. The radial and ulnar arteries derive directly from the axillary or brachial artery, in most of the cases in the proximal third of the arm.

The radial artery is of smaller caliber and soon after its origin becomes very superficial relative to the ulnar artery and associated nerves of the arm (ulnar and median nerves); it follows a distal path, passing through the cubital fossa towards the forearm. The ulnar artery has a much larger caliber and is located deeper than the radial artery. It follows a distal path covered by the ulnar and median nerves until almost reaching the elbow, when the ulnar artery and the median nerve separate from the ulnar nerve, penetrating the epicondylar foramen of the humerus, arising from it already in the forearm.

### Posterior humeral circumflex artery

In all dissected animals, only one posterior humeral circumflex artery was found. In 42 cases (87.5% – 21 on each side), the posterior humeral circumflex artery formed a common trunk with the anterior humeral circumflex artery (Figure 1).



**Figure 1.** The figure indicates the proximal portion of the *Cebus*' left arm and evidences the humeral circumflex trunk (a) and the anterior humeral circumflex artery (b), posterior humeral circumflex artery (c) and ulnar artery (d). Bar = 1 cm.

In 2 cases (4.2% – one on each side), this artery arose from a common trunk with the thoracodorsal and circumflex scapular arteries. In the remaining 4 cases, 4 different origins were found: in one case (left side), the posterior humeral circumflex artery arose from the axillary artery; in another case, also on the left side, it formed a common trunk with the thoracodorsal artery; in one case on the right side,

this artery arose from a common trunk along with the thoracodorsal and circumflex scapular arteries; while in another case, also on the right side, it formed a common trunk with the circumflex scapular and subscapular arteries. The posterior humeral circumflex artery, immediately after its origin, follows a trajectory towards the quadrangular space, crosses it and sends off branches to the deltoid, teres major, teres minor and triceps brachii muscles, and part of the shoulder joint.

#### Anterior humeral circumflex artery

In all cases, only one anterior humeral circumflex artery was found. In 42 cases (87.5% – 21 on each side), this artery arose from a common trunk with the posterior humeral circumflex artery (Figure 1). The anterior humeral circumflex artery is much smaller than the posterior humeral circumflex artery and after its origin follows a craniolateral path sending off small branches on the shoulder joint and the deltoid muscle.

#### Humeral circumflex trunk

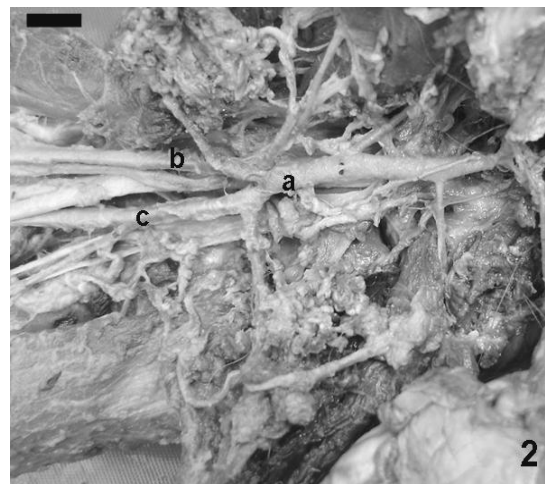
The humeral circumflex trunk, whose terminal branches are the humeral circumflex arteries (Figure 1), was found in 87.5% of dissected arms, with variable origins. In 20 cases (41.6% – 12 on the right side and 8 of the left), the trunk arose directly from the axillary artery. In 13 cases (27.1% – 8 on the left side and 5 of the right), it formed a larger trunk, along with the thoracodorsal and circumflex scapular arteries and subscapular branches. In 4 cases (8.3% – 2 on each side), it formed a larger trunk with the thoracodorsal and circumflex scapular arteries. In 3 cases (6.3% – all on the left side), this trunk is also formed by the circumflex scapular and subscapular arteries. In the 2 remaining cases (4.2% – both on the right side), the trunk emerged from the radial artery, forming a trunk with the circumflex scapular artery.

#### Radial artery

The radial artery (Figures 2, 3 and 4) was found in all dissected arms, and we did not find more than one artery on any of the dissected arms.

Considering human nomenclature – and consequently the same references – when naming the arteries of the arm of the *Cebus* monkey, a brachial artery was not found in this animal (or is very short), given that in 41 cases (85.4%), the axillary artery gives origin to the radial and ulnar arteries at the level of the teres major muscle tendon (therefore at the end of the axillary artery). In 6 cases (10.4% – 5 on the left side and 1 on the right), this

branching took place at a higher level, in the middle of the axillary area. In one case, this ramification took place at a lower level, very close to the elbow. The radial artery, very close to its origin, anteromedially bypasses the median and ulnar nerves, becoming superficial in relation to them, and then follows an ever-more superficial trajectory, between the biceps brachii and triceps brachii muscles, in such a way that it can be found immediately underneath the skin in the distal half of arm. In its trajectory through the arm, it sends off several small muscular branches, destined mainly to the biceps brachii muscle. In its distal third, already near the elbow joint, it sends off one or two larger branches – the superior ulnar collateral arteries.

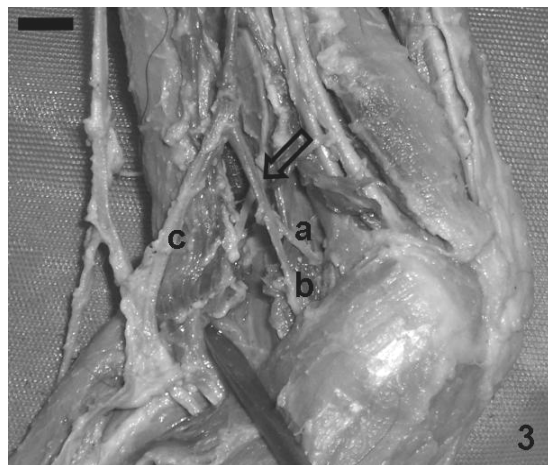


**Figure 2.** The figure of the *Cebus*' right arm evidences the absence of the brachial artery and the division of the axillary artery into radial and ulnar arteries, in the proximal portion of the arm. a. axillary artery; b. radial artery; c. ulnar artery. Bar = 1 cm.

#### Superior ulnar collateral artery

In all studied arms, only one superior ulnar collateral artery was found (Figure 3). In 38 cases (79.2% – 19 on each side), this artery arose from the radial artery. In the remaining cases (16.7% – 4 on each side), it arose from the ulnar artery.

Immediately after its origin, the superior ulnar collateral artery follows a distal-medial trajectory towards the humeral medial epicondyle and over the medial surface of the elbow joint. Along with the inferior ulnar collateral artery, it forms a vast vascular network, which anastomoses with itself and with the recurrent ulnar arteries. The superior ulnar collateral artery sends off small branches for the vascularization of distal portions of biceps and triceps brachii muscles, and also for proximal parts of the forearm muscles.



**Figure 3.** The figure evidences, on the right elbow of a Cebus, the (a) superior ulnar collateral, (b) inferior ulnar collateral, and (c) radial arteries. The arrow indicates the common originating trunk of the ulnar collateral arteries. Bar = 1 cm.

#### Inferior ulnar collateral artery

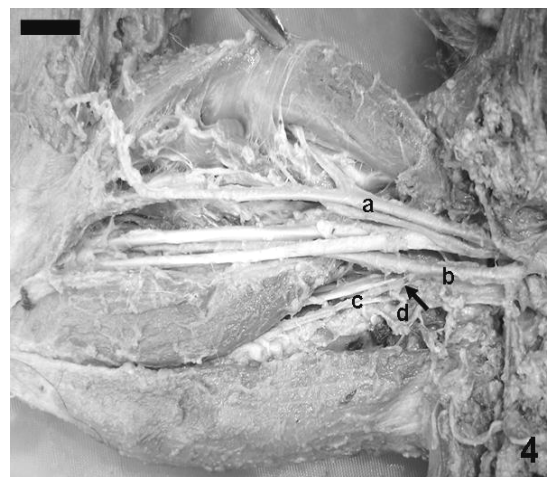The inferior ulnar collateral artery was found in 46 cases (95.8% – 23 on each side). In 41 cases (85.4% – 21 on the left side and 20 on the right), this artery originated from the radial artery (Figure 3). In five cases (10.4% – 3 on the right side and on the 2 left), this artery arose from the ulnar artery. In 14 cases (29.2% – 7 on each side), the two ulnar collateral arteries arose from a common trunk, and in all cases this trunk originated from the radial artery (Figure 3). The trajectory and distribution of the inferior ulnar collateral artery are similar to those of the superior ulnar collateral artery.

#### Ulnar artery

In all cases, only one artery was found (Figures 1, 2, 4 and 5). The ulnar artery is the main branch of the axillary artery, and seems to be its direct continuation. After its origin, this artery follows a distal trajectory, contiguous to the median and ulnar nerves, connected to them by common fascia. It lodges itself in the muscular groove between the medial head of triceps brachii muscle. In the distal third of the arm this artery tilts medially, always contiguous to both nerves. Near the elbow, the ulnar artery and median nerve separate from the ulnar nerve, and both enter the epicondylar foramen of the humerus. In its brachial path, the ulnar artery sends off a large branch in its proximal third: the profunda brachii artery, some smaller muscular branches and, occasionally one of the ulnar collateral arteries.

#### Profunda brachii artery

The profunda brachii artery (Figure 4) was found in 47 cases (97.9% – 23 on the left side and 24 on the right). In all 47 cases, this artery arose from the ulnar artery.



**Figure 4.** The figure shows, on the right arm of a Cebus, the (a) radial, (b) ulnar, (c) profunda brachii and (d) middle collateral arteries. The arrow indicates the origin of the middle collateral artery from the profunda brachii artery. Bar = 1 cm.

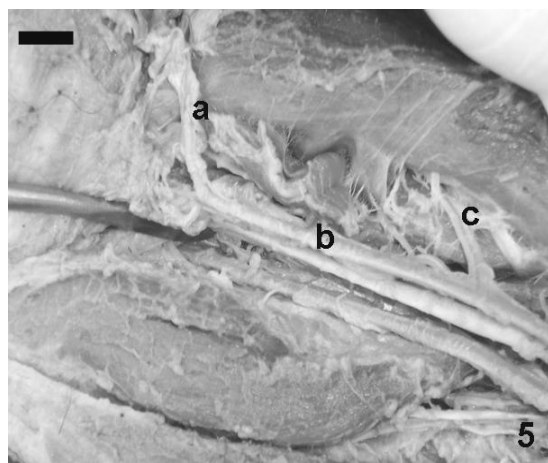
The profunda brachii artery is the main responsible for supplying blood to arm muscles. Immediately after its origin, usually, this artery normally sends off two or three muscular branches, which are distributed in adjacent muscles and tissues.

#### Middle collateral artery

In 42 cases (87.5%), only one middle collateral artery was found (Figure 4). In 40 cases (83.3%) this artery arose from the profunda brachii artery (Figure 4) and in the other two cases (4.2%) it emerged from the ulnar artery. The middle collateral artery is located posterior to the radial collateral artery. It penetrates the triceps brachii muscle and follows distally towards the olecranon where it forms, in conjunction with the interosseous recurrent artery, an arterial network over the elbow and sends off muscular branches along its trajectory.

#### Radial collateral artery

The radial collateral artery was found in all dissected arms (Figure 5). In 44 cases (91.7% – 23 on the left side and 21 on the right), this artery arose from the profunda brachii artery.



**Figure 5.** The figure evidences, in the right arm of a *Cebus*, the (a) middle collateral, (b) and ulnar arteries, and (c) a branch of the ulnar artery to the brachial muscle. Bar = 1 cm.

In four cases (8.3% – three on the right side and one on the left), this artery arose from the ulnar artery. The radial collateral artery is the larger of the two terminal branches of the profunda brachii artery. The radial collateral artery is located anterior to the middle collateral artery and follows a distal trajectory until it penetrates the triceps brachii muscle contiguous to the radial nerve, and emerges in the lateral face of arm. The radial collateral artery then travels superficially and contributes to an anastomosis around the elbow, and reconnecting with the radial recurrent artery. In its trajectory through the arm, it sends off several muscular branches.

## Discussion

### Posterior and anterior humeral circumflex arteries

According to Gray (1988), Williams *et al.* (1979), Testut and Latarjet (1958), these arteries arise directly from the axillary artery in humans. To Gray (1988), these arteries are distributed in the deltoid muscle and shoulder joint. Williams *et al.* (1979) and Testut and Latarjet (1958) add that the teres major and minor muscles, as well as part of the triceps brachii muscle are supplied by these arteries. To Gardner *et al.* (1978), Hollinshead (1980) and Keen (1961) these arteries have variable origins, and can emerge from the axillary artery through a common trunk among them or from the subscapular artery; but these authors do not clarify their distribution. In chimpanzees, according to Glidden and De Garis (1936), these arteries originate from a common trunk among them and from the subscapular artery.

In rhesus and cynomolgus, Urbanowicz and

Zaluska (1966) describe one common trunk between the humeral circumflex arteries, with the subscapular artery or another vessel, or isolated from the axillary artery, Bang (1936) cites that saki monkeys have only one posterior humeral circumflex artery. None of the authors clarified the distribution of these arteries. In buffalo, according to Sapra and Dhingra (1974), the posterior humeral circumflex artery emerges from the subscapular artery and supplies the teres major and minor muscles, triceps brachii, infraspinatus and deltoid muscles, as well as part of the shoulder joint.

The anterior humeral circumflex artery arises from the brachial artery and supplies the coracobrachialis muscle, part of the triceps brachii and shoulder. On domestic animals, according to Ghoshal and Getty (1970), these arteries have different origin and distribution, depending on the species. In our results on *Cebus*, we found these arteries in all studied cases; there is always one anterior and one posterior artery. In 87.5% of cases, the two arteries originated from a common trunk among them (Figure 1). In the remaining cases, these arteries had variable origin. This data coincides with findings on monkeys, but not with humans. In regards to the distribution of the arteries, our data is in accordance with that found in humans, other monkeys and domestic animals.

### Humeral circumflex trunk

The humeral circumflex trunk is cited on humans by some authors (Gardner *et al.*, 1978; Hollinshead, 1980) and on monkeys (Glidden and De Garis, 1936; Urbanowicz and Zaluska, 1966). On *Cebus*, this trunk was found in 87.5% of samples in our study (Figure 1), and featured variable origins from the axillary artery or other vessels.

### Radial and ulnar arteries

On humans, these arteries generally originate in the ulnar fossa past the elbow joint, by bifurcation of the brachial artery, but can take place in higher positions (Gray, 1988; Williams *et al.*, 1979; Hollinshead, 1980; Keen, 1961; Karlsson and Niechajev, 1982; Testut and Latarjet, 1958). These results on humans are clearly different from those found on *Cebus*, because these arteries originated in higher levels by bifurcation of the axillary artery (85.4%), with the ulnar artery as the major branch of the axillary artery. On chimpanzees, the origin of these arteries is the same as in humans (Glidden and De Garis, 1936).

### Superior ulnar collateral artery

In humans, the superior ulnar collateral artery originates in the medial part of the brachial artery, but it also can originate from the profunda brachii artery, and in both cases anastomoses around the elbow joint and reconnects with the posterior ulnar recurrent artery (Testut and Latarjet, 1958; Gardner *et al.*, 1978; Williams *et al.*, 1979; Hollinshead, 1980; Gray, 1988). On chimpanzees, this artery is a branch of the brachial artery and ends in the triceps brachii and dorsoepitrocLEAR muscles (Glidden and De Garis, 1936; Aversi-Ferreira *et al.*, 2005b). Bang (1936) cites only one superior ulnar collateral artery and describes it as a branch of the ulnar artery and ends in the arm muscles and around the elbow. Ghoshal and Getty (1970) found one or two superior ulnar collateral arteries that supply the muscles of the arm and forearm in domestic animals.

In our results, we found this artery in 95.8% of samples – always only one – but in 79.2% of studied cases it originated from the radial artery. In 16.7% of studied cases, it arose from the ulnar artery. Surprisingly, this data is discordant in relation to humans, other monkeys and domestic animals, possibly due to the different manner of origin of the radial and ulnar arteries, much closer to the axillary area. As for the distribution of this artery, our data is in agreement with that found in the cited literature for domestic animals, other monkeys and humans; that is, this artery sends off branches to arm and forearm muscles and anastomoses around the olecranon.

### Inferior ulnar collateral artery

On humans, the inferior ulnar collateral artery arises from the brachial artery and displays a trajectory and distribution similar to the superior ulnar collateral artery (Testut and Latarjet, 1958; Gardner *et al.*, 1978; Williams *et al.*, 1979; Hollinshead, 1980; Gray, 1988). On chimpanzees, Glidden and De Garis (1936), mention the origin and distribution of this vessel as similar to the superior ulnar collateral artery, which is in agreement with our results with *Cebus*, with the difference that in 85.4% of cases it originated from the radial artery, and in 29.2% both superior and inferior form a common trunk.

### Profunda brachii artery

The profunda brachii artery is the major branch from the brachial artery. It is distributed in the posteromedial musculature of the arm and ends to form the middle collateral and radial arteries in humans (Testut and Latarjet, 1958; Williams *et al.*,

1979; Hollinshead, 1980; Gray, 1988).

According to Gardner *et al.* (1978), it can originate from the brachial, subscapular or axillary arteries, and after supplying the deltoid muscle it ends in the middle collateral and radial arteries. Keen (1961) states that its origin is quite variable. The results described in chimpanzees (Glidden and De Garis, 1936), saki monkeys (Bang, 1936), rhesus and cynomolgus (Urbanowicz and Zaluska, 1966), are similar to humans, but Bang (1936) does not mention the terminal branches of the profunda brachii artery. The data described by Sapra and Dhingra (1974) on buffalo and by Ghoshal and Getty (1970) on domestic animals is similar to our description for humans and monkeys.

In our observations, we found this artery in 97.9% of cases – always only one and originating from the ulnar artery – possibly because of the absence of a brachial artery, given the bifurcation of the axillary artery into the radial and ulnar arteries. In *Cebus*, the profunda brachii artery is the main responsible for supplying blood to arm muscles, and features terminal branches that are the middle and radial collateral arteries. These results are equal to humans and other monkeys.

### Radial and middle collateral arteries

These arteries are terminal branches of the profunda brachii artery on humans feeding arm muscles and, along with the interosseous and radial recurrent arteries, anastomose around the elbow joint (Testut and Latarjet, 1958; Gardner *et al.*, 1978; Williams *et al.*, 1979; Hollinshead, 1980; Gray, 1988). These results are in agreement with what we found in *Cebus*, and also with similar descriptions on chimpanzees (Glidden and De Garis, 1936), rhesus and cynomolgus (Urbanowicz and Zaluska, 1966).

### General aspects

The arteries studied in *Cebus* for this work were associated and/or compared with the same structures existent in anatomy literature on humans, domestic animals and other non-human primates. The most data was obtained, in decreasing order, from literature on humans, domestic animals and other non-human primates. We observed that bibliographical analyses gave basis to interesting correlations between *Cebus*' habits and its arterial anatomic structures. The intense use of the thoracic limbs by *Cebus* for locomotion among trees, in the manipulation of objects, food and tools (sometimes very heavy, such as rocks) used to break coconuts (Resende and Ottoni, 2002), demands great muscular effort and, consequently, the need for

more effective vascularization of blood distribution to the muscles of the arm, as demonstrated by the ample surface generated by the ulnar and radial arteries starting from the proximal end of the arm, in substitution of the small or absent brachial artery.

The general structure of vessels in *Cebus* differs from the pattern found in humans and chimpanzees, which is hypothetically associated to the loss of tree-dwelling habits by the latter two (Hickman *et al.*, 2003), who use their thoracic limbs as structures for fine manipulation (Lopes, 2004). The return of venous blood to the heart depends on, among other factors, cardiac power. In chimpanzees and humans, the thoracic limb is most often turned downward; therefore the presence of a brachial artery facilitates the return of venous blood by constituting a single tube up to the elbow, without dispersing blood pressure up to that point. It is for this reason that this artery is used in humans to measure blood pressure, as is commonly known. In *Cebus*, whose thoracic limbs spend part of the time turned upward due to their tree-dwelling habits, the brachial artery is small or absent, as the return of venous blood from the thoracic limbs to the heart is already aided by gravity.

## Conclusion

In general terms, the findings on the vessels of the arm of the *Cebus* monkey are similar to those found in humans and in other primates. However, specifically, the most outstanding variation was the small size or the absence of the brachial artery in *Cebus*. The arterial pattern found in *Cebus* is consistent, in anatomical and physiological terms, with its tree-dwelling behavior and constant use of the thoracic limbs for locomotion.

## References

- AVERSI-FERREIRA, T.A. *et al.* Estudo anatômico dos músculos profundos do antebraço de *Cebus apella* (Linnaeus, 1766). *Acta Sci. Biol. Sci.*, Maringá, v. 27, n. 3, p. 297-301, 2005a.
- AVERSI-FERREIRA, T.A. *et al.* Anatomia comparativa dos nervos do braço de *Cebus apella*. Descrição do músculo dorsoepitrocLEAR. *Acta Sci. Biol. Sci.*, Maringá, v. 27, n. 3, p. 291-296, 2005b.
- AVERSI-FERREIRA, T.A. *et al.* Estudo anatômico dos músculos flexores superficiais do antebraço no macaco *Cebus apella*. *Biosci. J.*, Uberlândia, v. 22, n. 1, p. 139-144, 2006.
- AVERSI-FERREIRA, T.A. *et al.* Estudo anatômico das artérias do ombro de *Cebus libidinosus* (Rylands, 2000; *primates – cebidae*). *Cienc. Anim. Bras.*, Goiânia, v. 8, n. 2, p. 273-284, 2007.
- BANG, F.B. Observations on limb arteries of the Woolly Monkey (*Lagothrix lagotricha*). *Anat. Rec.*, Charleston, v. 66, n. 4, p. 387-395, 1936.
- BRESEIDA, D.R.; OTTONI, E.B. Observational learning in the manipulation of a problem-box by tufted capuchin monkeys (*Cebus apella*). *Rev. Etol.*, São Paulo, v. 3, n. 2, p. 3-13, 2001.
- CHAMPNEYS, F. On the muscles and nerves of a chimpanzee (*Troglodytes niger*) and a *Cynocephalus anubis*. *J. Anat. Physiol.*, London, v. 6, n. 1, p. 176-211, 1871.
- FERREIRA, J.R.; PRADA, I.L.S. Nomenclatura proposta para denominar as artérias da base do encéfalo do macaco-prego (*Cebus apella* L., 1766). *Acta Sci. Biol. Sci.*, Maringá, v. 23, n. 2, p. 635-643, 2001.
- GARDNER, R. *et al.* Anatomia: estudo regional do corpo humano. 4. ed. Rio de Janeiro: Guanabara Koogan, 1978.
- GHOSHAL, N.G.; GETTY, R. Comparative morphological study of the major arterial supply to the thoracic limb of the domestic animals. (*Bos taurus*, *Ovis aries*, *Capra hircus*, *Sus scrofa domestica*, *Equus caballus*). *Anat. Anz.*, Jena, v. 127, n. 4, p. 422-443, 1970.
- GLIDDEN, E.M.; DE GARIS, C.F. Arteries of the Chimpanzee. I. The aortic arch; II. Arteries of the upper extremity; III. The descending aorta; IV. Arteries of the lower extremity. *Am. J. Anat.*, New York, v. 58, n. 2, p. 501-527, 1936.
- GRAY, H. *GRAY/Anatomia*. 29. ed. Rio de Janeiro: Guanabara Koogan, 1988.
- HICKMAN, C.P. *et al.* *Animal diversity*. 3<sup>th</sup> ed. New York: McGraw Hill, 2003.
- HOLLINSHEAD, W.H. *Livro texto de anatomia humana*. São Paulo: Harper and Row do Brasil, 1980.
- KARLSSON, S.; NIECHAJEV, A. Arterial anatomy of the upper extremity. *Acta Radiol.*, Stockholm, v. 23, n. 2, p. 115-121, 1982.
- KEEN, J.A. A study of the arterial variations in the limbs with special reference to symmetry of vascular patterns. *Am. J. Anat.*, New York, v. 108, n. 5, p. 245-261, 1961.
- LIMA, B. *et al.* Modulation by context of a scene in monkey anterior infratemporal cortex a saccadic eye movement task. *An. Acad. Bras. Cienc.*, Rio de Janeiro, v. 75, n. 1, p. 71-76, 2003.
- LOPES, R.J. Gênio da selva. *Sci. Am. Bras.*, São Paulo, v. 3, n. 27, p. 24-32, 2004.
- MOULIAS, R.; BERAT-MULLER, C.N. The use of monkeys in medical research. *Presse Med.*, Paris, v. 76, n. 24, p. 1201-1202, 1968.
- NETO, E.G.B.S.; FERREIRA, J.R. Estudo anatômico da origem e distribuição dos ramos corticais das artérias cerebrais caudais do encéfalo do macaco-prego (*Cebus apella* L., 1766). *Acta Sci. Biol. Sci.*, Maringá, v. 24, n. 2, p. 639-646, 2002.
- OLIVEIRA, A.S. *et al.* Estudo anatômico do modelo arterial de vasos responsáveis pelo aporte sanguíneo da glândula submandibular da primatas neotrópicas (*Cebus apella* Linnaeus, 1766). *Acta Sci. Biol. Sci.*, Maringá, v. 22, n. 2, p. 573-579, 2000.



- RESENDE, B.D.; OTTONI, E.B. Brincadeira e aprendizagem do uso de ferramentas em macacos-prego (*Cebus apella*). *Estud. Psicol.*, Natal, v. 7, n. 1, p. 173-180, 2002.
- RYLANDS, A.B. *et al.* An assessment of the diversity of new world primates. *Neotrop. Primat.*, Washington, D.C., v. 8, n. 2, p. 61-93, 2000.
- SAPRA, R.P.; DHINGRA, L.D. The Blood Vessels of the thoracic limb of buffalo (*Bubalus bubalis*). *Anat. Anz.*, Jena, v. 135, n. 1-2, p. 116-139, 1974.
- SILVA, R.A.; FERREIRA, J.R. Estudo das artérias cerebelares do macaco-prego: considerações sobre a nomenclatura (*Cebus apella* L., 1766). *Braz. J. Vet. Res. Anim. Sci.*, São Paulo, v. 39, n. 6, p. 296-300, 2002a.
- SILVA, R.A.; FERREIRA, J.R. Morfologia da artéria cerebelar superior do macaco-prego (*Cebus apella* L., 1766). *Acta Sci. Biol. Sci.*, Maringá, v. 24, n. 3, p. 687-695, 2002b.
- SILVA, R.A.; FERREIRA, J.R. Estudo anatômico das artérias cerebelares inferiores rostrais da macaco-prego (*Cebus apella* L., 1766). *Primates – Cebidae. Publ. Avul. Inst. Pau Brasil*, São Paulo, v. 7, p.15-23, 2003.
- SILVA, R.A. *et al.* Estudo anatômico das artérias cerebelares inferiores caudais da macaco-prego (*Cebus apella* L., 1766). *Arq. Cienc. Saúde Unipar*, Umuarama, v. 7, n. 2, p. 107-112, 2003.
- TESTUT, L.; LATARJET, A. Sistema de la arteria aorta. In: TESTUT, L.; LATARJET, A. (Ed.). *Tratado de anatomía humana*. 9. ed. Barcelona: Salvat, 1958. v. 2. p. 261-304.
- URBANOWICZ, Z.; ZALUSKA, S. Various patterns of the branching of the axillary artery in *Macacus rhesus* and *Macacus cynomolgus*. *Ann. Univ. Curie*, Lublin, v. 21, n. 1, p. 1-15, 1966.
- WAAL, F.B.M. Como os animais fazem negócios. *Sci. Am. Brasil.*, São Paulo, v. 4, n. 36, p. 68-75, 2005.
- WILLIAMS, P.L. *et al.* *GRAY/Anatomia*. 37. ed. Rio de Janeiro: Guanabara Koogan, 1979.

Received 14 May 2006.

Accepted 10 March, 2007.