

English version

da Silva Silvestre, Jose Manoel; Barbosa Trevisan, Fernando; Sardinha, Wander Eduardo; Moraes Filho, Domingos; Durante Ramires, Eduardo; Dias, Silfayner Victor Mathias; Matsuda, Henrique  
Tratamento endovascular da doença venosa oclusiva central: experiência de um centro  
Jornal Vascular Brasileiro, vol. 13, núm. 2, abril-junio, 2014, pp. 94-100  
Sociedade Brasileira de Angiologia e de Cirurgia Vascular  
São Paulo, Brasil

Available in: <http://www.redalyc.org/articulo.oa?id=245031482004>



*Jornal Vascular Brasileiro*,  
ISSN (Printed Version): 1677-5449  
[jvascbr.ed@gmail.com](mailto:jvascbr.ed@gmail.com)  
Sociedade Brasileira de Angiologia e de Cirurgia  
Vascular  
Brasil

How to cite

| Complete issue

| More information about this article

| Journal's homepage

**www.redalyc.org**

Non-Profit Academic Project, developed under the Open Access Initiative

# Endovascular treatment of occlusive central venous disease: one center's experience

## *Tratamento endovascular da doença venosa oclusiva central: experiência de um centro*

José Manoel da Silva Silvestre<sup>1</sup>, Fernando Barbosa Trevisan<sup>1</sup>, Wander Eduardo Sardinha<sup>1</sup>, Domingos Moraes Filho<sup>1</sup>, Eduardo Durante Ramires<sup>1</sup>, Silfayner Victor Mathias Dias<sup>1</sup>, Henrique Matsuda<sup>1</sup>

### Abstract

**Introduction:** The majority of cases of stenosis or occlusion of central veins are the result of central catheters, arteriovenous fistulas, neoplasms or traumas and these conditions can cause severe cases of venous hypertension or reduce the flow through fistulas. The objective of this study is to analyze the results of central venous angioplasties conducted at our hospital. **Methodology:** We conducted a retrospective and descriptive study to analyze the results of central venous angioplasties conducted from 2010 to 2012 at a university hospital run by the Universidade Estadual de Londrina, Brazil. We calculated primary and secondary success rates and analyzed whether or not stents were used and complications occurred during a 6-month follow-up period. **Results:** A total of 25 central venous angioplasties were conducted. Twenty-four (96%) of these were because of catheter-related intimal hyperplasia and one was to treat the effects of compression by a tumor. Fifteen (60%) angioplasties were to correct stenosis and ten (40%) were because of occlusions, with a one-hundred percent success rate for all stenosis-related procedures. However, none of the cases of occlusion could be treated endovascularly. Patency during the 6-months follow-up period was 80% after reinterventions. **Conclusions:** Despite good results observed after primary interventions for stenoses, it must be accepted that all current treatment options for chronic occlusive venous disease will, sooner or later, lead to restenosis or occlusion. Venous occlusions constitute a challenge demanding the development of new techniques and new materials. Prevention is paramount, through avoidance of central catheterization and early creation of arteriovenous fistulas.

**Keywords:** angioplasty; stenosis venous; venous hypertension.

### Resumo

**Introdução:** A estenose ou a oclusão de veias centrais ocorre, na maioria das vezes, em consequência de cateteres centrais, fístulas arteriovenosas, neoplasias e traumas, podendo levar a quadros severos de hipertensão venosa e de redução do débito dessas fístulas. O presente trabalho tem como objetivo analisar os resultados obtidos nas angioplastias venosas centrais em nosso hospital. **Metodologia:** Realizamos um estudo retrospectivo, descritivo, analisando os resultados obtidos nas angioplastias venosas centrais realizadas no Hospital Universitário da Universidade Estadual de Londrina durante os anos de 2010 a 2012. Verificamos as taxas de sucesso primário e secundário, a utilização ou não de *stents* e as complicações, analisadas durante um período de acompanhamento de seis meses. **Resultados:** Foram realizadas 25 angioplastias venosas centrais, sendo 24 (96%) por hiperplasia intimal relacionada ao uso de cateteres e uma por compressão tumoral. Destas, 15 (60%) eram estenoses e dez (40%) eram oclusões, obtendo-se sucesso primário técnico em todos os procedimentos relacionados à estenose. Contudo, nenhum caso de oclusão pode ser tratado por via endovascular. No acompanhamento de seis meses, após reintervenções, observamos perviabilidade de 80%. **Conclusão:** Apesar dos bons resultados observados nas intervenções primárias sobre as estenoses, indiscutivelmente todas as opções atuais para o tratamento da doença venosa oclusiva crônica irão levar, precoce ou tardiamente, à reestenose ou à oclusão. As oclusões venosas constituem uma incitação para o desenvolvimento de novas técnicas e novos materiais. A prevenção assume papel preponderante, com redução da implantação de cateteres centrais e da realização precoce de fístulas arteriovenosas.

**Palavras-chave:** angioplastia; estenose venosa; hipertensão venosa.

<sup>1</sup> Universidade Estadual de Londrina – UEL, Departamento de Clínica Cirúrgica, Londrina, PR, Brazil.

Financial support: None.

Conflicts of interest: No conflicts of interest declared concerning the publication of this article.

Submitted: 11.22.13. Accepted: 01.17.14.

The study was carried out at Hospital Universitário de Londrina.

## ■ INTRODUCTION

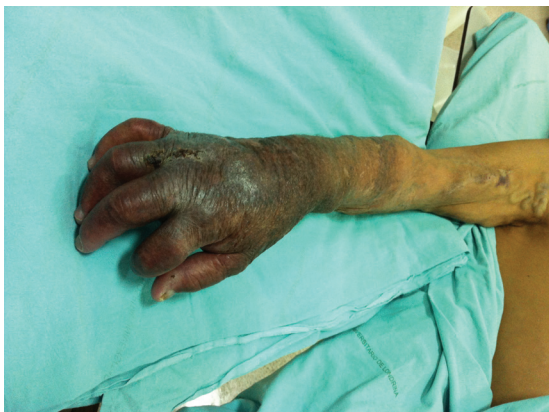Central occlusive venous disease (COVD) can be defined as the occlusion or reduction of at least 50% of the lumen of the internal jugular, subclavian, axillary, innominate or superior cava veins. In the majority of cases this disease is the result of trauma, neoplasm, central catheters or high flow arteriovenous fistulas, the last two of which are the most common causes; it is primarily triggered by development of intimal hyperplasia in up to 40% of terminal kidney disease patients.<sup>1</sup>

The disease has great clinical importance, not only because of the appearance of the debilitating signs and symptoms of chronic venous hypertension (Figure 1), but also because of the risk of losing venous access in hemodialysis patients.

Since their development, endovascular interventions have become the treatment of choice. Options include percutaneous angioplasties, with or without the use of stents. The objective of this study is to report on our experience with endovascular treatment of central occlusive venous disease, describing indications, primary and secondary success rates, complications and 6-month follow-up results.

## ■ PATIENTS AND METHODS

A total of 25 central venous angioplasties were performed between January 2010 and December 2012. Thirteen (52%) of the patients were male and the mean age of the sample was 52 years. There were twenty-four chronic hemodialysis patients who had central vein disease caused by previous catheterizations and just one patient who had angioplasty for treatment of superior vena cava syndrome caused by constriction by a tumor (breast cancer metastases).



**Figure 1.** Right upper limb with signs of severe chronic venous hypertension.

We conducted a retrospective and descriptive study based on review of patient records, test results and images of the procedures performed during this period at the university hospital run by the Universidade Estadual de Londrina, Brazil. The criteria for considering a case to be a clinical success were significant improvement in the signs and symptoms of chronic venous hypertension and in flow through the arteriovenous fistula. However, arm circumference measurements were not taken during that period. Recurrence of the symptoms was considered clinical failure, as were attempts to conduct additional angioplasty, whether successful or not.

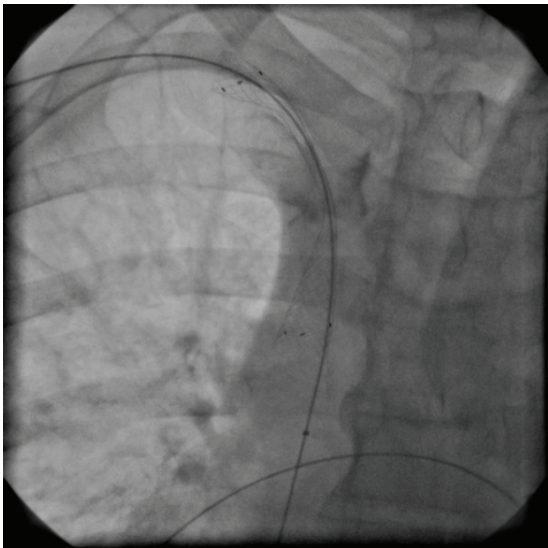
## ■ Procedure

Peripheral and central phlebographies were obtained for diagnostic assessment and treatment planning via puncture of a peripheral vein or an arteriovenous fistula in the limb with venous hypertension. After confirmation of stenosis or occlusion, a 6F sheath was fitted and a hydrophilic guidewire supported by a catheter was advanced in an attempt to cross the lesion. After anticoagulation with 5000 UI of intravenous unfractionated heparin and placement of the guidewire, in cases in which the attempt to cross the lesion was successful, a high-pressure balloon was positioned and expanded. Two control phlebographs were taken, one immediately and the other 15 minutes after angioplasty; if there was greater than 30% residual stenosis, a second angioplasty was performed, using a cutting balloon and/or self-expanding stent (Figure 2). All patients were discharged on the day of the procedure, after some hours of observation, and none were given anticoagulants or platelet antiaggregants during the postoperative period.

## ■ RESULTS

The angioplasty was a primary intervention in 21 (84%) out of 25 cases, while four (16%) procedures were to treat restenoses that had occurred after previous angioplasties. Fifteen (60%) cases were stenosis and the other ten (40%) were occlusions. The innominate vein was the most common topography, involved in 17 (68%) cases, followed by the subclavian vein, with five (20%) cases, and the superior vena cava, affected in three (12%) cases (Table 1).

With relation to the subset of primary angioplasties, 11 (52.3%) were stenoses and ten (47.7%) were occlusions. The attempt to cross the lesion was unsuccessful in all cases of occlusion and none of them could be recanalized. In these cases either



**Figure 2.** Fluoroscopy showing release of self-expanding stent and a residual lesion after balloon angioplasty.

**Table 1.** Demographic data and risk factors.

	Angioplasties
Patients	25
Age (years)	52±16
Sex: male / female	52% / 48%
Hypertension	70%
Diabetes	50%
Smoking	25%
Etiology: intimal hyperplasia	24 (96%)
Stenosis / occlusions	15 (60%) / 10 (40%)
Secondary angioplasties	4 (25%)
Use of <i>stent</i>	7 (47%)
Follow-up (months)	5±5

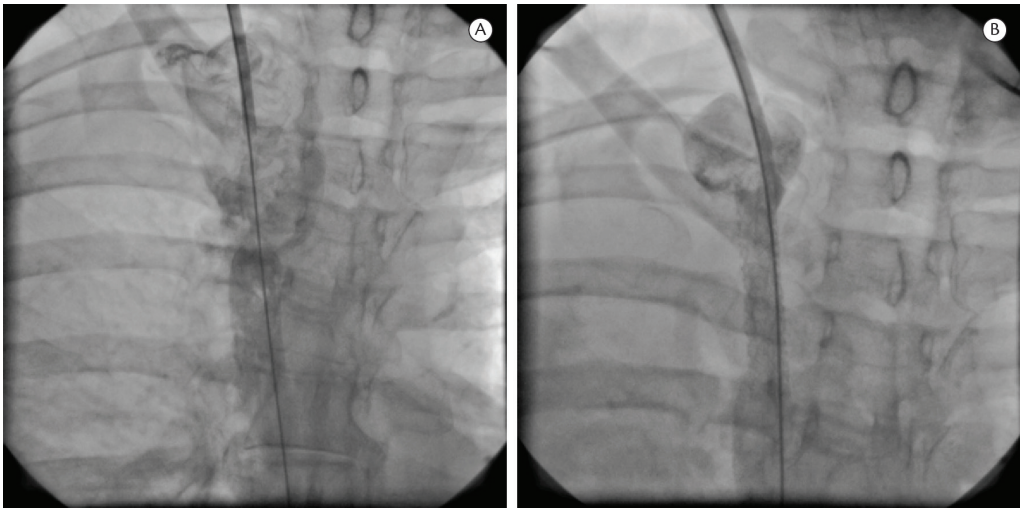
clinical observation or ligation of the fistula was chosen. In contrast, treatment proved possible in all (100%) of the stenosis cases. In five (45.4%) cases the balloon alone was sufficient to achieve good results; self-expanding stents were used in the other six (54.5%): five for residual stenosis (Figure 2) or remodeling, and, in the patient who had stenosis due to compression by a tumor, a covered stent was used because of a rupture of the innominate vein (Figure 3).

At a 30-day assessment, all 11 of the patients who had been treated were asymptomatic. Nine of these 11 patients returned for follow-up. Of these nine patients, two (22.2%) angioplasties had become obstructed by 6 months, one that had been treated using a stent and one that had not, and in neither case recanalization was possible. None of the remaining seven patent angioplasties required further intervention during the period analyzed.

With regard to the subset of four secondary angioplasties, all procedures were successful. Two were cases of restenosis after angioplasty of the innominate vein in which a stent had not been used and the other two were restenoses, one of the subclavian vein and the other of the innominate vein, after angioplasty in which a stent had been used. Only one of these four repeat angioplasties required a new *stent* and this was also the only case that occluded during follow-up, within 3 months.

**DISCUSSION**

The incidence of COVD is growing because of its frequent etiologic association with ever more common use of central venous catheters



**Figure 3.** Phlebography showing rupture of the superior vena cava: A, before correction, with leakage of contrast. B, after correction with a covered stent.

and cardiac pacemaker wires.<sup>2-4</sup> One study found that 27% of patients with COVD had a previous history of catheters or pacemaker wires,<sup>2</sup> primarily in subclavian veins, in which the occurrence of the disease can reach 50%, in contrast with the internal jugular vein, in which the occurrence rate is 10%.<sup>3</sup> This prevalence was associated with the large caliber of hemodialysis catheters and the high flow rates of dialysis sessions. The potential mechanism of COVD development caused by venous catheter placement can be explained by the trauma to endothelium caused by the catheter and the consequent inflammatory damage to the wall of the vessel, particularly when introduced via the subclavian vein, which is longer, has a tortuous course and is lodged against the first rib.<sup>3,5-8</sup> Other than catheters, another common cause of this type of injury in central veins is the turbulent venous flow of high output arteriovenous fistulas, which also cause endothelial injury followed by an inflammatory process.<sup>1,9</sup>

Central occlusive venous disease can be symptomatic or asymptomatic. Symptoms can vary depending on progression and the anatomic position of the disease.<sup>2,9</sup> Stenosis and occlusions in subclavian veins can cause venous hypertension in upper limbs, characterized by edema, cyanosis, varicose veins, hyperpigmentation and even ulcers (Figure 1). In more central sites, such as the brachiocephalic vein, they can also cause edema of face and chest and induce development of the superficial venous network in this area.<sup>9-11</sup> In patients on hemodialysis, output may be reduced and venous pressure increased, leading to inefficient dialysis. Patients who have venous compression by tumors will also present the signs and symptoms of their underlying disease, combined with those of venous hypertension just described.

Diagnostic suspicion is raised by clinical status. However, diagnostic confirmation can only be achieved through supplementary imaging exams. A venous ultrasonography study may show waves without cardiac and respiratory phasicity, which is

a finding with a high positive predictive value.<sup>9,12</sup> Venous phlebography with digital subtraction is still considered the gold standard.<sup>13</sup> However, angiotomography and magnetic resonance angiography could be alternatives to conventional angiography, although it should be stressed that patients with slower glomerular filtration rates are at risk of developing nephrogenic systemic fibrosis, caused by the gadolinium used in magnetic resonance angiography.<sup>14</sup>

Currently, the treatment of choice is endovascular, which can be conducted with or without stents. Rates of immediate technical success of angioplasties conducted with a balloon alone can vary from 70 to 90%.<sup>1,15-20</sup> In a study conducted by Kovalik et al.,<sup>16</sup> in 1994, the authors observed that there were two types of central venous injuries: non-elastic lesions, which respond well to angioplasty, and elastic lesions, which do or do not respond to angioplasty. Therefore, elastic lesions tend to maintain less patency in relation to non-elastic lesions.

The long-term patency outcomes of angioplasties for COVD using only a balloon have a wide range of variability. There are reports of primary patency at 6 months, varying from 23 to 55%.<sup>1,15-20</sup> In 2007, in one of the largest studies of angioplasties for COVD undertaken to date, Bakken et al.<sup>20</sup> studied 47 patients and demonstrated a technical success rate of 77%, with primary patency at 3 months of 58%, at 6 months of 45% and at 12 months of 29% (Table 2).

Moving on to stents, these were used for the first time by Gunther et al. in 1989, for treatment of refractory cases of COVD.<sup>21</sup> They are considered a second line of treatment. Stents provide mechanical support for the stenosis site, when it is resistant to angioplasty. Additionally, they are potentially useful for stenoses with kinks, elastic stenoses, circumscribed perforations or dissections after angioplasties; they also establish and maintain patency of chronic occlusions in central veins. However, there are significant limitations to the use of stents. After they have been implanted, stents may migrate,

**Table 2.** Primary and secondary patency of balloon angioplasty for central venous stenosis.

Study	Year	Number of participants	Primary success (%)	Patency at 3 months (%)	Patency at 6 months (%)	Patency at 12 months (%)
Glanz et al. <sup>1</sup>	1988	29	76	-	50	35
Beathard <sup>15</sup>	1992	27	89	49	29	-
Kovalik et al. <sup>16</sup>	1994	30	70	-	43	13
Quinn et al. <sup>17</sup>	1995	24	-	100	23	12
Dammers et al. <sup>18</sup>	2003	20	90	63	50	50
Surowiec et al. <sup>19</sup>	2004	35	89	-	55	43
Bakken et al. <sup>20</sup>	2007	47	77	58	45	2



shorten or fracture, and their use may impede future endovascular procedures or surgery. Furthermore, it is already evident that all stents can provoke intimal hyperplasia, leading to recurrent stenosis and multiple interventions to maintain patency.<sup>22</sup> However, in common with balloon angioplasties, stents also demonstrate a wide range of variability in relation to patency after treatment of COVD. Patency can vary from 72 to 100% at 3 months, through 55 to 100% at 6 months to 56 to 97% at 12 months.<sup>20,23-28</sup> To our knowledge, to date there have been no prospective controlled studies comparing angioplasties with and without stents for treatment of COVD. In a retrospective study published by Bakken et al. in 2007<sup>20</sup> and comparing angioplasties with and without stents, the authors showed that there were no significant differences in patency results between angioplasties with and without stents (Table 3).

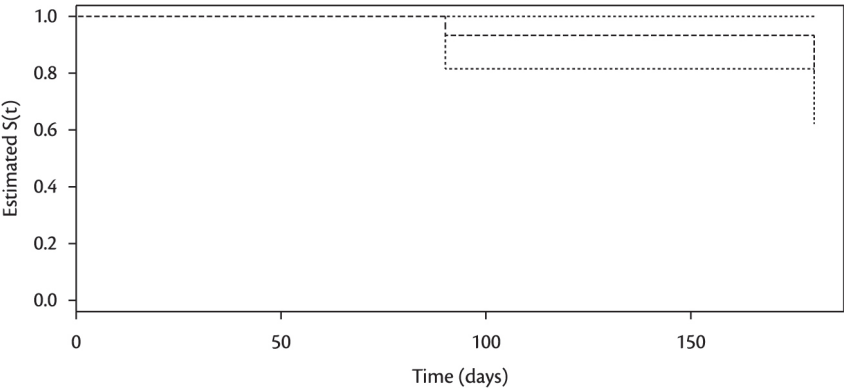
Relating our results to those of others, we note that with relation to stenosis, a primary technical success rate of 100%, followed by patency at 3 months of 93% and at 6 months of 80%, is similar to what has been reported by other authors (Figure 4).<sup>1,15-20,23-28</sup> Additionally, also in common with other authors,<sup>20,21</sup> we did not observe superior patency in angioplasties with stents. Notwithstanding, our results differ with

relation to obstructions, since we did not achieve technical success in any of these cases. In 1999, Farrell et al.<sup>29</sup> reported on five central venous obstruction recanalizations using the Rosch-Uchida needle, normally used to create intrahepatic shunts by puncture, without no major complications. Other authors have reported recanalization of obstructions using rigid guidewires.<sup>26</sup> Notwithstanding, we have not had the opportunity to attempt these techniques and occlusions remain our greatest challenge in endovascular treatment of COVD. We consider these techniques to be aggressive and subject to complications with high morbidity and mortality.

Two points should be mentioned with relation to covered stents: the first is that it is imperative that they be available in the hemodynamics room if they are to be used to treat complications during angioplasty, as with the rupture that occurred in one of our own cases. The second point is that covered stents are also being used to treat lesions that are unresponsive to angioplasty, even using stents.<sup>26,30,31</sup> The potential advantages of these materials include the provision of a relatively inert and stable intravascular matrix for endothelialization, allied to the mechanical advantages offered by stents. This could reduce the intimal hyperplasia response, reducing restenosis rates after angioplasty.<sup>27</sup> Kundu<sup>32</sup> published a study in which

**Table 3.** Primary and secondary patency of angioplasty for central venous stenosis with stents.

Study	Year	Number of participants	Primary success (%)	Patency 3 months (%)	Patency 6 months (%)	Patency 12 months (%)
Bakken et al. <sup>20</sup>	2007	26	96	72	55	46
Chen et al. <sup>23</sup>	2003	18	100	100	100	91
Vogel et al. <sup>24</sup>	2004	16	98	81	74	67
Aytekin et al. <sup>25</sup>	2004	14	100	100	89	56
Haage et al. <sup>26</sup>	1999	50	100	92	84	97
Vesely et al. <sup>27</sup>	1997	20	100	89	64	56
Gray et al. <sup>28</sup>	1995	52	96	-	76	33



**Figure 4.** Kaplan-Meier curve: patency of central venous angioplasties.

they employed eight covered stents for treatment of COVD, reporting primary patency at 3, 6 and 9 months of 100%. Notwithstanding, controlled and randomized clinical trials with longer follow-up periods are still needed.

## ■ CONCLUSIONS

Placement of central venous catheters or venous interventions are the most important risk factors for COVD. Despite the high rates of primary success obtained treating stenoses, the current options for treatment of this disease will, sooner or later, lead to restenosis or occlusion, requiring multiple interventions to maintain patency. This being the case, further controlled and randomized studies into the available treatment options are needed to develop adequate treatment algorithms. Further advances in techniques and new technologies and materials for treatment are also needed in order to achieve better results, including in venous occlusion cases, which are the greatest challenge to treat.

It is concluded that, in view of the great difficulty in achieving satisfactory results, prevention is paramount, including rational use of central venous access and appropriate planning of creation of arteriovenous fistulas in predialytic patients. As is the case with renal dysfunction, placement of central venous catheters should be avoided when possible and particularly so in the subclavian vein. Furthermore, use of other peripheral venous access routes should be minimized to preserve future venous access.

## ■ REFERENCES

- Glanz S, Gordon DH, Lipkowitz GS, Butt KMH, Hong J, Sclafani SJA. Axillary and subclavian vein stenosis: percutaneous angioplasty. *Radiology*. 1988;168:371-3. PMID:2969117.
- Agarwal AK, Patel BM, Farhan NJ. Central venous stenosis in hemodialysis patients is a common complication of ipsilateral central vein catheterization. *J Am Soc Nephrol*. 2004;15:368A-9A.
- Vanherweghem JL, Yasmine T, Goldman M, et al. Subclavian vein thrombosis: a frequent complication of subclavian cannulation for hemodialysis. *Clin Nephrol*. 1986;26:235-8. PMID:3802586.
- Trerotola SO, Kuhn-Fulton J, Johnson MS, Shah H, Ambrosius WT, Kneebone PH. Tunneled infusion catheters: increased incidence of symptomatic venous thrombosis in subclavian versus internal jugular venous access. *Radiology*. 2000;217:89-93. PMID:11012428. <http://dx.doi.org/10.1148/radiology.217.1.r00oc2789>
- Palabrica T, Lobb R, Furie BC, et al. Leukocyte accumulation promoting fibrin deposition is mediated by P-selectin on adherent platelets. *Nature*. 1992;359:848-51. PMID:1279433. <http://dx.doi.org/10.1038/359848a0>
- Weiss MF, Scivittaro V, Anderson JM. Oxidative stress and increased expression of growth factors in lesions of failed hemodialysis access. *Am J Kidney Dis*. 2001;37:970-80. [http://dx.doi.org/10.1016/S0272-6386\(05\)80013-7](http://dx.doi.org/10.1016/S0272-6386(05)80013-7)
- Fillinger MF, Reinitz ER, Schwartz RA, et al. Graft geometry and venous intimal-medial hyperplasia in arteriovenous loop grafts. *J Vasc Surg*. 1990;11:556-66. [http://dx.doi.org/10.1016/0741-5214\(90\)90302-Q](http://dx.doi.org/10.1016/0741-5214(90)90302-Q)
- Neves Junior MAV, Petnys A, Melo RC, Babbioni E. Acesso vascular para hemodiálise: o que há de novo? *J Vasc Bras*. 2013;12(3):221-5.
- Schwab SJ, Quarles LD, Middleton JP, Cohan RH, Saeed M, Dennis VW. Hemodialysis associated subclavian vein stenosis. *Kidney Int*. 1988;33:1156-9. PMID:2969991. <http://dx.doi.org/10.1038/ki.1988.124>
- Gadallah MF, El-Shahawy MA, Campese VM. Unilateral breast enlargement secondary to hemodialysis arteriovenous fistula and subclavian vein occlusion. *Nephron*. 1993;63(3):351-3. PMID:8446276. <http://dx.doi.org/10.1159/000187222>
- Wright RS, Quinones-Baldrich WJ, Anders AJ, Danovitch GM. Pleural effusion associated with ipsilateral breast and arm edema as a complication of subclavian vein catheterization and arteriovenous fistula formation for hemodialysis. *Chest*. 1994;106(3):950-2. PMID:8082387. <http://dx.doi.org/10.1378/chest.106.3.950>
- Rose SC, Kinney TB, Bundens WP, Valji K, Roberts AC. Importance of Doppler analysis of transmitted atrial waveforms prior to placement of central venous catheters. *J Vasc Interv Radiol*. 1998;9:927-4. [http://dx.doi.org/10.1016/S1051-0443\(98\)70424-5](http://dx.doi.org/10.1016/S1051-0443(98)70424-5)
- Lumsden AB, MacDonald MJ, Isiklar H, et al. Central venous stenosis in the hemodialysis patient: incidence and efficacy of endovascular treatment. *Cardiovasc Surg*. 1997;5:504-9. [http://dx.doi.org/10.1016/S0967-2109\(97\)00043-4](http://dx.doi.org/10.1016/S0967-2109(97)00043-4)
- Marckmann P, Skov L, Rossen K, et al. Nephrogenic systemic fibrosis: suspected causative role of gadodiamide used for contrast-enhanced magnetic resonance imaging. *J Am Soc Nephrol*. 2006;17:2359-62. PMID:16885403. <http://dx.doi.org/10.1681/ASN.2006060601>
- Beathard GA. Percutaneous transvenous angioplasty in the treatment of vascular access stenosis. *Kidney Int*. 1992;42:1390-7. PMID:1474770. <http://dx.doi.org/10.1038/ki.1992.431>
- Kovalik EC, Newman GE, Suhocki P, Knelson M, Schwab SJ. Correction of central venous stenoses: use of angioplasty and vascular Wallstents. *Kidney Int*. 1994;45:1177-81. PMID:8007589. <http://dx.doi.org/10.1038/ki.1994.156>
- Quinn SF, Schuman ES, Demlow TA, et al. Percutaneous transluminal angioplasty versus endovascular stent placement in the treatment of venous stenoses in patients undergoing hemodialysis: intermediate results. *J Vasc Interv Radiol*. 1995;6:851-5. [http://dx.doi.org/10.1016/S1051-0443\(95\)71200-3](http://dx.doi.org/10.1016/S1051-0443(95)71200-3)
- Dammers R, de Haan MW, Planken NR, van der Sande FM, Tordoir JH. Central vein occlusion in hemodialysis patients: Results of radiological and surgical intervention. *Eur J Vasc Endovasc Surg*. 2003;26:317-21. PMID:14509897. <http://dx.doi.org/10.1053/ejvs.2002.1943>
- Surowiec SM, Fegley AJ, Tanski WJ, et al. Endovascular management of central venous stenoses in the hemodialysis patient: results of percutaneous therapy. *Vasc Endovascular Surg*. 2004;38:349-54. PMID:15306953. <http://dx.doi.org/10.1177/153857440403800407>
- Bakken AM, Protack CD, Saad WE, Lee DE, Waldman DL, Davies MG. Long-term outcomes of primary angioplasty and primary stenting of central venous stenosis in hemodialysis patients. *J Vasc Surg*. 2007;45:776-83. PMID:17398386. <http://dx.doi.org/10.1016/j.jvs.2006.12.046>
- Gunther RW, Vorwerk D, Bohndorf K, et al. Venous stenoses in dialysis shunts: treatment with self-expanding metallic stents. *Radiology*. 1989;170:401-5. PMID:2521397.

22. Anaya-Ayala JE, Smolock CJ, Colvard BD. Efficacy of covered stent placement for central venous occlusive disease in hemodialysis patients. *J Vasc Surg.* 2011;54:754-9. PMID:21664095. <http://dx.doi.org/10.1016/j.jvs.2011.03.260>
23. Chen CY, Liang HL, Pan HB, et al. Metallic stenting for treatment of central venous obstruction in hemodialysis patients. *J Chin Med Assoc.* 2003;66:166-72. PMID:12779037.
24. Vogel PM, Parise CP. SMART stent for salvage of hemodialysis access grafts. *J Vasc Interv Radiol.* 2004;15:1051-60. PMID:15466790. <http://dx.doi.org/10.1097/01.RVI.0000129915.48500.DC>
25. Aytekin C, Boyvat F, Yağmurdu MC, Moray G, Haberal M. Endovascular stent placement in the treatment of upper extremity central venous obstruction in hemodialysis patients. *Eur J Radiol.* 2004;49:81-5. [http://dx.doi.org/10.1016/S0720-048X\(02\)00370-4](http://dx.doi.org/10.1016/S0720-048X(02)00370-4)
26. Haage P, Vorwerk D, Piroth W, Schuermann K, Guenther RW. Treatment of hemodialysis-related central venous stenosis or occlusion: results of primary wallstent placement and follow-up in 50 patients. *Radiology.* 1999;212:175-80. PMID:10405739. <http://dx.doi.org/10.1148/radiology.212.1.99j121175>
27. Vesely TM, Hovsepian DM, Pilgram TK, Coyne DW, Shenoy S. Upper extremity central venous obstruction in hemodialysis patients: treatment with Wallstents. *Radiology.* 1997;204:343-8. PMID:9240518.
28. Gray RJ, Horton KM, Dolmatch BL, et al. Use of Wallstents for hemodialysis access-related venous stenoses and occlusions untreatable with balloon angioplasty. *Radiology.* 1995;195:479-84. PMID:7724770.
29. Farrell T, Lang EV, Barnhart W. Sharp recanalization of central venous occlusions. *JVIR.* 1999;10:149-54. [http://dx.doi.org/10.1016/S1051-0443\(99\)70457-4](http://dx.doi.org/10.1016/S1051-0443(99)70457-4)
30. Quinn SF, Kim J, Sheley RC. Transluminally placed endovascular grafts for venous lesions in patients on hemodialysis. *Cardiovasc Intervent Radiol.* 2003;26:365-9.
31. Kundu S, Modabber M, You JM, Tam P, Nagai G, Ting R. Use of PTFE stent grafts for hemodialysis-related central venous occlusions: inter- mediate-term results. *Cardiovasc Intervent Radiol.* 2011;34:949-57.
32. Kundu S. Central venous disease in hemodialysis patients: prevalence, etiology and treatment. *J Vasc Access.* 2010;11:1-7. PMID:20119911.

# Correspondence

Fernando Barbosa Trevisan  
Av. São Paulo, 550/1608 - Centro  
CEP 86010-060 - Londrina (PR), Brazil  
E-mail: fernandotrvsn@hotmail.com

# Author information

JMSS é Professor Associado da Disciplina de Angiologia e Cirurgia Vascular do Departamento de Clínica Cirúrgica da Universidade Estadual de Londrina (UEL).  
FBT é Residente de Angiorradiologia e Cirurgia Endovascular do Hospital Universitário Regional do Norte do Paraná.  
WES é Professor Adjunto da Disciplina de Angiologia e Cirurgia Vascular do Departamento de Clínica Cirúrgica da Universidade Estadual de Londrina (UEL).  
DMF é Professor Adjunto da Disciplina de Angiologia e Cirurgia Vascular do Departamento de Clínica Cirúrgica da Universidade Estadual de Londrina (UEL).  
EDR é Professor Auxiliar da Disciplina de Angiologia e Cirurgia Vascular do Departamento de Clínica Cirúrgica da Universidade Estadual de Londrina (UEL).  
SVMD é Residente de Cirurgia Vascular do Hospital Universitário Regional do Norte do Paraná.  
HM é Residente de Cirurgia Vascular do Hospital Universitário Regional do Norte do Paraná.

# Author contributions

Conception and design: JMSS, FBT  
Analysis and interpretation: JMSS, FBT, WES, DMF, EDR, SVMD, HM  
Data collection: JMSS, FBT, WES, DMF, EDR, SVMD, HM  
Writing the article: JMSS, FBT, WES  
Critical revision of the article: JMSS, FBT  
Final approval of the article\*: JMSS, FBT, WES, DMF, EDR, SVMD, HM  
Statistical analysis: JMSS, FBT  
Overall responsibility: JMSS, FBT

\* All authors have read and approved of the final version of the article submitted to *J Vasc Bras.*