



Interciencia

ISSN: 0378-1844

interciencia@ivic.ve

Asociación Interciencia

Venezuela

Freitas, Francisca E. L.; Cordeiro Mori, Flora; Sasso Cerri, Estela; Lucas, Sandra R. R.; Miraglia, Sandra M.

Alterations of spermatogenesis in etoposide-treated rats: a stereological study

Interciencia, vol. 27, núm. 5, mayo, 2002, pp. 227-235

Asociación Interciencia

Caracas, Venezuela

Available in: <http://www.redalyc.org/articulo.oa?id=33906803>

- How to cite
- Complete issue
- More information about this article
- Journal's homepage in redalyc.org

redalyc.org

Scientific Information System

Network of Scientific Journals from Latin America, the Caribbean, Spain and Portugal


Non-profit academic project, developed under the open access initiative

---

# ALTERATIONS OF SPERMATOGENESIS IN ETOPOSIDE-TREATED RATS: A STEREOLOGICAL STUDY

FRANCISCA E. L. FREITAS, FLORA CORDEIRO-MORI,  
ESTELA SASSO-CERRI, SANDRA R. R. LUCAS and SANDRA M. MIRAGLIA

---

 Podophyllin is the crude extract from the roots and rhizomes of two plants from India, *Podophyllum peltatum* and *Podophyllum emodi* (Arnold, 1979; Issel and Crooke, 1979). Podophyllotoxin, a main active constituent of podophyllin, is known to produce metaphase arrest. It binds tubulin at a distinct site from that occupied by the vinca alkaloids, inhibiting microtubule formation in the mitotic spindle apparatus. However, it is too toxic for clinical use (Chen *et al.*, 1984). Thus, attempting to discover less toxic substances, two semi-synthetic glycosidic derivatives of epipodophyllotoxin were synthesized (Stähelin, 1973): the etoposide (Vepesid, code VP-16-213, abbreviated VP-16) and the teniposide (VM-26). In the 70s, these derivatives obtained approval from the FDA for clinical use. Unlike podophyllotoxin, etoposide has no effect on microtubule assembly. It does not arrest mitosis (Chen *et al.*, 1984) but, rather, exerts its maximal effects in the S or G2 cell cycle phases preventing cells from entering mitosis (Calabresi and Parks, 1985).

The etoposide (4'-Demethyl-epipodophyllotoxin-9-(4,6-O-ethylidene- $\beta$ -D-glucopyranoside) has been utilized in a wide variety of neoplasms including small-cell lung cancer, esophageic carcinoma, Kaposi's sarcoma, testicular cancer, acute leukemia and, both Hodgkin's and non Hodgkin's lymphomas (Kobayashi and Ratain, 1994).

The main target of this drug is topoisomerase II (Minocha and Long, 1984), and for this reason it is known as "poison of topoisomerase" like other drugs such as anthracyclines which have a similar mechanism of action (Joel *et al.*, 1994; Joel and Slevin, 1994). In spite of the beneficial effects of this drug in malignant tumor treatment, some reports have also emphasized a deleterious action on the organism of mammals, including the testes (Wozniak and Ross, 1983; Takahashi *et al.*, 1986a; Kadota *et al.*, 1989). The myelosuppression and gonadal failure (Myers and Schilsky, 1992) are the two most common side effects related to the use of cytotoxic anticancer agents. The implications of histological data on reproductive performance must

be considered, mainly in young adult and child patients, since there is a potential risk of loss or diminution of the reproductive capacity in etoposide-treated individuals. Such risk is commonly present when chemotherapeutic drugs are utilized in single as well as in multiple schedules (Russell and Russell, 1991). In addition, there are evidences that etoposide may be more effective and/or less toxic when administered in low divided daily doses given for prolonged periods (Greco and Hainsworth, 1994). Animal studies carried out in early 1970 demonstrated evident superiority of more extended schedules of etoposide administration against tumor cell lineage (Russell and Russell, 1991; Myers and Schilsky, 1992; Joel *et al.*, 1994). Moreover, clinical and experimental data related to the adverse late effects of the etoposide treatment on testicular morphology are scanty and fragmentary. The present investigation aims to elucidate which quantitative and qualitative changes of seminiferous epithelium can be related to testicular atrophy in adult rats (Kadota *et al.*, 1989) treated chronically from prepuberal phase with low

---

**KEY WORDS / Etoposide / Seminiferous epithelium / Spermatogenesis / Testis / Topoisomerase /**

Received: 11/19/2001. Modified: 03/14/2002. Accepted: 04/02/2002

---

Francisca E. L. Freitas. **Master in Morphology, Federal University of São Paulo (UNIFESP). Professor, Laboratory of Natural Sciences, Federal University of Acre, Rio Branco, Brazil.**

Flora Cordeiro-Mori. **Master in Morphology, Federal University of São Paulo (UNIFESP). Professor, Department of Health Sciences, Paulista University, São Paulo, Brazil.**

Estela Sasso-Cerri. **Master in Morphology. Doctor in Health Sciences, UNIFESP. Professor, Laboratory of Embryology, Department of Morphology, UNIFESP.**

Sandra R. R. Lucas. **Master in Molecular Biology and Doctor in Health Science, UNIFESP. Professor, Laboratory of Embryology, Department of Morphology, UNIFESP.**

Sandra M. Miraglia. **Master in Morphology. Doctor in Health Sciences, UNIFESP. Professor, Laboratory of Embryology, Department of Morphology, UNIFESP. Address: Rua Bartolomeu Feio, edifício Manchester, número 66, apto. 164, Brooklin, CEP 04580-000, São Paulo, S.P., Brazil. e-mail: Miraglia.morf@epm.br**

---

TABLE I  
DISTRIBUTION OF THE EXPERIMENTAL AND CONTROL GROUPS

Control groups	Initial age for injection (days)	Type of injection	Mating age (days)	Sacrifice age (days)	Period of mating (days)
C60	30	0.9% saline	-	60	-
CM113	30	0.9% saline	103	113	10
Experimental groups					
E60	30	Etoposide (VP-16)	-	60	-
EM113	30	Etoposide (VP-16)	103	113	10
V60	30	Vehicle	-	60	-
VM113	30	Vehicle	103	113	10

C60, V60 and E60 groups, n=6 in each group  
CM113, EM113 and VM113 groups, n=10 in each group.

daily doses of etoposide. A histomorphometric and stereological study was carried out, and the serum testosterone level and reproductive performance of the animals were investigated in the adult state. In addition, since this drug is also mutagenic (Maraschin *et al.*, 1990) and clastogenic (Agarwal *et al.*, 1994), the body weight, viability and mortality index of the offspring were also observed.

## Material and Methods

### Animals and groups

Forty-eight male albino Wistar 30-day old rats were distributed among six groups and were sacrificed at either 60 or 113 days of age (Table I). Two of the groups received Vepesid (VP16-213), the etoposide-experimental (E60) and the mated etoposide-experimental (EM113) groups; two other groups received the vehicle, the vehicle-experimental group (V60) and the mated vehicle-experimental group (VM113); the two remaining groups were control groups, including the sham-control group (C60) and the mated sham-control group (CM113). Animals were allocated to the treatment groups in a randomized manner and obtained from different progenies. No more than six newborn rats were maintained during the period of breast-feeding, with the aim to equalize their body weights at the start of the treatments. The mated groups (CM113, EM113 and VM113) had ten animals each, while each of the other groups included six rats.

All animals were kept in plastic cages under 12-12 hour light cycle at 23-25°C. Food and water were allowed *ad libitum*. The general physiological

state of the animals was watched during the treatment with the etoposide, although the control of the blood cells was not carried out. Principles of laboratory animal care (NIH publication 85-23, 1985) and national laws on animal use were observed. This research had approval from the Ethical Committees of the Federal University of São Paulo and the São Paulo Hospital.

### Dosage and schedule

Vepesid® ampoules (VP16-213, Bristol-Myers Squibb) were utilized. The contents of 5ml ampoules, (100mg of etoposide each) were diluted in the vehicle. The vehicle contained 650mg polyethylene glycol 300, 30mg benzyl alcohol, 1mg citric acid, 80mg Tween 80 and 241mg ethyl alcohol per ml. Dosage solutions of etoposide were prepared by dilution of each ampoule with 0.9% physiological saline according to the timetable from Bristol Myers Squibb. The rats in the vehicle-experimental groups (V60 and VM113) received the vehicle solution diluted with physiological saline; those in the sham-control groups (C60 and CM113) received only physiological saline; while rats in the experimental groups (E60 and EM113) received 2mg/kg of body weight (bw) of etoposide. The animals were subjected to each specific treatment for 30 consecutive days from the prepuberal phase, when they were 30 days old (Table I). Intraperitoneal injection was preferred over intravenous injection because of ease of administration. Lu and Meistrich (1979) have shown that both methods of administration generally yield similar results. The long-term administration of low-daily-dose etoposide was uti-

lized in this report and its use in patients has been suggested (Greco and Hainsworth, 1994).

Initially, the dosage was established according to the literature. In addition, a pilot test using different doses was previously run. The dosage was selected taking into account the testicular morphological response and the adequate mating conditions of the animals. After the end of the experiment, thirty animals of the EM113, VM113 and CM113 groups were maintained for 53 days to assess their fertility, as the duration of spermatogenesis in Wistar rats is of 52 days (Huckins, 1965).

### Histological and mating procedures

The rats were anaesthetized with sodium pentobarbital (40mg/kg bw). Their testes were dissected, removed from the scrota and weighed. A micrometer caliper was utilized to measure major and minor axes; and the gonads were then fixed by immersion in Bouin's liquid for 48h. Cross and oblique random sections were obtained from the fragments of the gonad, allowing a sequential adequate morphometric and stereological analysis (Gundersen *et al.*, 1988; Mandarim-de-Lacerda, 1999). The specimens were processed and embedded in paraffin. To obtain a better identification of all phases of spermatogenesis, 3µm-thick sections were stained with the periodic acid-Schiff method and counterstained with Harris' Hematoxylin (PAS + H).

### Morphometric and stereological studies

**Testicular weight and testis total volume.** The testis is an ellipsoid (Ahmad *et al.*, 1969). Thus, the total volume of each testis was calculated by the modified formula of ellipsoid volume:  $V = 4/3 \cdot \pi \cdot a \cdot b^2$ , where *a* is the semiprolate axis and *b* is the semioblate axis (Miraglia and Hayashi, 1993; Botelho Cabral *et al.*, 1997). The absolute and relative testicular weights were also determined (Table II).

**Volume density.** Volume densities (Vv) of both seminiferous tubules and interstitial tissue were calculated (Gundersen *et al.*, 1988). These values were obtained using a 25-point integrating eyepiece attached to a light binocular microscope (Weibel, 1963). One thousand points in 40 fields of testicular sections were randomly counted per testis at x100 magnification. Based on these data (Table III) and on the total testicular volume, the volumes of the correspondent testicular components were calculated (Miraglia and Hayashi, 1993).

TABLE II  
BODY WEIGHT AND TESTICULAR MORPHOMETRY IN ALBINO RATS OF THE CONTROL  
AND EXPERIMENTAL GROUPS

Control groups	Body weight (g)	Absolute testicular weight (g)	Relative testicular weight (g/100g bw)	Major axis (mm)	Minor axis (mm)	Total testicular volume (mm <sup>3</sup> )
C60	235.00 ± 8.03	1.25 ± 0.08	0.57 ± 0.04	18.59 ± 0.34	11.10 ± 0.38	1199.30 ± 105.56
CM113	345.72 ± 20.16	1.58 ± 0.11	0.46 ± 0.05	20.90 ± 0.33	11.96 ± 0.36	1565.33 ± 114.29
Experimental Groups						
E60	145.98 ± 6.22** E60<C60 and V60	0.78 ± 0.08** E60<C60 and V60	0.53 ± 0.03	15.51 ± 0.61** E60<C60 and V60	9.23 ± 0.29** E60<C60 and V60	691.85 ± 58.56** E60<C60 and V60
EM113	308.40 ± 8.01* E113<C113 and V113	0.76 ± 0.18** E113<C113 and V113	0.25 ± 0.06** E113<C113 and V113	15.54 ± 1.20** E113<C113 and V113	9.49 ± 0.66** E113<C113 and V113	732.79 ± 168.15** E113<C113 and V113
V60	242.00 ± 9.11	1.22 ± 0.07	0.50 ± 0.07	19.08 ± 0.41	11.20 ± 0.40	1253.18 ± 126.98
VM113	350.80 ± 18.20	1.54 ± 0.13	0.47 ± 0.04	21.00 ± 0.35	11.88 ± 0.29	1551.61 ± 143.45

Values given as mean ± standard error

\*p<0.05 (significant).

\*\* p<0.01 (highly significant).

For descriptions of the groups see Table I.

**Tubular diameter.** The diameter of seminiferous tubule sections was measured utilizing an eyepiece micrometer (x8) attached to a light binocular microscope. Random measurements of 100 tubules per animal were done in cross or oblique sections at x80 magnification. When the sections were oblique, the minor axis was measured (Miraglia and Hayashi, 1993; Botelho Cabral *et al.*, 1997).

**Cells of germinal lineage.** The percentages of tubular sections containing the various cell types (Table IV) of the seminiferous epithelium were determined by counting 100-random-transverse or oblique sections in each testis at x1000 magnification (Hayashi and Cedenho, 1980; Miraglia and Hayashi, 1993). B-type and intermediate spermatogonia were not distinguished individually and were added together. Similarly, neither A0-type and A1-A4 type spermatogonia were individually differentiated. Spermatis in the steps 1 to 8 were considered round spermatis and those in the steps 9 to 19 were denominated elongate.

#### Radioimmunoassay method

Blood was collected from the abdominal aorta of all animals, previously anaesthetized, to measure serum testosterone. The serum was maintained at -20°C. Afterwards, the animals were sacrificed with an exceeding dose of the anesthetic. Measurements were made

in a single assay by standard radioimmunoassay method (Lox *et al.*, 1974).

#### Reproductive performance

Each of the rats in the EM113, VM113 and CM113 groups were mated in individual cages with two multiparous female rats for 10 consecutive days when they were 103 days old, to assess their fertility. The fertility index in each group was considered as the ratio of the total quantity of offspring to the total number of mated female rats (Table V). The progenies were observed for 30 consecutive days in order to obtain information about their body weight, viability as well as their mortality index.

#### Statistical methods

The Jandel Statistical SigmaStat software, version 2.0, was utilized. To compare the two sets of groups of same age (E60, V60 and C60, and E113, V113 and C113) an analysis of variance (ANOVA) was performed. All data obtained from morphometric and stereological studies were submitted to a Standard One Way ANOVA, excepting the frequencies of the cellular types of germinal lineage; when the results obtained were significant or highly significant, all pairwise multiple-comparison procedures (Student-Newman-Keuls Method) were used in the variables. On the other hand, for the analysis of the frequencies of ger-

mal lineage cell types, a non-parametric ANOVA on Ranks rather than a Standard One Way ANOVA was performed. Thus, when these last data showed significance, a complementary multiple-comparison test (Dunn's method) was applied. In this case, in spite of the utilization of a non-parametric analysis, the values of means are also presented in Table III, with the purpose of giving an idea on the variability of these data and also to allow their comparison with the data obtained from the literature.

#### Results

##### General aspects of the etoposide-treated animals

The etoposide-treated albino animals exhibited piloerection and paleness in the extremities, tail and eyes, evidencing a probable anemia. Other adverse effects including myocardial infarction, hypotension, peripheral neuropathy, ascites, systemic debility and ataxy were not observed. Some hepatosplenomegaly was noted. One animal presented anaphylactic shock; it died and was substituted. In general, the rats showed transient diarrhea and some reversible alopecia, side effects that disappeared after the completion of the treatment, when the animals were in adult phase. A decrease of food intake was another adverse effect observed during the treatment; however, there was some stabilization as there was some re-

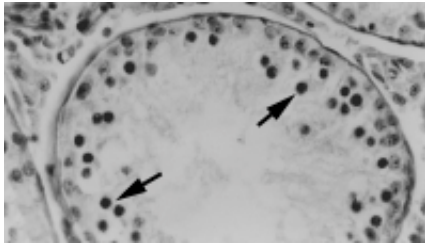


Figure 1. Light micrograph of testicular section of a 60-day-old etoposide-treated rat. An altered seminiferous tubule showing low frequency of germinal lineage cells and many cells with pyknotic nuclei (arrows). PAS + H (x245).

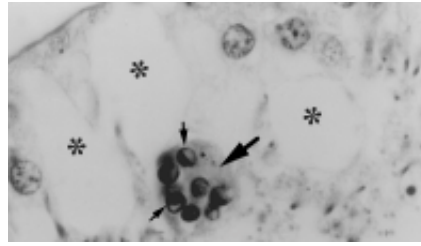


Figure 2. Light micrograph of portion of seminiferous tubule of a 60-day-old etoposide-treated rat exhibiting intraepithelial vacuolation (asterisks) and a multinucleated formation of round spermatids (large arrow). Margined condensations of chromatin are observed in some nuclei of this formation, suggesting apoptosis (small arrows). PAS + H (x615).

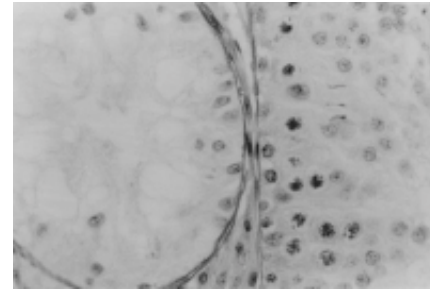


Figure 3. Light micrograph of testicular section showing portions of two seminiferous tubules of a 60-day-old etoposide-treated rat. Both tubules exhibit quantitative alterations of the germinal lineage cells. The left tubule shows "Sertolization" of the seminiferous epithelium while the right tubule exhibits a little hypotrophic epithelium. PAS + H (x240).

covery of body weight noted in 113-day-old adult rats of the mated etoposide-experimental group.

#### *Histological analysis and frequencies of the cellular types of germinal lineage*

In the etoposide-experimental group (E60), the most damaged seminiferous convoluted tubules showed low cellular population density with a corresponding enlargement of lumen diameter and intraepithelial vacuolation (Figures 1, 2, 3). Tubular sections containing only Sertoli cells ("Sertolization"; Figure 3) as well as spermatogonia were rarely observed. Although the animals in the E60 group sometimes exhibited normal tubular sections under the light microscope, py-

knotic nuclei of germinal lineage cells were observed in other sections, characterizing the degeneration of the seminiferous epithelium. Multinucleated formations of round spermatids and other rare forms of primary spermatocytes were also noted in this group (Figures 2 and 4, respectively). Sometimes, the nuclei of these formations showed chromatin condensation in one or several homogeneous masses, surrounding the nuclear membrane and suggesting apoptosis (Figure 2).

Some sections also displayed disorganized cellular associations corresponding to different stages of the seminiferous epithelium cycle while others exhibited a large quantity of cellular debris and cells at various phases of maturation localized in the tubular lumen.

The tubular diameter (Table III) was largely diminished in both etoposide-experimental groups (E60 and EM113) in comparison to the correspondent sham-control and vehicle-experimental groups.

The frequencies of the tubular sections containing the various types of germinal lineage cells are shown in Table IV. In a hundred sections examined per testis, the frequencies of all cell types of germinal lineage exhibited an accentuated reduction in the E60 group, when compared to both C60 and V60 groups.

In the mated etoposide-experimental group (EM113), various seminiferous tubule sections exhibited similar qualitative histological characteristics such

TABLE III  
TESTICULAR STEREOLOGY IN ALBINO RATS OF THE CONTROL AND EXPERIMENTAL GROUPS

Control groups	Tubular diameter (µm)	Seminiferous tubule volume (mm <sup>3</sup> )	Interstitial tissue volume (mm <sup>3</sup> )	Tubular volumetric density %	Volumetric density of interstitial tissue %
C60	258.86 ± 16.39	840.11 ± 59.25	359.19 ± 43.88	70.00	30.00
CM113	276.60 ± 17.51	1130.32 ± 92.65	435.01 ± 37.26	72.21	27.79
Experimental groups					
E60	195.59 ± 2.81** E60<C60 and V60	468.65 ± 39.04** E60<C60 and V60	223.03 ± 24.95* E60<C60 and V60	67.76** E60<C60 and V60	32.24** E60>C60 and V60
EM113	207.17 ± 21.43** E113<C113 and V113	486.28 ± 115.72** E113<C113 and V113	246.51 ± 52.89** E113<C113 and V113	66.36** E113<C113 and V113	33.64** E113>C113 and V113
V60	255.42 ± 16.83	875.72 ± 94.65	377.46 ± 60.39	69.88	30.12
VM113	275.80 ± 16.70	1123.36 ± 85.40	428.24 ± 30.54	72.40	27.60

Values given as mean ± standard error

\*p<0.05 (significant).

\*\*p<0.01 (highly significant).

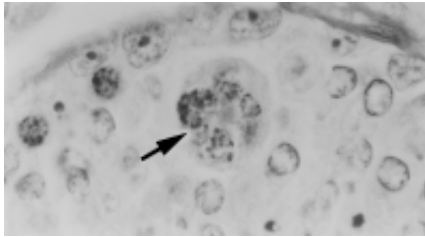


Figure 4. Light micrograph of portion of seminiferous tubules of a 60-day-old etoposide-treated rat showing a multinucleated formation of primary spermatocytes (arrow). PAS + H (x615).

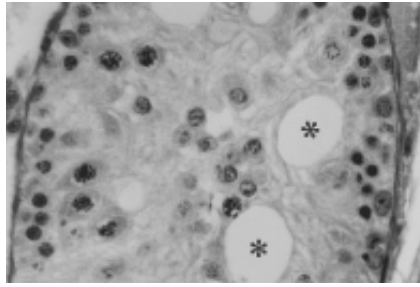


Figure 5. Light micrograph of portion of seminiferous tubule of a 113-day-old etoposide-treated rat exhibiting low frequency of germinal lineage cells, intratubular vacuolation (asterisks) as well as sloughing cells and cellular debris in the cellular lumen. PAS+H (x310).

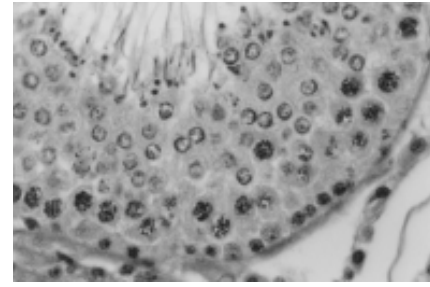


Figure 6. Light micrograph of seminiferous tubule section of a vehicle-treated rat showing normal aspect. PAS+H (x310).

as those observed in the E60 group. However, tubular sections showing low cell density, intraepithelial vacuolation (Figure 5) and “Sertolization” were less frequent in the 113-day-old than in the 60-day-old etoposide-treated experimental animals, although the frequencies of various cell types of germinal lineage were still low in relation to both CM113 and VM113 groups (Table IV). Multinucleated formations of round spermatids (Figure 2) were very rare in the EM113 group and those of spermatocytes (Figure 4) were absent.

In addition, some folding of peritubular tissue was occasionally seen

in rats of the E60 group, while it was not observed in the animals of the EM113 group. The Leydig cells showed normal morphology under light microscope in both etoposide-experimental groups.

The Sertoli cells also exhibited nuclei with normal morphology under the light microscope and the frequency of the tubules containing these cells was also normal in both E60 and EM113 (Table IV).

The animals of the V60 and VM113 groups (Figure 6) displayed normal testicular histology, like the C60 and the C113 groups, respectively.

#### Body and testicular weights

Animals in the E60 group showed a highly significant reduction of body weight in comparison to the correspondent C60 and V60 groups, while those of the EM113 group only exhibited a significant decrease in relation to the CM113 and VM113 groups (Table II). In addition, rats of both E60 and EM113 groups showed highly significant decreases of the absolute testicular weight in comparison with the sham control and vehicle-experimental groups of the same age. Consequently, 113-day-old mated etopo-

TABLE IV  
FREQUENCIES OF GERMINAL LINEAGE CELL TYPES IN ALBINO RATS OF THE EXPERIMENTAL AND CONTROL GROUPS (PERCENTAGE OF TUBULES WITH CELL TYPES)

	Spermatogonia (TOTAL)	Only A0-A4 spermatogonia (#)	A and B or interm. spermatogonia (##)	Primary spermatocytes	Secondary spermatocytes	Round spermatids	Elongate spermatids	Sertoli cells
<b>Control groups</b>								
C60	100.00	45.00	54.90	100.00	6.00	75.40	92.40	100.00
CM113	100.00	32.00	68.30	100.00	8.50	100.00	100.00	100.00
<b>Experimental groups</b>								
E60	58.00** E60<C60 and V60	23.80** E60<C60 and V60	34.20** E60<C60 and V60	54.70** E60<C60 and V60	3.00** E60<C60 and V60	40.50** E60<C60 and V60	52.10** E60<C60 and V60	100.00
EM113	66.80* E113<C113 and V113	26.20* E113<C113 and V113	40.60** E113<C113 and V113	68.80	5.50* E113<C113 and V113	55.50* E113<C113 and V113	85.80	100.00
V60	100.00	42.00	58.00	100.00	6.00	76.00	100.00	100.00
VM113	96.00	34.00	66.00	100.00	8.00	98.00	100.00	100.00

Values given as means

(#) percentage of tubules containing only type-A spermatogonia.

(##) percentage of tubules containing type-A and type-B or intermediate spermatogonia.

\*p<0.05 (significant).

\*\*p<0.01 (highly significant).

TABLE V  
SERUM TESTOSTERONE LEVEL AND REPRODUCTIVE PERFORMANCE  
IN ALBINO RATS OF THE EXPERIMENTAL AND CONTROL GROUPS

Control groups	Serum testosterone level (ng/dl)	Total number of newborn rats	Total number of mated females	Index of fertility	Weight of the offspring (g)
C60	197.00 ± 42.43	no mating	no mating	no mating	-
CM113	191.60 ± 69.82	194	20	9.70	6.22
Experimental groups					
E60	190.60 ± 101.09	no mating	no mating	no mating	-
EM113	274.40 ± 101.20	35** E113<C113 and V113	20 E113<C113 and V113	1.75** E113<C113 and V113	4.14** E113<C113 and V113
V60	253.40 ± 94.88	no mating	no mating	no mating	-
VM113	220.00 ± 74.86	203	20	10.15	6.30

Values given as mean ± standard error  
\*\*p<0.01

side-experimental rats showed a very significant reduction of relative testicular weight (g/100g bw), while 60-day-old etoposide-experimental rats did not demonstrate any statistical difference in relation to the respective sham-control group and the vehicle experimental group of the same age (Table II). The results show that the differences of the body weight that were observed between the etoposide-treated rats and their respective control rats were more accentuated the younger the animals. On the contrary, there was no significant recuperation of the testis weight in older experimental rats.

#### Morphometric and stereological analysis of other parameters

Tables II and III contain data related to the testicular morphometry and stereology, obtained from the control and experimental groups. The values related to the absolute volume of testicular components are shown in Table III and obtained from the data of each respective volume density shown in the same Table and from the total testicular volume exhibited in Table II. The majority of the morphometric and stereological parameters showed a highly significant decrease in both E60 and EM113 groups in comparison with the respective C60 and CM113 groups and the V60 and VM113 groups (Tables II, III). Exceptions were observed in relation to the volume of interstitial tissue, which only diminished significantly in the E60 group (Table III) as well as in relation to the testicular relative weight (Table II), which did not exhibit significant alterations in this

group. On the other hand, the volume density of interstitial tissue showed a highly significant increase in the E60 and EM113 groups, in comparison with the sham-control and vehicle-experimental groups of the same age. No significant morphometric and stereological testicular alterations occurred in the rats of the V60 and VM113 groups, in comparison to respective sham-control groups of the same age (C60 and CM113).

#### Serum testosterone level, reproductive performance and mortality of offspring

The statistical analysis did not show significant alterations on the serum testosterone levels in the rats of E60, V60, EM113 and VM113 experimental groups in comparison with the respective C60 and CM113 sham-control groups (Table V).

No significant alterations of the serum testosterone level were observed in the animals of etoposide-experimental groups in comparison to vehicle-experimental groups of the same age.

The data related to the reproductive performance of the rats of the EM113 group showed a highly significant decrease of the offspring occurrence obtained from the mating of these rats in comparison to CM113 and VM113 groups. Consequently, the fertility index of the etoposide-experimental group was very low (Table V).

The newborn rats exhibited small size, low body weight (Table V) and cyanosis. There was a 100% mortality of the offspring in a seven-day period.

## Discussion

Patients in reproductive age can be exposed to several side effects when chemotherapeutic agents are administered for cancer treatment. Since cells of spermatogenic lineage are especially vulnerable because they are constantly under mitosis or meiosis, damage of the testis can occur and, consequently, a decrease or loss of fertility.

The large and efficient activity of the etoposide in anticancer therapy has been reported (Relling *et al.*, 1992), including its utilization in the treatment of refractory malignant neoplasm such as tumor of testicular stroma cells (Stewart *et al.*, 1993). Etoposide acts inhibiting the topoisomerase II, an ATP-dependent nuclear-enzyme that regulates DNA topology by transiently breaking and rejoining double-stranded DNA (Wozniak and Ross, 1983). In mammals, this derivate of epipodophylloxyquin interferes with the action of the topoisomerase II during the process of DNA replication and transcription. Thus, its chemotherapeutic efficacy is correlated with its ability to stabilize the covalent DNA-topoisomerase complex and this is the most probable explanation for this cytotoxicity. However, the stabilization of the covalent complex is not sufficient to ensure cell death, but the activation by etoposide of specific enzymes and precursors of enzymes catalyzes a biochemical cascade of events culminating with apoptosis (Kaufmann, 1998). In normal tissues, the activity of etoposide varies during the cell cycle (Heck and Earnshaw, 1986) and in the S-phase this drug is very toxic (Maraschin *et al.*, 1990). The long-term administration of low-daily-dose etoposide has been discussed and suggested as a possible superior schedule in treatments of some neoplasms, provoking less myelotoxicity than the standard schedule (Greco and Hainsworth, 1994). The former schedule was utilized in this report to examine its toxicity amplitude on the process of spermatogenesis.

There is general agreement that various antineoplastic drugs exert a prejudicial effect on spermatogonia provoking the death of these cells (Meistrich *et al.*, 1982; Russell and Russell, 1991). Besides, differentiated spermatogonia are more sensitive to chemotherapeutic agents than spermatogonia, which are reserve stem cells (Lu and Meistrich, 1979). The former include types B and intermediate, as well as the renewing stem cell categories that consist of four successive generations of A-type spermatogonia (A1-A4; Lu and Meistrich,

1979; Dym and Clermont, 1987). Our results showed a significant decrease of tubular sections containing the various elements of the seminiferous epithelium in the etoposide-treated rats. This probably occurred because the testis is a highly proliferative tissue, like the bone marrow, with fast cellular renewal and, for this reason, it probably presents a large quantity of topoisomerase and becomes an easy target for the etoposide. Highly significant decrease of the frequencies of tubular sections containing the various types of spermatogonia, of primary and secondary spermatocytes, as well as of round and elongate spermatids were observed in etoposide-treated 60-day-old rat testes. On the other hand, 113-day-old etoposide-treated rats showed only significant diminution of the total number of tubular sections containing spermatogonia as well as secondary spermatocytes and round spermatids. Moreover, no statistically significant alterations of frequencies of tubular sections with primary spermatocytes and elongate spermatids occurred in these animals. The reserve stem cells (A0), which were less sensitive to the drug, proliferated and populated the tubule again with renewing stem cells (A1-A4). Thus, an increase of tubules containing these types of stem cells was noted in the etoposide-treated older rats. This may signify that a light recuperation of the seminiferous epithelium occurred since, on the contrary, in etoposide-treated younger rats the frequencies of these cellular types were highly decreased. Otherwise, morphometric and stereological testicular values pertaining to the EM113 group did not return to normal level.

Etoposide inhibits pre-mitotic DNA synthesis more effectively at stages II-III and IV-VI of the seminiferous epithelium cycle in which DNA synthesis of late spermatogonia (intermediate and B-type spermatogonia) takes place (Parvinen, 1982; Hakovirta *et al.*, 1992). The present results show that the frequencies of seminiferous tubules presenting only A-type spermatogonia as well as A-type, B-type and intermediate spermatogonia were highly reduced in the E-60 group while they were respectively reduced and highly reduced in the EM113 group.

However, other pre-mitotic peaks of DNA synthesis are also located at stages IX, XII, XIV and I, involving A1, A2, A3 and A4 spermatogonia, respectively (Hakovirta *et al.*, 1992). This fact evinces data related to the evident diminution of the frequency of the tubules containing only A-type spermatogonia verified in this report.

On the other hand, DNA synthesis in pre-meiotic spermatocytes is

not as vulnerable to the etoposide action as pre-mitotic DNA synthesis is. This might be due to the fact that the role of topoisomerase II in pre-mitotic DNA synthesis, at determined stages of development, is more accentuated than in pre-meiotic DNA synthesis. Moreover, in pre-meiotic DNA synthesis other topoisomerases can be involved in the process (Hakovirta *et al.*, 1992). Nevertheless, according to our results, etoposide administration caused a very accentuated diminution of primary spermatocytes and of other more differentiated cells of germinal lineage in etoposide-treated 60-day-old animals. Probably, the phenomenon of depletion of maturation, which involves the progressive scarceness of spermatocytes and spermatids after the destruction of spermatogonia, was also an important reason for these decreases, acting together with the direct but minor effect of etoposide on DNA pre-meiotic synthesis.

In addition to the quantitative alterations in the components of seminiferous epithelium, qualitative morphological alterations such as intraepithelial vacuolation, presence of multinucleated cells from round spermatids and primary spermatocytes, low cellularity of seminiferous tubules, germinal lineage cells with pyknotic nuclei and tubular "Sertolization" were also observed. The occurrence of multinucleated formations has been observed in testes of prepubertal normal rats (Miraglia and Hayashi, 1993), of elderly people (Holstein and Eckmann, 1986), in adverse conditions and pathological circumstances (Kaya and Harrison, 1975; Hayashi and Cedenho, 1980; Martinova *et al.*, 1989; Miraglia and Hayashi, 1993; Scott *et al.*, 1996; Botelho Cabral *et al.*, 1997; Sasso-Cerri *et al.*, 2001). However, in this work the occurrence of these formations from primary spermatocytes was much rarer than from round spermatids. During the respective phases of the normal process of spermatogenesis, intercellular bridges connect groups of each specific cell type of the germinal lineage among them. These bridges remain intact until the later spermatids are released into the tubular lumen, to be, then, the free spermatozoa. Otherwise, multinucleated formations of round spermatids are groups of these cells that were unable to separate from each other during the spermiogenesis (Miraglia and Hayashi, 1993). This happens because breakdown failures in the intercellular bridges take place (Holstein and Eckmann, 1986). Thus, these cells undergo karyokinesis without any cytokinesis and, then, coalesce themselves (Kaya and Harrison, 1975). Multinucle-

ated formations from round spermatids, suggesting apoptosis, were also relatively common in the 60-day-old etoposide-treated rats. Cancer chemotherapeutic drugs, including etoposide, are very potent inducers of apoptosis in male rat germ cells (Sjöblom *et al.*, 1998). Death of these multinucleated formations may have occurred due to apoptosis, which is a way to eliminate damaged germ cells, as it is a controlled form of cell selection acting as a molecular control point regulating physiological processes, toxicities and diseases through cell deletion (Corcoran *et al.*, 1994).

The presence of intraepithelial vacuoles was probably a consequence of the death of germinal lineage cells resulting in large spaces between contiguous Sertoli cells. Thus, these vacuoles were possibly extra-cellular in relation to the Sertoli cell, due to the lack of elements of the seminiferous epithelium. Studies by transmission electron microscope have shown that the vacuoles can also be aggregated within the seminiferous epithelium and arranged in sequential series along the course of the junctional complex between neighboring Sertoli cells (Kerr *et al.*, 1979; 1987).

The results demonstrated that the etoposide had a negative action on the seminiferous epithelium; it frequently provoked a moderated tubular hypocellularity and sometimes an accentuated tubular atrophy, observed in 113 and 60-day-old etoposide-treated rats. Consequently, morphometric and stereological testicular alterations occurred in both groups. Lower and higher daily doses of etoposide than those utilized in this experiment can induce testicular and epididymal atrophies as well as a suppression of spermatogenesis with decrease of the total number of spermatozoa produced (Takahashi *et al.*, 1986a; Kadota *et al.*, 1989).

The evident diminution of germinal lineage cells observed had repercussions on the reproductive capacity of the 113-day-old etoposide-treated rats and provoked a decrease of their fertility index. In these cases, sterility and temporary infertility are probably related to the survival of testicular reserve stem cells as well as to the number of regenerating stem cells and the kinetics of their differentiation into functional spermatozoa.

Chemotherapy can induce interstitial fibrosis and may reduce the percentage of seminiferous tubules with evident spermatogonia. However, many testicular alterations can be reversed after the treatment, depending on the elapsed time (Hensle *et al.*, 1984).

The low fertility index observed in 113-day-old etoposide-treated male rats occurred due to deficient spermatogenesis resulting in a decrease of functional spermatozoa. Damage and death of differentiated spermatogonia constituted the main cause. However, fetal mortality might also have contributed to the observed small progeny, as etoposide is a clastogenic (Maraschin *et al.*, 1990; Martin *et al.*, 1999) and mutagenic drug (Sjöblom *et al.*, 1994). It is possible that chromosome-type aberrations and frequent chromatid-type lesions occurred in cells of the spermatogenic lineage and probably neither occurred at random (Maraschin *et al.*, 1990). In the present study, the offspring from untreated multiparous normal female rats mated with etoposide-treated male rats died within 7 days after birth. High fetal mortality and many congenital malformations have been noted in the progeny from pregnant rats treated with etoposide (Takahashi *et al.*, 1986b).

It has also been reported that anticancer agents can affect Leydig cells (Barcellona and Brinkley, 1973; Parvinen, 1979) and, consequently, steroidogenesis. Stereological and ultrastructural studies about these subjects are being carried out. Daily manipulation of rats has been cited as another factor that might modify the serum testosterone level (Grotta, 1971). No statistically significant alterations of serum testosterone level were noted in the 60-day-old and 113-day-old rats treated with etoposide or vehicle for 30 consecutive days from 30 days of age.

In summary, the long-term administration of low daily doses of etoposide to rats from prepuberal phase induced accentuated testicular morphometric and stereological alterations in the adult phase. These morphological alterations were not specific and were similar to those caused by other anticancer agents. Probably, differentiated spermatogonia (B-type, intermediate, A1-A4 types) were the most affected cells because they have high quantities of topoisomerase II, the main target of etoposide action. Previous reports have demonstrated that the formation of a cleavable etoposide-topoisomerase II-DNA complex triggers cytotoxicity but does not constitute the immediate cause of cellular death; on the other hand, there is a high degree of correlation between etoposide-induced sister chromatid exchanges and cytotoxicity (Chatterjee *et al.*, 1990). Sister chromatid exchanges may also include non-homologous recombination in which unequal exchange of genetic material could lead to loss or gain of genetic sequences from progeny cells. This fact could lead to essential

gene inactivation, subsequent depletion of essential gene product and, finally, cellular death (Berger *et al.*, 1991). The frequencies of other more differentiated cells of germinal lineage also diminished, which might have been due to the cascade cellular depletion phenomenon since they derive from progressive differentiation of spermatogonia, but the direct action of etoposide on those cells should not be excluded. The rats showed restoration of body weight, and some light recuperation of the seminiferous epithelium could be observed. Otherwise, their reproductive performance was very low. Thus, although a reduced fertility index has been noted when mating etoposide-treated rats with normal multiparous females, it is also important to consider the high number of early deaths of cyanotic and little pups that occurred soon after birth. Also, it is possible that a percentage of pre- or post-implantation embryonic loss could have happened since etoposide is a clastogenic and mutagenic drug, deserving further investigation.

#### ACKNOWLEDGMENTS

This work was supported by FAPESP. The authors thank José Gilberto Vieira, Ieda Varreschi and Ivonne F. Bianco of the Endocrinology Laboratory of UNIFESP for the testosterone radioimmunoassay, Arilda M. Jardim for secretarial assistance and Isabel C.M. Westin for text revision.

#### REFERENCES

- Agarwal K, Mukherjee A, Sen S (1994) Etoposide (VP-16): cytogenetic studies in mice. *Environ. Mol. Mutag.* 23: 190-193.
- Ahmad KN, Lennox B, Mack WS (1969) Estimation of the volume of Leydig cells in man. *Lancet* 30: 461-464.
- Arnold AM (1979) Podophyllotoxin derivative VP 16-213. *Cancer Chemother Pharmacol.* 3: 71-80.
- Barcellona WJ, Brinkley BR (1973) Effects of actinomycin D on spermatogenesis in the Chinese hamster. *Biol. Reprod.* 8: 335-349.
- Berger NA, Chatterjee S, Schmotzer JA, Helms SA (1991) Etoposide (VP-16-213)-induced gene alterations: potential contribution to cell death. *Proc Natl Acad Sci.* 88: 8740-8743.
- Botelho Cabral MG, Hayashi H, Miraglia SM (1997) Histomorphometry of sexually immature albino rat testis after X ray-irradiation. *Interciencia* 22: 71-80.
- Calabresi P, Parks Jr RE (1985) Quimioterapia das doenças neoplásicas. In Gilman AG, Goodman LS, Rall TW, Murad F. *As bases farmacológicas da terapêutica*. 7ed. Guanabara-Koogan. Rio de Janeiro. pp. 813-856.
- Chatterjee S, Trivedi D, Petzold SJ, Berger NA (1990) Mechanism of epipodophyllotoxin-induced cell death in poly (adenosine diphosphate-ribose) synthesis-deficient V79 Chinese hamster cell lines. *Cancer Res.* 50: 2713-2718.
- Chen GL, Yang L, Rowe TC, Halligan BD, Tewey KM, Liu LF (1984) Nonintercalative antitumor drugs interfere with the breakage reunion reaction of mammalian DNA topoisomerase II. *J Biol Chem* 259: 13560-13566.
- Corcoran GB, Fix L, Jones DP, Moslen MT, Nicolera P, Oberhammer FA, Buttyar R (1994) Contemporary issues in toxicology. Apoptosis: molecular control point in toxicity. *Toxicol. Appl. Pharmacol.* 128: 169-181.
- Dym M, Clermont Y (1987) Effects of x-rays on type A spermatogonia in the rat. *Anat. Rec.* 157: 238.
- Greco AF, Hainsworth JD (1994) Prolonged administration of low-daily-dose etoposide: a superior dosing schedule? *Cancer Chemother. Pharmacol.* 34 (Suppl.): 101-104.
- Grotta LJ (1971) Effects of age and experience on plasma testosterone. *Neuroendocrinology* 8: 136-143.
- Gundersen HJG, Bendtse TF, Korbo L (1988) Some new, simple and efficient stereological methods and their use in pathological research and diagnosis. *APMIS* 96: 379-394.
- Hakovirta H, Parvinen M, Lähdetie J (1992) Effects of etoposide on stage specific DNA synthesis during rat spermatogenesis. *Mutat. Res.* 301: 189-193.
- Hayashi H, Cedenho AP (1980) Fertilizing capacity of the cryptorchid rat. *J. Reprod. Fert.* 59: 79-82.
- Heck MMS, Earnshaw WC (1986) Topoisomerase II: a specific marker for cell proliferation. *J. Cell Biol.* 103: 2569-2581.
- Hensle TW, Burbidge KA, Shepard BR, Marbec CC, Blanc WA, Wigger JH (1984) Chemotherapy and its effect on testicular morphology in children. *J. Urol.* 131: 1142-1144.
- Holstein AF, Eckmann C (1986) Multinucleated spermatocytes and spermatids in human seminiferous tubules. *Andrology* 18: 5-16.
- Huckins C (1965) Duration of spermatogenesis in pre and post puberal Wistar rats. *Anat. Rec.* 151: 364.
- Issel BF, Crooke ST (1979) Etoposide (VP-16-213). *Cancer Treat. Rev.* 6: 107-124.
- Joel SP, Slevin ML (1994) Schedule-dependent topoisomerase II-inhibiting drugs. *Cancer Chemother. Pharmacol.* 34: S84-S88.
- Joel SP, Shah R, Slevin ML (1994) Etoposide dosage and pharmacodynamics. *Cancer Chemother. Pharmacol.* 34: 69-75.
- Kadota T, Chikazawa H, Takahashi N (1989) Toxicological study of etoposide (VP-16) in rats with special emphasis on testicular alteration. *Toxicol. Lett.* 45: 185-194.
- Kaufmann SH (1998) Cell death induced by topoisomerase-targeted drugs: more questions than answers. *Biochim. Biophys. Acta.* 1400: 195-211.
- Kaya M, Harrison RG (1975) An analysis of the effect of ischaemia on testicular ultrastructure. *J. Pathol.* 117: 105-117.
- Kerr JB, Rich KA, Kretser DM (1979) Effects of experimental cryptorchidism on the ultrastructure and function of the Sertoli cell and peritubular tissue of the rat testis. *Biol. Reprod.* 21: 823-838.
- Kerr JB, Bartlett JMS, Donachie K, Sharpe RM (1987) Origin of regenerating Leydig cells in the testis of the adult rat: an ultrastructural,

- morphometric and hormonal assay study. *Cell Tissue Res.* 249: 367-377.
- Kobayashi K, Ratain MJ (1994) Pharmacodynamics and long-term toxicity of etoposide. *Cancer Chemother. Pharmacol.* 34(Suppl.): 64-68.
- Lox CD, Christian CD, Heine MW (1974) A simple radioimmunoassay for testosterone. *Am. J. Obst. Gynecol.* 118: 114-118.
- Lu CC, Meistrich ML (1979) Cytotoxic effects of chemotherapeutic drugs on mouse testis cells. *Cancer Res.* 39: 3575-3582.
- Mandarin-de-Lacerda CA (1999) What is the interest of normal and pathological morphological research to be quantitative? The example of the stereology. *Braz. J. Morphol. Sci.* 16: 131-139.
- Maraschin J, Dutrillaux B, Aurias A (1990) Chromosome aberrations induced by etoposide (VP-16) are not random. *Int. J. Cancer* 46: 808-812.
- Martin RH, Ernst S, Rademaker A, Barclay L, Ko E, Summers N (1999) Analysis of sperm chromosome complements before, during, and after chemotherapy. *Cancer Genet. Cytogenet.* 108: 133-136.
- Martinova YS, Nikolova DB, Michova Z (1989) Early effect of the anticancer drug biocarbazine (DTIC synonym) on mice spermatogenesis. *Z. Mikrosk. Anat. Forsch.* 103: 431-436.
- Meistrich ML, Finch M, da Cunha M, Hacker U, Au WW (1982) Damaging effects of fourteen chemotherapeutic drugs on mouse testis cells. *Cancer Res.* 42: 122-131.
- Minocha A, Long BH (1984) Inhibition of DNA catenation activity of type II topoisomerase by VP16-213 and VM26. *Biochem. Biophys. Res. Comm.* 122: 165-170.
- Miraglia SM, Hayashi H (1993) Histomorphometry of immature rat testis after heating. *J. Morphol.* 217: 65-74.
- Myers SE, Schilsky RL (1992) Prospects for fertility after cancer chemotherapy. *Sem. Oncol.* 19: 597-604.
- Parvinen LM (1979) Early effects of procarbazine (N-Isopropyl-L-(2 Methylhydrazino)-p-Toluamide Hydrochloride) on rat spermatogenesis. *Exper. Mol. Pathol.* 30: 1-11.
- Parvinen LM (1982) Regulation of the seminiferous epithelium. *Endocr. Rev.* 4: 404-417.
- Relling MV, Evans R, Dass C, Desiderio DM, Nemej J (1992) Human cytochrome P450 metabolism of teniposide and etoposide. *J. Pharmacol. Exp. Ther.* 261: 491-496.
- Russell LD, Russell JA (1991) Short-term morphological response of the rat testis to administration of five chemotherapeutic agents. *Am. J. Anat.* 192: 142-168.
- Sasso-Cerri E, Giovanoni M, Hayashi H, Miraglia SM (2001) Morphological alterations and intratubular lipid inclusions as indicative of spermatogenic damage in cimetidine-treated rats. *Arch. Androl.* 46: 5-13.
- Scott CA, Desinan L, Maffezzini M, Simonato A, Avelini C, Stefani S, Rizze V, Carmignani G, Beltrami CA (1996) Effects of cisplatin and luteinizing hormone releasing hormone analogues on rat spermatogenesis. A morphological and flow cytometric study. *Anat. Quant. Cytol. Histol.* 18: 361-373.
- Sjöblom T, Parvinen M, Lähdetie J (1994) Germ-cell mutagenicity of etoposide: induction of meiotic micronuclei in cultured rat seminiferous tubules. *Mutat. Res.* 323: 41-45.
- Sjöblom T, West A, Lähdetie J (1998) Apoptotic response of spermatogenic cells to the germ cell mutagens etoposide, adriamycin, and diepoxybutane. *Environ. Mol. Mutagen.* 31: 133-148.
- Stähelin H (1973) Activity of a new glycosidic lignun derivative (V.P. 16-213) related to podophyllotoxin in experimental tumours. *Eur. J. Cancer* 9: 215.
- Stewart AD, Stewart JD, Mai KT (1993) Active chemotherapy for metastatic stromal cell tumor of the testis. *Urology* 42: 732-734.
- Takahashi N, Kadota T, Kawano S (1986a) Toxicity studies of VP-16-213 (V). Intravenous three-month toxicity in rats. *J. Toxicol. Sci.* 11(Suppl.1): 123-161.
- Takahashi N, Kai S, Kohmura H (1986b) Reproduction studies of VP-16-213 (V). Intravenous administration to rats prior to and in the early stages of pregnancy. *J. Toxicol. Sci.*;11 (Suppl. 1): 263-279.
- Weibel ER (1963) Principles and methods for the morphometric study of the lung and the other organs. *Lab. Invest.* 12: 131-155.
- Wozniak AJ, Ross WE (1983) DNA damage as a basis for 4'-demethylepipodophyllotoxin-9-(4,6-O-ethylidene-b-D-glucopyranoside) (Etoposide) cytotoxicity. *Cancer Res.* 43: 120-124.