



Psicothema

ISSN: 0214-9915

psicothema@cop.es

Universidad de Oviedo

España

Fernández Lucas, Alberto; Martínez Castillo, Eduardo; López Ibor Alcocer, María Inés; Ortiz Alonso, Tomás

Bilateral activation of motor cortex after functional recovery in capsular ictus: a case report

Psicothema, vol. 11, núm. 3, 1999, pp. 545-550

Universidad de Oviedo

Oviedo, España

Available in: <http://www.redalyc.org/articulo.oa?id=72711307>

- How to cite
- Complete issue
- More information about this article
- Journal's homepage in redalyc.org

redalyc.org

Scientific Information System

Network of Scientific Journals from Latin America, the Caribbean, Spain and Portugal

Non-profit academic project, developed under the open access initiative

BILATERAL ACTIVATION OF MOTOR CORTEX AFTER FUNCTIONAL RECOVERY IN CAPSULAR ICTUS: A CASE REPORT

Alberto Fernández Lucas, Eduardo Martínez Castillo,
María Inés López-Ibor Alcocer y Tomás Ortiz Alonso

Universidad Complutense de Madrid

Abnormally-associated movements are one of the most commonly observable signs after capsular infarction. Various studies have related these associated movements to a bilateral activation of motor cortices. This activation has been previously detected by means of Movement-related potentials in several pathologies. Our results show NS' and MP components bilaterally distributed over the scalp. Thus, this technique could be useful in order to elucidate patterns of functional reorganization after capsular stroke.

Activación bilateral de la corteza motora después de un ictus capsular: un caso clínico. Uno de los signos comúnmente observados tras un infarto capsular es la presencia de movimientos asociados anormales. Varios estudios han puesto en relación estos movimientos asociados con una activación anómala bilateral de la corteza motora. Este patrón de activación ha sido detectado mediante potenciales motores en varias patologías. Nuestros resultados muestran alteraciones de diversos componentes (NS y MP) por lo que entendemos que esta técnica puede ser de utilidad para clarificar los mecanismos de reorganización funcional tras un infarto capsular.

One of the more frequent alterations of the pyramidal system is the capsular stroke. Vascular accidents of the internal capsule produce, because of the interruption of the corticospinal and corticobulbar fascicles, a paralysis in the contralateral superior and inferior limb and in the inferior contralateral facial muscles. The progress of the capsular stroke is normally positive, though the initial absence of movement in the contralateral limbs, but there is an increased difficulty in the recuperation of the more distal parts of both limbs (Arboix et al., 1990; Elcano et

al., 1989). It is also common the persistent difficulty in the performance of precise movements, as well as the presence of associated movements (Young & Young, 1998).

Recent Positron Emission Tomography (PET) studies (Chollet et al., 1991; Weiller et al., 1992; Weiller et al., 1993) has revealed bilateral activation of motor cortices after functional recovery, during recovered-fingers movement. This bilateral activation is related to associated-involuntary movements (Weiller et al., 1993) of normal fingers.

Cortical potentials related to voluntary movement may help to elucidate the neural mechanisms participating in associated-movement preparation. These cortical potentials are generally defined as movement-related potentials (MRPs) and reflect a prepa-

Correspondencia: Tomás Ortiz Alonso
Departamento de Psiquiatría y Psicología Médica
Facultad de Medicina
Universidad Complutense
28035 Madrid (Spain)

ratory activity that is related to the specific movement being executed (Shibasaki & Ikeda, 1996). MRPs associated with hand or finger movements begin with a long phase of rising negativity (Hallet, 1994). The later part of this rising negativity, starting about 400 msec before the onset of movement, is called the negative slope (NS'). NS' becomes steeper especially at the centroparietal region contralateral to the movement side and peaks about 90 msec before the onset of EMG activity. Sometimes the NS' is followed by the motor potential (MP), which begins before movement, peaks after movement beginning, and produces the main negativity. The initial slope of the MP (isMP) occurs after the peak of NS' and before the onset of EMG activity. This initial slope has a discrete and focal topography and appears over the contralateral primary motor cortex representing its activation (for a review see Barret et al., 1985; Barret et al., 1986).

To our interest, erroneous bilateral cortical predominance observed in mirror movements (similar to that described after motor recovery in capsular infarction) is well represented by MRPs recording, indicating an abnormal bilateral NS' (Shibasaki & Nagae, 1984) and MP (Cohen et al., 1991).

Therefore, we expect that MRPs (NS'-MP) will reflect a bilateral activation of motor cortices during self-paced, recovered-hand movements, in a patient with capsular stroke.

Patient and Methods

Patient Characteristics

64 years old female (patient M.P) with a history of hypertensive illness, is admitted to San Carlos University Hospital, with an acute episode, that consist in a speech disorder associated to a motor deficit in the right hemibody without lost of consciousness. Neurological examination reveals a mode-

rate disarthria, right central facial paresis and a predominantly crural right hemiparesis. There are no sensory alterations. The rest of the physical and neurological examinations were within normal limits. Diagnose was a pure motor hemiparesis.

The MRI (T2 images), two weeks after the acute episode, reveals few high intensity images in the posterior area of the left internal capsule (see Figure 1).

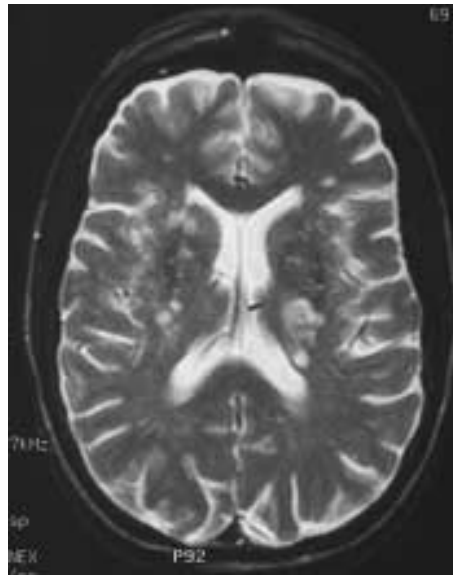


Figure 1. Magnetic Resonance imaging (MRI, T2 images), reveals few high intensity images in the posterior area of the left internal capsule.

After the acute episode, the patient attended to a rehabilitation program with a completed recuperation after three months.

Method

11 months after the acute episode, patient M.P was asked to make self-paced, brisk abduction movements of the right (recovered) and left (normal) hands at an irregular rate of approximately one movement every 4 seconds, while her eyes fixated at a point 1.7 m

away. M.P completed 150 to 180 movements, divided into blocks of 30 to 50 movements for each hand in a single recording session.

Cerebral evoked potentials were recorded from C3, Cz, C4 Ag/AgCl electrodes on the scalp according to the international 10/20 system. Eyes movements were monitored by an electrode, placed infraorbitally, referenced to linked ear electrodes A1/A2. An unrectified EMG was recorded from an electrode placed over the belly of the common extensor digitorum muscle of each hand, referenced to an inactive electrode placed on the dorsum of the ipsilateral hand. The band-pass was 0.3-70 Hz and the impedances <5 k Ohms for all electrodes. EEG recordings were performed in a quiet, dimly lighted room. M.P was resting comfortably in an arm-chair with her hands extended naturally in a pronated position on a pillow. She was requested to assume a relaxed posture in order to minimised head and eye movements.

We analysed the latency of the movement related cortical potentials over C3, C4 and Cz electrodes, measuring the Negative Shift Peak and Motor potential peak and reaction time measuring EMG onset of voluntary hand movement. The latencies of the movement-related potentials were measured manually using the computer, following the criteria previously defined by Tarkka and Hallet (1991).

Data were analysed off-line by means of a polygraph interface (ATI Nautilus 5.28). To this effect, cerebral, EMG, and EOG channels were aligned by the onset of the initial negative deflection of the compound muscle action potential. An interval of 1,500 milliseconds, 1000 backwards and 500 forwards from EMG onset, was then analysed. Trials containing substantial artefacts or contaminated by eye movements were excluded from subsequent analysis.

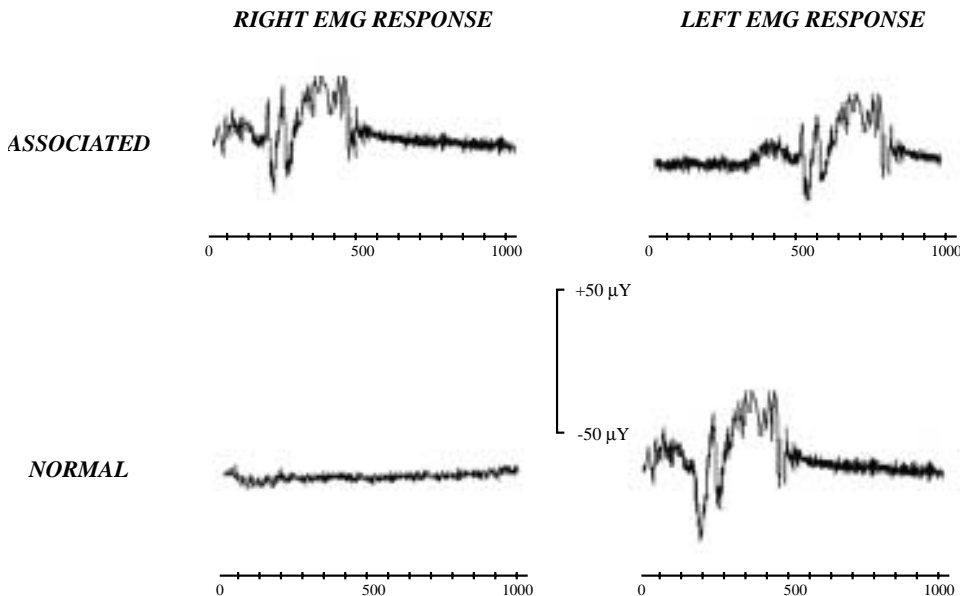


Figure 2. Top: abnormal associated EMG response in left hand, recorded during right hand voluntary movement. Bottom: Normal EMG response during left hand movement. Time 0: onset of EMG activity; this is trigger point for forward and backward averaging.

Results

EMG

The main result observed in the EMG register is the continuous presence of as-

sociated movements in the left hand during the performance of the self-paced right hand (recovered hand) movements (Figure 2). However, left hand movements were not associated to any abnormal movement.

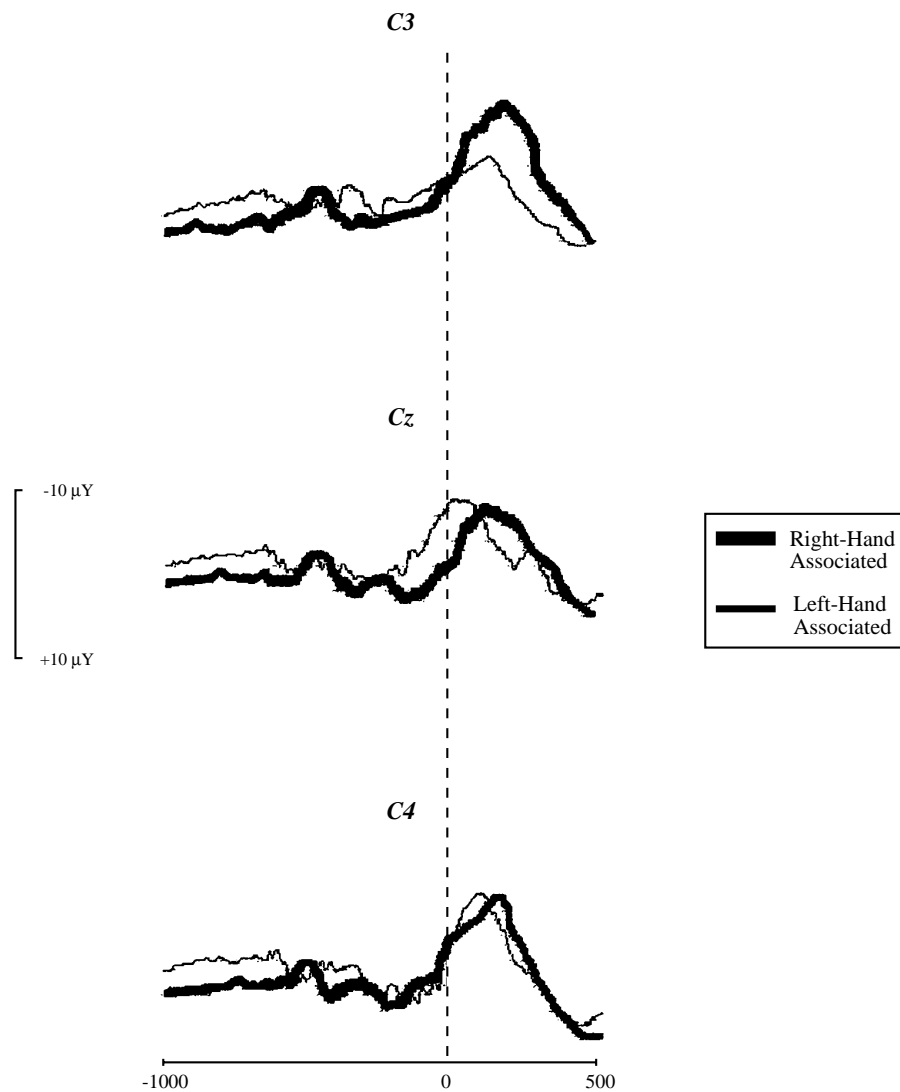


Figure 3. MRPs elicited by right (associated) or left hand movements. Time 0: onset of EMG activity, this is the trigger point for forward and backward averaging.

The onset of the EMG in the right hand appears at 209 msec and at 187,3 msec in the left hand. The associated movement that appears in the left hand when a movement in the right hand appears at 692 msec.

MRPs

Figure 3 show MRPs recorded from scalp electrodes C3, Cz and C4. Approximately 400 msec before EMG onset the waveforms became steeper (NS') and reach a peak about 50 msec before EMG onset, with larger amplitude over contralateral electrodes for left hand normal movement.

In opposite to left hand movement, MP has a clear bilateral distribution during right movements. This component begins close to EMG onset and peaks about 170 msec after. MRPs associated to left hand movement present a clearly diminished amplitude over C3 electrode; while both right and left hand movements, elicitates a MP component of maximum amplitude over C4. Moreover, right hand movement elicitates an abnormal high-amplitude MS component over C4, with a significative delay (40 msec) compared to left hand MS. This left-to-right MS delay is also observable over Cz.

Discussion

Results above presented confirm two previously well defined evidences: 1. Neural reorganization necessary to overcome some motor deficits, may consequently cause a bilateral activation of motor cortices during recovered-limb movements; and 2. This bilateral cortical activation may produce, as a consequence, associated movements in «normal» limb.

The bilaterality of the NS' y MP components is a normal observation in the mirror movements (Shibasaki & Nagae, 1984). This pathology is characterised, like in other patients with a capsular infarction, by the presence of involuntary associated abnor-

mal movements (Schott & Wyke, 1981). But this is not the only similarity in both diseases. When we considered Weiller y Chollet results (Chollet et al., 1991; Weiller et al., 1992; Weiller et al., 1993), the onset of bilateral activity (that includes premotor areas and caudate nuclei) and associated movements, is a consequence of a desinhibition process. This implies that there is a functional inhibition in these areas under normal conditions, which is determined under by contralateral structures (Weiller et al., 1992), mainly between homotopic regions. For these authors, the decreased of the natural process of transhemispheric inhibition (mostly transcallosal) could be a valid explanation.

This hypothesis is narrowly related to Danek's and the mirror movements. As Danek et al. (Danek et al., 1992) pointed out, a bilateral distribution of descending motor pathways can not sufficiently explain mirror movements, as far as some neurones in the unlesioned primary motor cortex address hand muscles bilaterally, both in monkeys (Tarkka et al., 1990) and humans (Fries et al., 1991). Accepting this latent bilaterality of motor commands as normal, some authors (Cohen et al., 1991; Danek et al., 1992) postulated an «inhibition theory» of mirror movements. This theory claims that commands from the motor cortex that would excite ipsilateral muscles via ipsilateral pathways normally are suppressed by the opposite, not primarily active, motor cortex (Shibasaki & Kato, 1975). Such inhibition, is thought to be exerted by cortico-cortical fibers crossing the corpus callosum. When this callosal fiber system fails, as occurs in the agenesis of corpus callosum, mirror or associated movements currently appear.

Recently, Ortiz et al (In press), have been able to probe that certain associated movements that appears in Alzheimer's disease (similar to the alterations that appears in the capsular infarctions) are narrowly rela-

ted with a significant decreased in the volume of anterior areas of the corpus callosum. We can conclude, therefore, that there is a constellation of motor disturbances (mirror movements, associated movements in striato-capsular infarction and Alzheimer's disease) that are characterised by an

abnormal bilateration of the neural activity, that could be explained because of the disappearance of the natural process of the active inhibition, that is originated either because a callosal alteration or because of an abnormal reorganization of the pyramidal system.

References

- Arboix A, Martí-Vilalta JL, García JH. (1990). Clinical study of 227 patients with lacunar infarcts. *Stroke*, 21, 842-847.
- Barret G, Shibasaki H, Neshige R. (1985). A computer-assisted method for averaging movement-related cortical potentials with respect to EMG onset. *Electroencephalography and Clinical Neurophysiology* 60: 276-281.
- Barret G, Shibasaki H, Neshige R. (1986). Cortical potential shifts preceding voluntary movement are normal in parkinsonism. *Electroencephalography and Clinical Neurophysiology*, 63, 340-349.
- Chollet F, DiPiero V, Wise RJS, Brooks DJ, Dolan RJ, Frackowiak RSJ. (1991). The functional anatomy of motor recovery after stroke in humans: a study with Positron Emission Tomography. *Annals of Neurology*, 29, 63-71.
- Cohen LG, Meer J, Tarkka I, Bierner S, Liederma DB, Dubinsky RM. (1991). Congenital mirror movements: abnormal organisation of motor pathways in two patients. *Brain*, 114, 381-403.
- Danek A, Heye b, Schroeder R. (1992). Cortical evoked motor responses in patients with Xp22.3-linked Kallmann's syndrome and in female gene carriers. *Annals of Neurology*, 31, 299-304.
- Elcano J, Arboix A, Kulisevsky J, Martí-Vilalta JL. (1989). Hemiparesic ataxic syndrome after a capsular haemorrhage. *Medicina Clínica (Barcelona)*, 92, 479.
- Fries W, Danek A, Witt TN. (1991). Motor responses after transcranial electrical stimulation of cerebral hemispheres with a degenerated pyramidal tract. *Annals of Neurology*, 29, 646-650.
- Hallet M. (1994). Movement-related cortical potentials. *Electromyography and Clinical Neurophysiology*, 34, 5-13.
- Ortiz T, Fernández A, Martínez E, López-Ibor MI, López-Ibor JJ. (1998). Patterns of callosal atrophy and presence of associated electromyographic responses in early stages of Alzheimer's disease. *Annals of Neurology* (In Press).
- Schott GD, Wyke MA. (1981). Congenital mirror movements. *Journal of Neurology Neurosurgery and Psychiatry*. 44, 586-599.
- Shibasaki H, Ikeda A. (1996). Generation of movement-related potentials in the supplementary sensorimotor area. *Advances in Neurology*, 70, 117-125.
- Shibasaki H, Kato M. (1975). Movement-associated cortical potentials with unilateral and bilateral simultaneous hand movement. *Journal of Neurology*, 208, 191-199.
- Shibasaki H, Nagae K. (1984). Mirror movement: application of movement-related cortical potentials. *Annals of Neurology* 15, 299-302.
- Tarkka IM, Hallet M. (1991). Topography of scalp-recorded motor potentials in human finger movements. *Journal of Clinical Neurophysiology*, 8, 331-341.
- Tarkka IM, Reilly JA, Hallet M. (1990). Topography of movement-related cortical potentials is abnormal in Parkinson's disease. *Brain Research*, 522, 172-175.
- Weiller C, Chollet F, Friston KJ, Wise RJS, Frackowiak RSJ. (1992). Functional reorganization of the brain in recovery from striatocapsular infarction in man. *Annals of Neurology*, 31, 463-472.
- Weiller C, Ramsay SC, Wise RJS, Friston KJ, Frackowiak RSJ. (1993). Individual patterns of functional reorganization in the human cerebral cortex after capsular infarction. *Annals of Neurology*, 33, 181-189.
- Young PA, Young PH. (1998). *Neuroanatomía Clínica Funcional*. Barcelona. Ed. Masson.

Aceptado el 23 de diciembre de 1998