



Acta Medica Colombiana

ISSN: 0120-2448

Asociacion Colombiana de Medicina Interna

García-Marmolejo, Juan Pablo; Mayoral-Valencia, Manuel David  
Pulmonary alveolar microlithiasis. An incidental finding in a patient with COPD  
Acta Medica Colombiana, vol. 46, no. 2, 2021, p. 51  
Asociacion Colombiana de Medicina Interna

DOI: <https://doi.org/10.36104/amc.2021.1990>

Available in: <https://www.redalyc.org/articulo.oa?id=163169706011>

- ▶ How to cite
- ▶ Complete issue
- ▶ More information about this article
- ▶ Journal's webpage in redalyc.org



Scientific Information System Redalyc

Network of Scientific Journals from Latin America and the Caribbean, Spain and Portugal

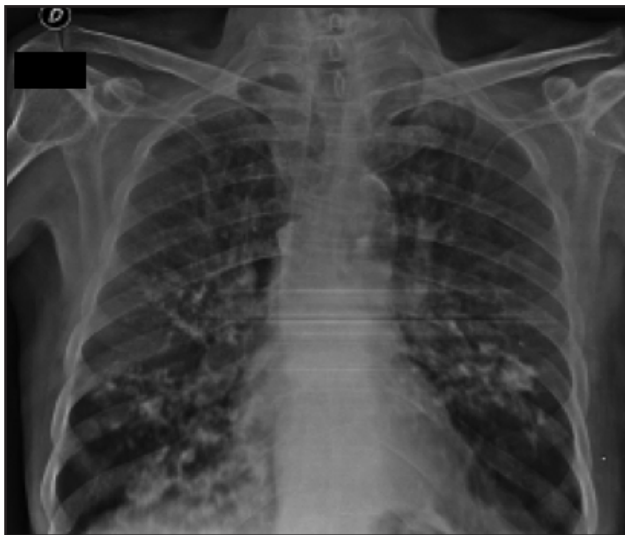
Project academic non-profit, developed under the open access initiative

## Pulmonary alveolar microlithiasis An incidental finding in a patient with COPD

JUAN PABLO GARCÍA-MARMOLEJO, MANUEL DAVID MAYORAL-VALENCIA • CALI (COLOMBIA)

DOI: <https://doi.org/10.36104/amc.2021.1990>

A 67-year-old male with a history of chronic obstructive pulmonary disease and heavy smoking consulted due to progressive



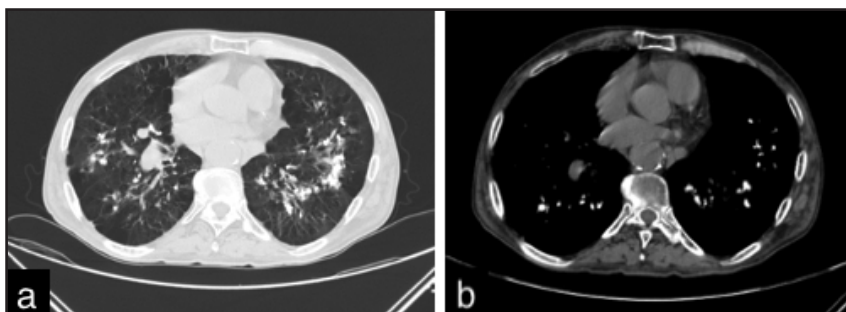
**Figure 1.** Chest x-ray showing a dense, bilateral micronodular pattern in the perihilar region.

worsening of his dyspnea over the previous week along with a dry cough and unquantified fever at home. A chest x-ray showed bilateral calcified micronodules. A high-resolution computerized tomography confirmed these findings. The diagnosis was confirmed by the histological results of a bronchoalveolar lavage showing characteristic laminar microliths.

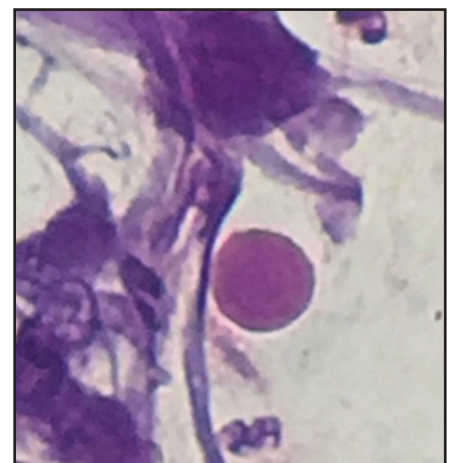
Pulmonary alveolar microlithiasis is a rare hereditary pulmonary disease characterized by microcalcifications within the alveolar spaces (1). It is caused by mutations of the SCL34A2 gene which encodes the phosphate cotransporter in type II alveolar cells. This results in increased phosphate and calcium in lung surfactant, which leads to the formation and deposition of microliths within the alveoli as well as in other parts of the body (2). The definitive diagnosis requires histological identification of the microliths (3).

### References

1. Menon PD, Hackman S. Pulmonary Alveolar Microlithiasis: An Isolated Case in a Hispanic Male. *Case Rep Pathol.* 2020;1–4.
2. Shaw BM, Shaw SD, McCormack FX. Pulmonary Alveolar Microlithiasis. *Semin Respir Crit Care Med.* 2020;41(2):280–7.
3. Tachibana T, Hagiwara K, Johkoh T. Pulmonary alveolar microlithiasis: Review and management. *Curr Opin Pulm Med.* 2009;15(5):486–90.



**Figure 2.** Axial high-resolution computerized tomography of the chest: A. Mediastinal window showing multiple bilateral calcified densities in the lower lobes. B. Pulmonary window showing bilateral calcified interlobular micronodular hyperdensities.



**Figure 3.** Hematoxylin and eosin staining of bronchoalveolar lavage liquid (100x) showing the presence of calcospherites.

Juan Pablo García-Marmolejo: Estudiante de Medicina, Departamento de Clínicas Médicas, Pontificia Universidad Javeriana; Dr. Manuel David Mayoral-Valencia: Internista. Profesor Departamento de Clínicas Médicas, Pontificia Universidad Javeriana. Cali (Colombia).

Correspondencia: Dr. Juan Pablo García-Marmolejo. Cali (Colombia). E-Mail: [jpgarciamarmolejo@gmail.com](mailto:jpgarciamarmolejo@gmail.com)

Received: 15/VIII/2020 Accepted: 27/X/2020

