



Extranodal Natural Killers/T Cell's Lymphoma: A case report

Linfoma de células T/Natural Killers extranodal: reporte de un caso

Olivia Blanco Pita¹ , Carlos L. Pérez Hernández^{2*} , Leandro Moya Díaz³

¹Hospital Docente Clínico Quirúrgico Manuel Fajardo. La Habana, Cuba.

²Universidad Ciencias Médicas de La Habana, Instituto de Ciencias Básicas y Preclínicas Victoria de Girón. La Habana, Cuba.

³Hospital Militar Central "Dr. Luis Díaz Soto". La Habana, Cuba.

*Corresponding Author carlosph@infomed.sld.cu

How to cite this article

Blanco Pita O, Pérez Hernández CL, Moya Díaz L: Extranodal Natural Killers/T Cell's Lymphoma: A case report. Rev haban cienc méd [Internet]. 2023 [cited]; 22(2) e5037; Available from: <http://www.revhabanera.sld.cu/index.php/rhab/article/view/5037>

Received: september 22, 2022

Approved: March 12, 2023

ABSTRACT

Introduction: Extranodal Natural Killers/T Cell's lymphomas are uncommon diseases with a higher incidence in the regions of East Asia and Central and South America and are associated with the Epstein-Barr virus. These neoplasms have a tendency to affect the facial midline, mainly the nasal and paranasal regions. These diseases develop an angiocentric growth pattern with necrosis. These lymphomas have aggressive behavior and high mortality.

Objective: The objective of this work is to present a rare case of NK/T-cell lymphoma, which should be taken into account since its late diagnosis influences the high lethality and poor survival.

Case Presentation: Here we present a case of an Extranodal Natural Killers/T Cell's lymphoma in a 21 years old male with a febrile picture of long-standing evolution (3 months), nasal obstruction, weight loss, and swelling of the zygomatic arch, accompanied by tumor infiltration, destruction of the palate, and purulent discharge through the left eye. The symptoms and signs occurred over a period of approximately 4 months, with a progressive deterioration of the patient.

Conclusions: Even though Extranodal Natural Killers/T Cell's lymphoma is an uncommon disease, it has an aggressive clinical course with poor prognosis and survival. Therefore, it should be considered in the differential diagnosis of nasal or paranasal swelling.

Keywords:

NK/T-Cell Lymphoma, ENKTL, Natural Killers, Non-Hodgkin Lymphoma, Cancer.

RESUMEN

Introducción: Los linfomas extranodales de células T/Natural Killers son enfermedades poco frecuentes con una mayor incidencia en las regiones de Asia Oriental y América Central y del Sur y están asociados con el virus de Epstein-Barr. Estas neoplasias tienen tendencia a afectar la línea media facial, principalmente las regiones nasales y paranasales. Estas enfermedades desarrollan un patrón de crecimiento angiocéntrico con necrosis. Estos linfomas tienen un comportamiento agresivo y una elevada mortalidad.

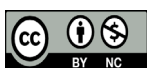Objetivo: El presente trabajo tiene por objetivo presentar un caso raro de linfoma de células T/NK que debe ser tenido en cuenta pues su diagnóstico tardío influye en la alta letalidad y pobre sobrevida.

Presentación del caso: Presentamos un caso de linfoma extranodal de células T/Natural Killers. Varón de 21 años con cuadro febril de larga data de evolución (3 meses) obstrucción nasal, pérdida de peso e hinchazón del arco cigomático. Acompañado de infiltración tumoral, destrucción del paladar y secreción purulenta a través del ojo izquierdo. Los síntomas y signos transcurren en un período de 4 meses aproximadamente, con un deterioro progresivo del paciente.

Conclusiones: Incluso cuando el linfoma extraganglionar de células T/Natural Killers es una enfermedad poco frecuente, tiene un curso clínico agresivo con mal pronóstico y supervivencia. Por lo tanto, debe considerarse en el diagnóstico diferencial del aumento de volumen nasal o paranasal.

Palabras Claves:

Linfoma de células T/NK, ENKTL, Células Natural Killers, Linfoma no Hodgkin, Cáncer.



INTRODUCTION

Extranodal Natural Killers/T Cell's Lymphoma (ENKTL) is a rare disease with a higher incidence in East Asia and Central and South America. The incidence in the United States increased from 0.4 in 2001 to 0.8 in 2014 per 1,000,000 individuals. These neoplasms are closely associated with Epstein-Barr Virus (EBV) infection, and have an aggressive clinical course with poor prognosis and survival.^(1,2)

ENKTL tends to affect the facial midline, mainly the nasal and paranasal regions, presenting an angiocentric growth pattern with necrosis.^(2,3,4,5,6) This lymphoma has an aggressive behaviour, the 5-year overall survival rate for advanced stage IV ENKTL is close to 20% and nearly half of patients die within the first six months.

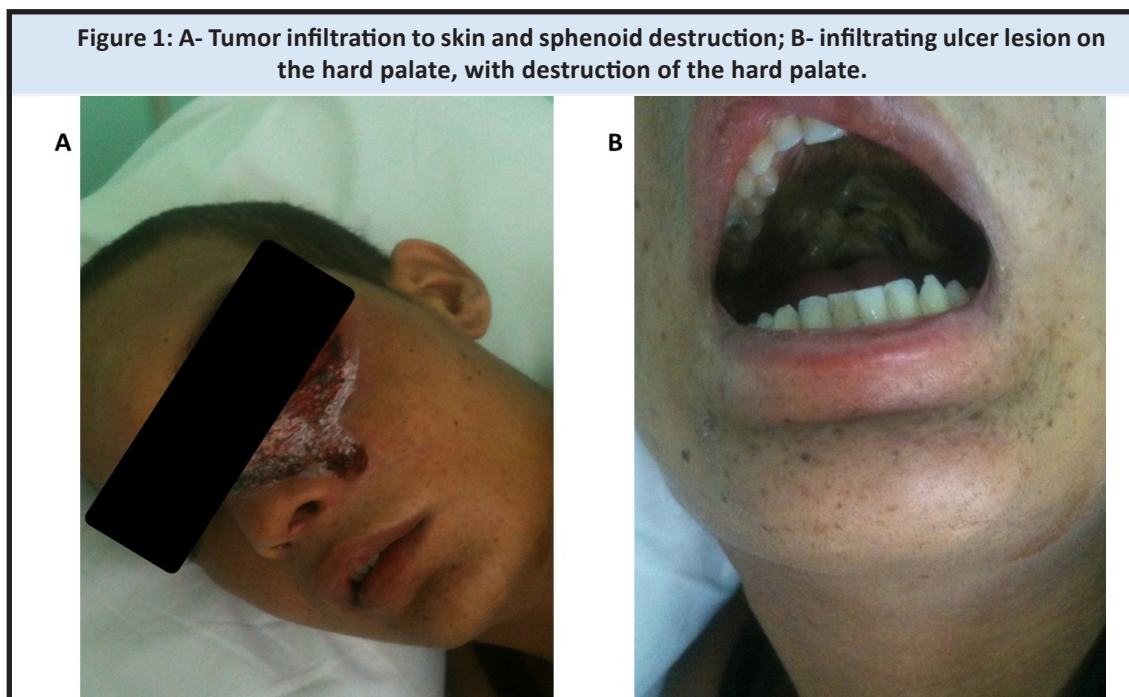The **objective** of this paper is to present a rare case of stage IV Extranodal natural killer/T-cell lymphoma with a torpid clinical course. Although these lymphomas have a low incidence, they should be taken into account when making the diagnosis due to their high mortality and poor survival.

Written informed consent was obtained from the patient and family members for the publication of this case report and any accompanying images.

CASE PRESENTATION

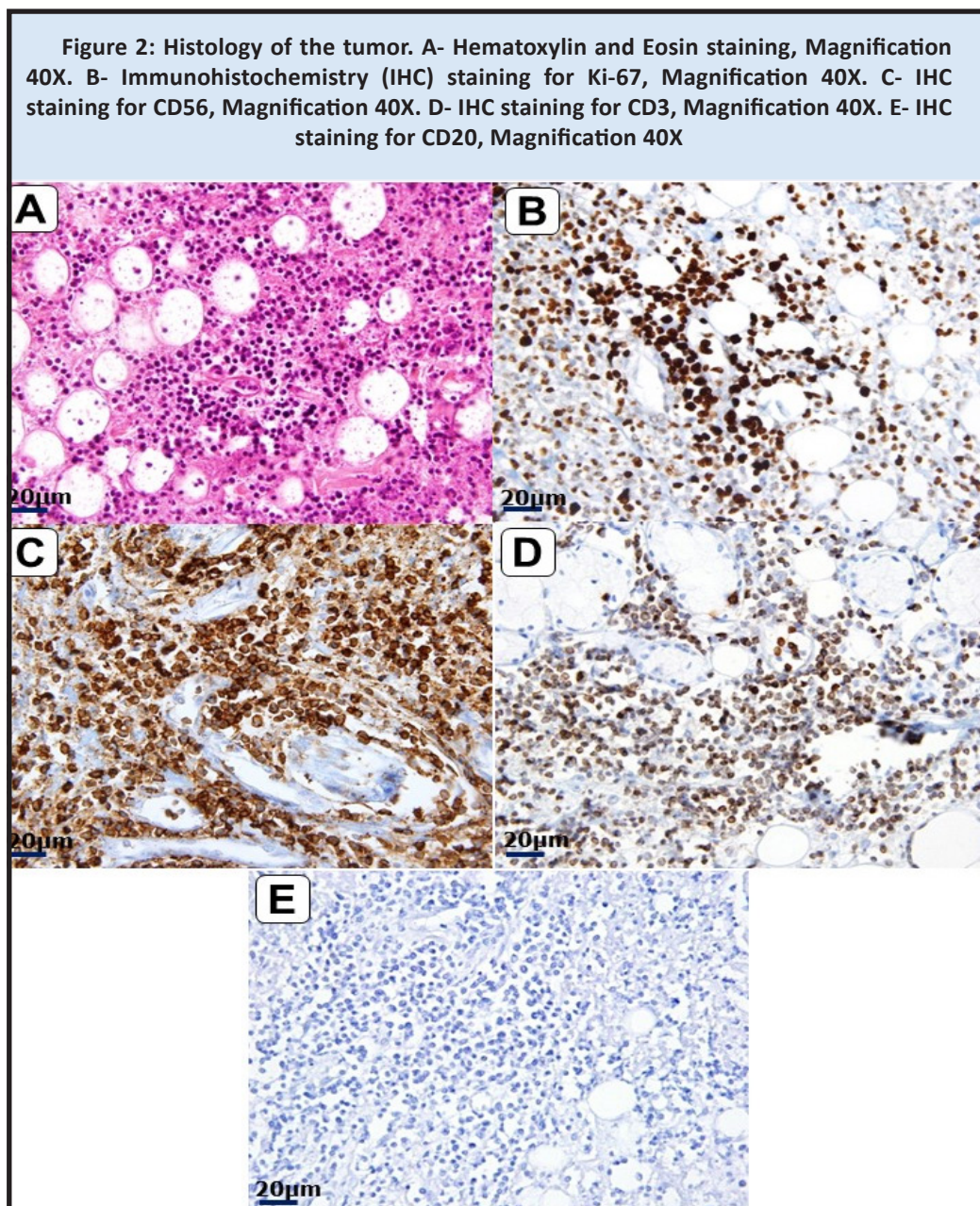
A 21 years old young man with a medical history of asthma presented to the National Institute of Oncology and Radiobiology with a long-term fever (39 °C, mainly in the evening), swelling of the left zygomatic arch, nasal obstruction, nasal drainage, and weight loss (15 Kg in 3 months). The symptoms and signs occurred over a period of approximately 4 months, with a progressive deterioration of the patient.

During the physical examination, swelling of the nasal, zygomatic, and frontal regions, accompanied by tumoral infiltration, destruction of the palate, and purulent secretion from the left eye was verified. The patient also presented severe malnutrition (Figure 1)



Computerized Tomography (CT) scan of the head, neck and thorax and biopsy were indicated. The CT scan showed a hyperdense, heterogenic image occupying the nasal cavity, as well as left maxillary, frontal, and ethmoidal womb with growth of the skin and subcutaneous tissue and extension of the internal angle of the orbit contacting the ocular globe. No secondary cranium-encephalic lesions and no cervical adenopathy were observed. Hyperdense nodular images in the bronchogram suggest an inflammatory process in the upper lobe of the right lung and left pleural leak. Mediastinal lymphadenopathies smaller than 10 mm were found. There were no secondary bone lesions.

Biopsy of the main (nasal) tumour: Lymphoproliferative process histologically consistent with a mid-large cell with marked vascularized and necrosis areas. Immunohistochemistry analyses were positive to cCD3, CD56, Ki-67 (+ 90%) and EBV, and negative for CD20 (Figure 2).



Diagnosis was concluded as Extranodal Natural Killers/T Cell's Lymphoma (ENKTL) nasal type, stage IV. The patient underwent therapy with radiotherapy 50 Gy and Chemotherapy with etoposide, ifosfamide, cisplatin, and dexamethasone (RT-VIPD). There was no observed response to treatment. The patient continued with a decline in the general status, neutropenia, hepato-splenomegaly, and icterus. The patient died two months after the diagnosis.

DISCUSSION

Non-Hodgkin lymphoma is one of the top ten cancer localizations by incidence and mortality. It was responsible for 544 000 new cases and 260 000 deaths worldwide in 2020. In the USA, Lymphoid neoplasms are 34.4/100 000. Extranodal Natural Killers/T Cell's Lymphoma (ENKTL) is a rare subtype of lymphoma with a higher incidence in East Asia and Central and South America and is more frequent in males than in females. In the USA, the reported incidence of ENKTL increased from 0.4 in 2001 to 0.8 in 2014 per 1 000 000 individuals.^(1,7,8,9,10,11,12) To the best knowledge of the author, this paper constitutes the first report of an ENKTL in Cuba and according to the registry of the National Institute of Oncology and Radiobiology, this is the first case diagnosed in this institution at least in the last decade.

Multiple factors have been implicated in the development of ENKTL. Among them, the infection with EBV has been strongly associated with this lymphoma and is implicated in its pathogenesis. Viral LMP activate MYC and NF- κ B. MYC epigenetically induce EZH2 and thus proliferation, while NF- κ B also induce proliferation and stimulate PDL1 and hence immune evasion.^(6,13,14,15)

Genetic risk factors have only been spotted in recent years. Some loci have been associated with ENKTL like IL18RAP promotor and 47F-67I, 47Y-67L, and rs9277378. Those loci control inflammation and immune regulation through the IL18-IL18RAP axis and antigen presentation, involving HLA-DRB1 and HLA-DPB1.^(16,17)

Molecular studies have shown several genetic and epigenetic alterations in ENKTL. Mutation analysis revealed frequent activation of oncogenic pathway and alterations in tumour suppressor genes (TSGs). Mutations mainly affect JAK/STAT pathway, TP53, PRDM1 and DDX3X, which also activate MYC and NF- κ B. Moreover, mutations in genes associated with epigenomic regulation, as well as miRNA and histone methylation (H3K27me3) dysregulation have been reported. Altogether, these stimulate proliferation, immune evasion and inhibits apoptosis. Genomic and transcriptomic profiling have shown to be useful to identify distinct genetic subtypes and potential therapeutic personalization in ENKTL.^(15,18,19,20,21)

Clinical Characteristics

ENKTL usually affects the nasal/upper aerodigestive tract, most frequently the nasal cavity, paranasal sinuses, and nasopharynxes. Less frequent, non-nasal, and metastatic localizations include the gastrointestinal tract, skin, testis, adrenal glands, kidney, breast, and eyes. Lymphadenopathy and bone marrow involvement are less frequent but observable in nearly 20% of cases. The clinical symptoms include nasal obstruction, nasal drainage, facial swelling, and B-symptoms.^(22,23,24)

Diagnosis/morphology

ENKTLs are lymphoid tumors, histologically characterized by a diffuse angiocentric and angio-destructive growth pattern with ischemia and necrosis. Cells may be variable in size but mid or mixed small and large are the most frequent. The neoplastic cells express CD2, and cytoplasmatic CD3 (but not surface CD3) and CD56 and do not express CD20, which is useful for immunohistochemistry (IHC) diagnosis. The proliferation index assessed by the Ki-67 antibody is usually high and is associated with bad prognosis. ENKTL is closely associated with EBV, therefore EBV markers are also detected by IHC.^(3,4,22,25,26)

Treatment and clinical outcome Survival/Prognosis

The treatments usually used for Lymphomas such as Cyclophosphamide, doxorubicin, vincristine, and prednisone (CHOP) or CHOP-like therapies have failed to show sufficient efficacy in ENKTL as they express MDR/ABCB1.^(27,28) Consequently, other treatments have been adopted: Radiotherapy (50-54 Gy) plus dexamethasone, etoposide, ifosfamide, and dexamethasone (RT-DeVIC) and radiotherapy with cisplatin once per week followed by etoposide, ifosfamide, cisplatin, and dexamethasone (CCRT-VIPD). Considering the high expression of P-glycoprotein/MDR in ENKTL, corticosteroid, methotrexate, ifosfamide, L-asparaginase, and etoposide (SMILE) and L-asparaginase, methotrexate, and dexamethasone (AspaMetDex) have been used with better results. But L-asparaginase-containing chemotherapies have a higher incidence of adverse reactions such as liver damage, bone marrow suppression and infection, and death. Also, DDGP (cisplatin, dexamethasone, gemcitabine, and pegaspargase) chemotherapy show improved response and survival compared with SMILE.^(22,23,28,29)

Therefore, in view of the general status of the patient we decide to start treatment with RT-VIPD and not with an L-asparaginase-containing chemotherapy. Even those, the patient continued to decline his status and perished two months after the diagnosis. The overall survival (OS) rate reported for localized stage I/II ENKTL at 5 years is near 70% meanwhile, the OS rate at 5 years for advanced stage IV ENKTL is close to 20% where nearly half of patients die within the first six months. Conditions that increase hazard ratio and decrease OS and progression-free survival (PFS) are B-symptoms Hb <11 g/dL, low platelet, high LDH, involvement of lymphadenopathies, Ki-67 > 60%, stage IV.^(22,23) Several of those conditions were present in our patient.

CONCLUSION

Extranodal Natural Killers/T Cell's Lymphoma (ENKTL) is an uncommon disease which is endemic in East Asia and Central and South America but with less incidence in other regions. These neoplasms tend to affect the facial midline, presenting an angiocentric growth pattern with necrosis and is closely associated with Epstein-Barr Virus (EBV) infection. ENKTL has an aggressive clinical course and poor prognosis and survival. Thus, it should be considered in the differential diagnosis of nasal or paranasal swelling.

REFERENCES

1. Kommalapati A, Tella SH, Ganti AK, Armitage JO. Natural Killer/T-cell Neoplasms: Analysis of Incidence, Patient Characteristics, and Survival Outcomes in the United States. *Clin Lymphoma Myeloma Leuk*. 2018 Jul 1;18(7):475–9.
2. Alaggio R, Amador C, Anagnostopoulos I, Attygalle AD, Araujo IB de O, Berti E, et al. The 5th edition of the World Health Organization Classification of Haematolymphoid Tumours: Lymphoid Neoplasms. *Leukemia* [Internet]. 2022 [Cited 28/09/2022];36(7):1720–48. Available from: <https://www.nature.com/articles/s41375-022-01620-2>
3. Asano N, Kato S, Nakamura S. Epstein–Barr virus-associated natural killer/T-cell lymphomas. *Best Pract Res Clin Haematol*. 2013 Mar;26(1):15–21.
4. Bajor-Dattilo EB, Pittaluga S, Jaffe ES. Pathobiology of T-cell and NK-cell lymphomas. *Best Pract Res Clin Haematol*. 2013 Mar;26(1):75–87.
5. Fox CP, Civallero M, Ko YH, Manni M, Skrypets T, Pileri S, et al. Survival outcomes of patients with extranodal natural-killer T-cell lymphoma: a prospective cohort study from the international T-cell Project. *Lancet Haematol*. 2020 Apr 1;7(4):e284–94.

6. Peng RJ, Han BW, Cai QQ, Zuo XY, Xia T, Chen JR, et al. Genomic and transcriptomic landscapes of Epstein-Barr virus in extranodal natural killer T-cell lymphoma. *Leukemia* [Internet]. 2019;33(6):1451–62. Available from: <https://doi.org/10.1038/s41375-018-0324-5>
7. Torre LA, Bray F, Siegel RL, Ferlay J, Lortet-Tieulent J, Jemal A. Global cancer statistics, 2012. *CA Cancer J Clin*. 2015 Mar 1;65(2):87–108.
8. Torre LA, Siegel RL, Ward EM, Jemal A. Global Cancer Incidence and Mortality Rates and Trends-An Update. *Cancer Epidemiology Biomarkers Prevention*. 2016 Jan 12;25(1):16 – 27.
9. Teras LR, DeSantis CE, Cerhan JR, Morton LM, Jemal A, Flowers CR. 2016 US lymphoid malignancy statistics by World Health Organization subtypes. *CA Cancer J Clin*. 2016 Nov 12;66(6):443-459.
10. William BM, Armitage JO. International analysis of the frequency and outcomes of NK/T-cell lymphomas. *Best Pract Res Clin Haematol*. 2013 Mar;26(1):23–32.
11. Jhuang JY, Chang ST, Weng SF, Pan ST, Chu PY, Hsieh PP, et al. Extranodal natural killer/T-cell lymphoma, nasal type in Taiwan: a relatively higher frequency of T-cell lineage and poor survival for extranasal tumors. *Hum Pathol*. 2015 Feb;46(2):313–21.
12. Sung H, Ferlay J, Siegel RL, Laversanne M, Soerjomataram I, Jemal A, et al. Global Cancer Statistics 2020: GLOBOCAN Estimates of Incidence and Mortality Worldwide for 36 Cancers in 185 Countries. *CA Cancer J Clin* [Internet]. 2021 May 1 [Cited 06/07/2022];71(3):209–49. Available from: <https://onlinelibrary.wiley.com/doi/full/10.3322/caac.21660>
13. Saleem A, Natkunam Y. Extranodal NK/T-Cell Lymphomas: The Role of Natural Killer Cells and EBV in Lymphomagenesis. *International Journal of Molecular Sciences* [Internet]. 2020 Feb 22 [Cited 28/09/2022];21(4):1501. Available from: <https://www.mdpi.com/1422-0067/21/4/1501/htm>
14. Montes-Mojarro IA, Fend F, Quintanilla-Martinez L. EBV and the Pathogenesis of NK/T Cell Lymphoma. *Cancers* [Internet]. 2021 Mar 19 [Cited 28/09/2022];13(6):1414. Available from: <https://www.mdpi.com/2072-6694/13/6/1414/htm>
15. De Mel S, Soon GST, Mok Y, Chung TH, Jeyasekharan AD, Chng WJ, et al. The genomics and molecular biology of natural killer/T-cell lymphoma: Opportunities for translation. *Int J Mol Sci* [Internet]. 2018 [Cited 28/09/2022];19(7). Available from: www.mdpi.com/journal/ijms
16. Lin GW, Xu C, Chen K, Huang HQ, Chen J, Song B, et al. Genetic risk of extranodal natural killer T-cell lymphoma: a genome-wide association study in multiple populations. *Lancet Oncol*. 2020 Feb 1;21(2):306–16.
17. Li Z, Xia Y, Feng LN, Chen JR, Li HM, Cui J, et al. Genetic risk of extranodal natural killer T-cell lymphoma: a genome-wide association study. *Lancet Oncol*. 2016 Sep 1;17(9):1240–7.
18. Dong G, Liu X, Wang L, Yin W, Bouska A, Gong Q, et al. Genomic profiling identifies distinct genetic subtypes in extra-nodal natural killer/T-cell lymphoma. *Leukemia* [Internet]. 2022 Jun 13 [Cited 28/09/2022];36(8):2064–75. Available from: <https://www.nature.com/articles/s41375-022-01623-z>
19. Song TL, Nairismägi ML, Laurensia Y, Lim JQ, Tan J, Li ZM, et al. Oncogenic activation of the STAT3 pathway drives PD-L1 expression in natural killer/T-cell lymphoma. *Blood* [Internet]. 2018 Sep 13 [Cited 11/09/2022];132(11):1146–58. Available from: <https://ashpublications.org/blood/article/132/11/1146/39381/Oncogenic-activation-of-the-STAT3-pathway-drives>.
20. Xiong J, Cui BW, Wang N, Dai YT, Zhang H, Wang CF, et al. Genomic and Transcriptomic Characterization of Natural Killer T Cell Lymphoma. *Cancer Cell*. 2020 Mar 16;37(3):403-419.e6.
21. Zhang Y, Li C, Xue W, Zhang M, Li Z. Frequent Mutations in Natural Killer/T Cell Lymphoma. *Cellular Physiology and Biochemistry* [Internet]. 2018 Sep 1 [Cited 11/09/2022];49(1):1–16. Available from: <https://www.karger.com/Article/FullText/492835>
22. Li S, Feng X, Li T, Zhang S, Zuo Z, Lin P, et al. Extranodal NK/T-cell Lymphoma, Nasal Type: A Report of 73 Cases at MD Anderson Cancer Center. *Am J Surg Pathol* [Internet]. 2013 [Cited 11/09/2022];37(1). Available from: http://journals.lww.com/ajsp/Fulltext/2013/01000/Extranodal_NK_T_cell_Lymphoma,_Nasal_Type_A.2.aspx
23. Yamaguchi M, Suzuki R, Oguchi M, Asano N, Amaki J, Akiba T, et al. Treatments and Outcomes of Patients With Extranodal Natural Killer/T-Cell Lymphoma Diagnosed Between 2000 and 2013: A Cooperative Study in Japan. *J Clin Oncol*. 2017 Jan;35(1):32-39.
24. Tse E, Kwong YL. NK/T-cell lymphomas. *Best Pract Res Clin Haematol*. 2019 Sep 1;32(3):253–61.
25. Suzuki R. Pathogenesis and Treatment of Extranodal Natural Killer/T-Cell Lymphoma. *Semin Hematol*. 2014 Jan;51(1):42–51.
26. Tse E, Au-Yeung R, Kwong YL. Recent advances in the diagnosis and treatment of natural killer/T-cell lymphomas. *Expert Rev Hematol* [Internet]. 2019 Nov [Cited 28/09/2022];12(11):927-935 Available from: <https://pubmed.ncbi.nlm.nih.gov/31487202/>
27. Yamaguchi M, Suzuki R, Oguchi M. Advances in the treatment of extranodal NK/T-cell lymphoma, nasal type. *Blood* [Internet]. 2018 Jun 7 [Cited 28/09/2022];131(23):2528–40. Available from: <https://ashpublications.org/blood/article/131/23/2528/36945/Advances-in-the-treatment-of-extranodal-NK-T-cell>

28. Van Doesum JA, Niezink AGH, Huls GA, Beijert M, Diepstra A, van Meerten T. Extranodal Natural Killer/T-cell Lymphoma, Nasal Type: Diagnosis and Treatment. *Hemasphere* [Internet]. 2021 Feb 12 [Cited 28/09/2022];5(2):e523. Available from: <https://pubmed.ncbi.nlm.nih.gov/33458595/>

29. Wang X, Hu J, Dong M, Ding M, Zhu L, Wu J, et al. DDGP vs. SMILE in Relapsed/Refractory Extranodal Natural Killer/T-cell Lymphoma, Nasal Type: A Retrospective Study of 54 Patients. *Clin Transl Sci* [Internet]. 2021 Jan 1 [Cited 28/09/2022];14(1):405–11. Available from: <https://onlinelibrary.wiley.com/doi/full/10.1111/cts.12893>

Conflict of interest

The authors declare there are no conflicts of interest regarding the publication of this article.

Authors' contributions

Olivia Blanco Pita: Conceptualization, methodology, investigation, formal analysis, resources, visualization, supervision, writing-original draft, writing-review & editing.

Carlos L. Pérez Hernández: Conceptualization, methodology, investigation, formal analysis, resources, visualization, supervision, writing-original draft, writing-review & editing.

Leandro Moya Díaz: formal analysis, writing-original draft, writing-review & editing.

All authors had full access to the data in the study and take responsibility for the integrity of the data and accuracy of the data analysis.



Available in:

<https://www.redalyc.org/articulo.oa?id=180482305011>

[How to cite](#)

[Complete issue](#)

[More information about this article](#)

[Journal's webpage in redalyc.org](#)

Scientific Information System Redalyc
Diamond Open Access scientific journal network
Non-commercial open infrastructure owned by academia

Olivia Blanco Pita, Carlos L. Pérez Hernández,
Leandro Moya Díaz

Extranodal Natural Killers/T Cell 's Lymphoma: A case report

Linfoma de células T/Natural Killers extranodal: reporte de un caso

Revista Habanera de Ciencias Médicas

vol. 22, no. 2, e5037, 2023

Universidad de Ciencias Médicas de la Habana,

ISSN-E: 1729-519X