



Surgical & Cosmetic Dermatology

ISSN: 1984-5510

ISSN: 1984-8773

Sociedade Brasileira de Dermatologia

Barros, Juliano Cesar de; Almeida, Isabella Parente; Barros, Jefferson Alfredo de; Munoz, Andrés Mauricio Lopez; Filho, Carlos D'Apparecida Santos Machado  
Opções cirúrgicas no vitiligo: enxerto de raspado cutâneo  
e suspensão epidérmica diluídos em ácido hialurônico gel  
Surgical & Cosmetic Dermatology, vol. 12, no. 4, 2020, October-November, pp. 369-372  
Sociedade Brasileira de Dermatologia

DOI: <https://doi.org/10.5935/scd1984-8773.20201243576>

Available in: <https://www.redalyc.org/articulo.oa?id=265568335012>

- How to cite
- Complete issue
- More information about this article
- Journal's webpage in redalyc.org

redalyc.org

Scientific Information System Redalyc

Network of Scientific Journals from Latin America and the Caribbean, Spain and Portugal

Project academic non-profit, developed under the open access initiative

# Surgical options in vitiligo: skin graft and epidermal suspension diluted in hyaluronic acid gel

*Opções cirúrgicas no vitiligo: enxerto de raspado cutâneo e suspensão epidérmica diluídos em ácido hialurônico gel*

DOI: <http://www.dx.doi.org/10.5935/scd1984-8773.20201243576>

## ABSTRACT

**Introduction:** Vitiligo is an acquired skin dyschromia characterized by the physical and/or functional reduction of melanocytes. We present two surgical proposals for the treatment of vitiligo.

**Case reports:** 1) Implant of skin graft diluted in hyaluronic acid gel: We obtained the material through curettage, diluted it in hyaluronic acid gel, and applied it to receptor areas. 2) Epidermal suspension obtained through curettage and diluted in hyaluronic acid gel: After the curettage of the donor area, we treated the material with trypsin-EDTA, centrifuged it, and diluted it in hyaluronic acid gel. The receptor area received the graft.

**Conclusion:** These are safe, easy, and satisfactory surgical procedures for the presented cases.

**Keywords:** Vitiligo; Keratinocytes; Ambulatory surgical procedures

## RESUMO

**Introdução:** vitiligo é dermatose caracterizada por redução física e/ou funcional dos melanócitos. Apresentamos duas propostas cirúrgicas para tratamento do vitiligo.

**Relato de caso:** 1) Implante de enxerto cutâneo diluído em gel de ácido hialurônico: material obtido a partir de curetagem da área doadora, diluído em ácido hialurônico gel e aplicado na área receptora. 2) Suspensão não cultivada obtida por curetagem e diluída em gel de ácido hialurônico: material obtido por curetagem da área doadora é tratado com tripsina, centrifugado, diluído em ácido hialurônico gel e aplicado na área receptora.

**Conclusão:** Trata-se de técnicas seguras, de fácil execução e com resultado satisfatório nos casos apresentados.

**Palavras-chave:** Vitiligo; Procedimentos cirúrgicos menores; Queratinócitos

## INTRODUCTION

Vitiligo is an acquired, idiopathic cutaneous dyschromia characterized by physical and functional reduction of melanocytes. The global prevalence is around 0.5% to 1%. Clinically, it presents achromic macules and patches of different sizes and forms.<sup>1</sup> Stable vitiligo cases resistant to clinical treatment are candidates for surgical treatment, including non-cultured epidermal suspension grafts treated enzymatically with trypsin 0.25%; thin dermo-epidermal skin grafts; suction blister epidermal grafts (SBEG); total punch grafting; epidermal grafting or in vitro isolation; and culture of melanocytes.<sup>2,3</sup>

## How I do?

### Authors:

Juliano Cesar de Barros<sup>1</sup>  
Isabella Parente Almeida<sup>1</sup>  
Jefferson Alfredo de Barros<sup>1</sup>  
Andrés Mauricio Lopez Munoz<sup>1</sup>  
Carlos D'Apparecida Santos  
Machado Filho<sup>1</sup>

<sup>1</sup> Department of Dermatology,  
Faculdade de Medicina do ABC,  
São Paulo (SP), Brazil.

### Correspondence:

Isabella Parente Almeida  
Departamento de Dermatologia  
Av. Príncipe de Gales, 821  
09060-870 Santo André (SP)  
E-mail: isabellaparente@hotmail.com

Received on: 23/08/2020

Approved on: 06/12/2020

Study conducted at the Faculdade de  
Medicina do ABC, São Paulo (SP), Brazil.

Financial support: None.

Conflict of interest: None.



Additionally, Machado (2000)<sup>3</sup> demonstrated the feasibility of obtaining material for grafting through simple epidermal curettage of the donor area to be implanted in a recipient area, also curetted. The obtained graft is humidified with physiological saline to obtain a “paste”; it is applied to the recipient area and fixed with an adhesive semi-permeable membrane.

The present article describes two surgical techniques for treating vitiligo, considering variations of the curettage technique used for obtaining the graft from the donor area.

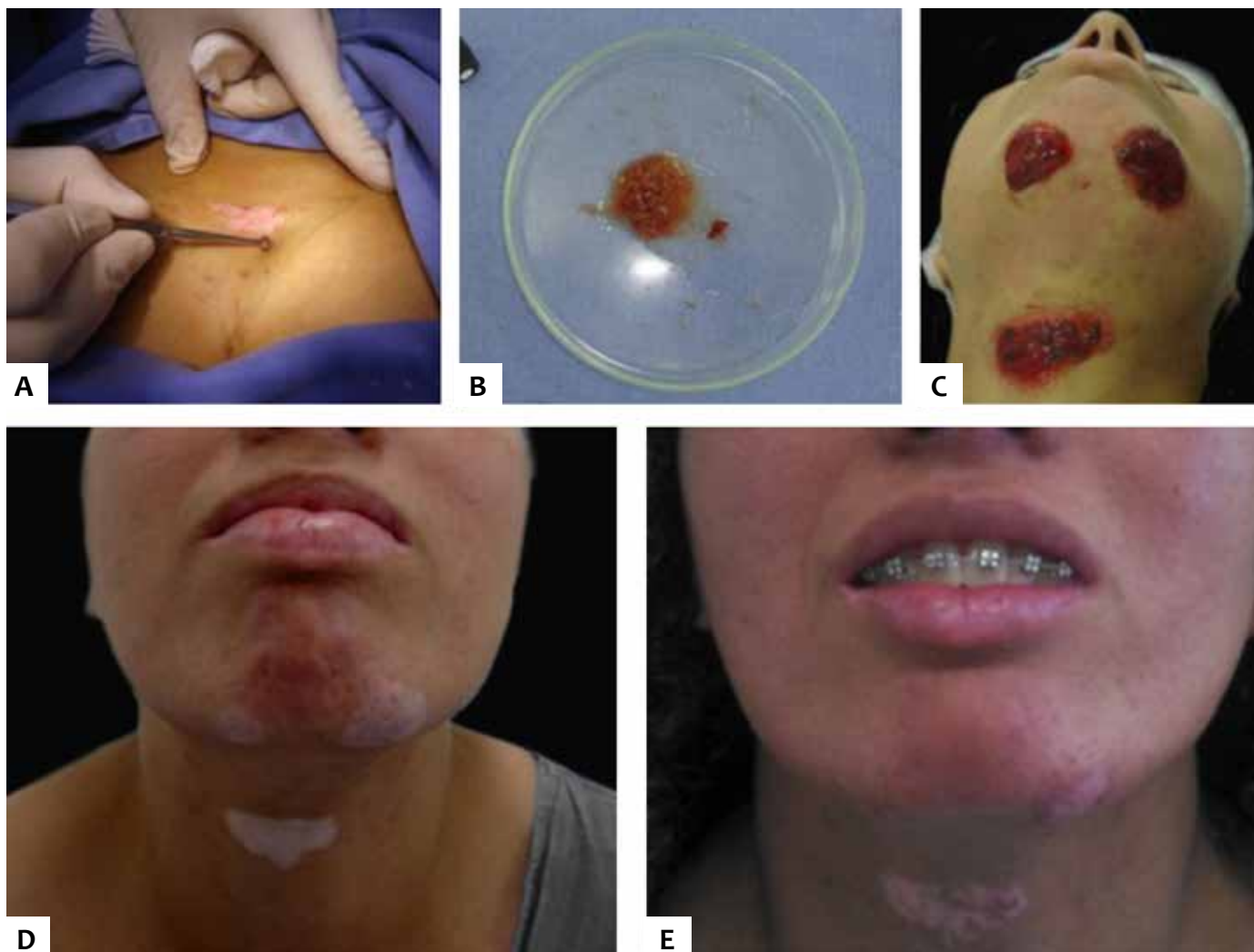
#### **Implant of epidermal curettage graft diluted in hyaluronic acid gel**

The technique's characteristic is the dilution of the obtained graft in a gel of hyaluronic acid. This biocompatible and hygroscopic substance provides greater viability and adhesion to the receptor area.<sup>4</sup> The curettage of the donor area to the papillary dermis obtains the material (Figure 1A). It is then diluted

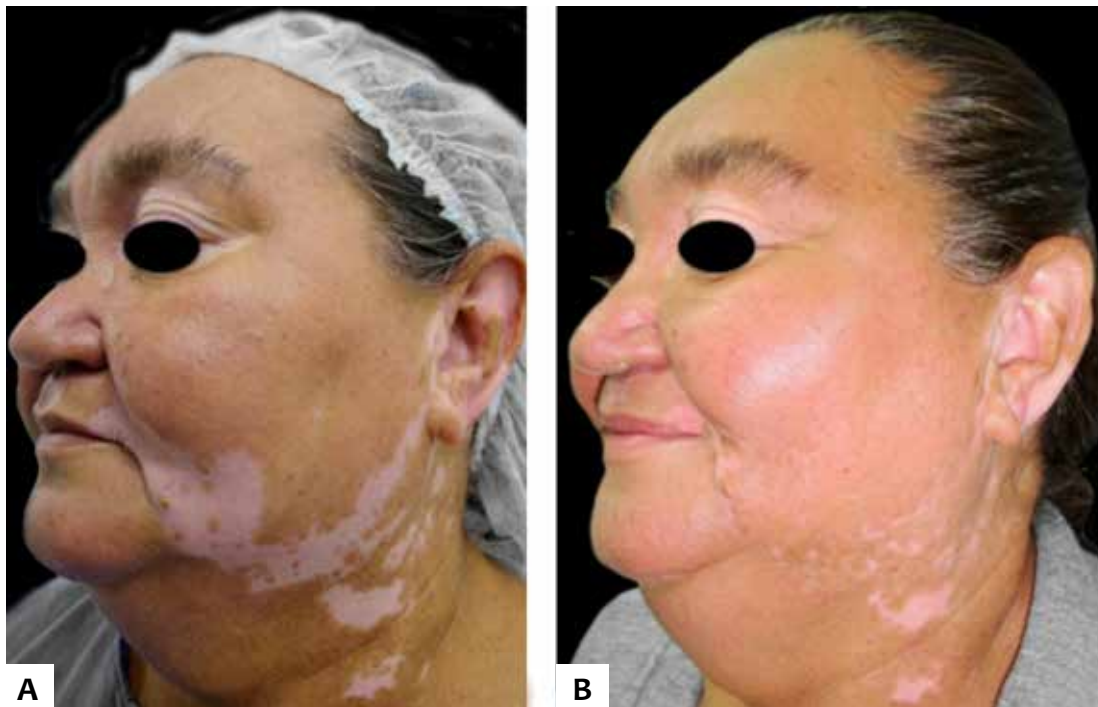in 1–2 ml of hyaluronic acid gel at 0.5–2% (Figure 1B) (Figure 1B). The recipient area is also curetted reaching the papillary dermis and obtaining the same size as the donor area. Finally, the graft is applied over the recipient area (Figure 1C) and covered with a dressing of porous membrane of cellulose, maintained in site for seven days. Topical medications and phototherapy are reintroduced 14 days after the procedure. Satisfactory results are observed after 90 days (Figure 1D and 1E).

#### **Non-cultured melanocyte-keratinocyte cells suspension obtained by curettage and diluted in hyaluronic acid gel**

It corresponds to the association of the techniques curettage grafting and uncultured epidermal suspension methods. Mulekar (2003 and 2005)<sup>5,6</sup> and van Geel (2001)<sup>2</sup> initially described the use of hyaluronic acid in epidermal suspensions. After curettage of the donor area until the onset of the papillary



**FIGURE 1:** Implant of curetted skin graft diluted in hyaluronic acid gel. **A** - Curettage of the donor area. **B** - Graft diluted in hyaluronic acid gel. **C** - Post-grafting recipient area. **D** - Preoperative. **E**) Postoperative (90 days)



**FIGURE 2:** Uncultivated suspension obtained from curettage with subsequent dilution in hyaluronic acid gel.  
**A** - Preoperative.  
**B** - Postoperative (180 days)

dermis's punctate bleeding, the collected graft is exposed to a proteolytic solution (Trypsin EDTA 0.025% - LGC Biotechnology™ - Brazil) and incubated for 20 minutes at 98.6° Fahrenheit. After incubation, a pipette aspirates the trypsin. The sample is then washed with 0.9% saline solution and transferred to a centrifuge tube containing the DMEM culture medium (LGC Biotechnology™ - Brazil). After six minutes of centrifuging at 1500 rpm, the supernatant of epidermal cells is discarded, and the pellet is suspended in 1-2 ml of hyaluronic acid gel 0.5-2% (Paulista Center for Pharmaceutical Development™ - Brazil). The suspension concentration, which can vary according to the clinical case of vitiligo, generates a donor to receptor area ratio ranging between 1:10 to 1:20. The recipient area is curetted or dermabraded to the papillary dermis. After applying the epidermal graft, it is occluded with a porous cellulose membrane,

which should remain on the site for seven days. The topical medications and phototherapy should be reintroduced after 14 days. Satisfactory results are observed after 90 days and improve 180 days after the procedure (Figures 2A and 2B).

## CONCLUSION

In conclusion, curetting the skin until the papillary dermis is an affordable procedure, easy to perform, which provides a satisfactory sample for grafting. When this technique is associated with hyaluronic acid, it allows greater viability and adherence of the graft to the recipient area. Nowadays, there are not indexed publications of those described techniques, and future studies are necessary for further elucidation and improvement of these treatment modalities.

## ACKNOWLEDGMENTS:

We thank the patients and the Nursing staff: it would not be possible to conduct this study without them. ●

## REFERENCES

1. Singh C, Parsad D, Kanwar AJ, Dogra S, Kumar R. Comparison between autologous noncultured extracted hair follicle outer root sheath cell suspension and autologous noncultured epidermal cell suspension in the treatment of stable vitiligo: a randomized study. *Br J Dermatol*. 2013;169(2):287-93.
2. Van Geel N, Ongenae K, Nayaert JM. Surgical techniques for vitiligo: a review. *Dermatology*. 2001;202(2):162-6.
3. Machado C. (2000). Vitiligo: áreas tratadas por enxertia com raspado cutâneo e estudo da reação de polimerase em cadeia de RNA mensageiro de tirosinase por transcriptase reversa. (Tese de Doutorado). São Paulo: Universidade Federal de São Paulo.
4. Van Geel N, Ongenae K, De Mil M, Nayaert JM. Modified technique of autologous noncultured epidermal cell transplantation for repigmenting vitiligo: a pilot study. *Dermatol Surg*, 2001;27(10):873-6.
5. Mulekar SV. Melanocyte-keratinocyte cell transplantation for stable vitiligo. *Int J Dermatol*, 2003;42:132-6.
6. Mulekar SV. Long-term follow-up study of 142 patients with vitiligo vulgaris treated by autologous, noncultured melanocyte-keratinocyte cell transplantation. *Int J Dermatol*. 2005;44(10):841-5.

## AUTHORS ' CONTRIBUTION:

**Juliano Cesar de Barros** |  ORCID 0000-0003-1494-7118


Approval of the final version of the manuscript; study design and planning; preparation and writing of the manuscript; data collection, analysis, and interpretation; active participation in research orientation; intellectual participation in propaedeutic and/or therapeutic conduct of studied cases; critical literature review; critical revision of the manuscript.

**Isabella Parente Almeida** |  ORCID 0000-0002-6283-4065


Approval of the final version of the manuscript; study design and planning; preparation and writing of the manuscript; data collection, analysis, and interpretation; intellectual participation in propaedeutic and/or therapeutic conduct of studied cases; critical literature review; critical revision of the manuscript.

**Jefferson Alfredo de Barros** |  ORCID 0000-0001-5073-0747

Study design and planning; data collection, analysis, and interpretation; active participation in research orientation.

**Andrés Mauricio Lopez Munoz** |  ORCID 0000-0003-2319-2351

Study design and planning; preparation and writing of the manuscript; critical literature review; critical revision of the manuscript.

**Carlos D'Apparecida Santos Machado Filho** |  ORCID 0000-0003-4362-1563

Approval of the final version of the manuscript; study design and planning; active participation in research orientation; critical literature review; critical revision of the manuscript.