



Surgical & Cosmetic Dermatology

ISSN: 1984-5510

ISSN: 1984-8773

Sociedade Brasileira de Dermatologia

Gomides, Mabel Duarte Alves; Berbert, Alceu Luiz Camargo Villela  
Tumor triquilemal proliferante exuberante em jovem  
Surgical & Cosmetic Dermatology, vol. 12, no. 1, Supl., 2020, October-December, pp. 66-69  
Sociedade Brasileira de Dermatologia

DOI: <https://doi.org/10.5935/scd1984-8773.20201241454>

Available in: <https://www.redalyc.org/articulo.oa?id=265568336015>

- How to cite
- Complete issue
- More information about this article
- Journal's webpage in [redalyc.org](https://www.redalyc.org)

redalyc.org

Scientific Information System Redalyc  
Network of Scientific Journals from Latin America and the Caribbean, Spain and  
Portugal

Project academic non-profit, developed under the open access initiative

## Case report

### Authors:

Mabel Duarte Alves Gomides<sup>1</sup>  
Alceu Luiz Camargo Villela  
Berbert<sup>2</sup>

<sup>1</sup> Dermatology Service, Hospital de Clínicas, Universidade Federal de Uberlândia (MG), Brazil.

<sup>2</sup> School of Medicine, Universidade Federal de Uberlândia, Uberlândia (MG), Brazil.

### Correspondence:

Mabel Duarte Alves Gomides  
Av. Pará, 1720  
Bairro Umuarama  
38405-320 Uberlândia (MG)  
E-mail: mabel@dermaclinicagoias.com.br

Received on: 07/09/2019

Approved on: 02/11/2020

Study conducted at the Dermatology Service, Hospital de Clínicas, Federal University of Uberlândia, Uberlândia (MG), Brazil.

Financial support: None.

Conflict of interest: None.

### Acknowledgment:

We thank the residents Nayara Fayad Souza Dib and Núbia Carvalho Pena de Oliveira Praeiro Alves, who participated in the case report under the guidance of assistant physician Dr. José Joaquim Rodrigues.



# Exuberant Proliferating Trichilemmal Tumor in a young person

*Tumor triquilemal proliferante exuberante em jovem*

DOI: <https://www.dx.doi.org/10.5935/scd1984-8773.20201241454>

## ABSTRACT

Proliferating Trichilemmal Tumor (PTT) is an uncommon benign neoplasm that usually affects adult women over 60 years old, preferably as a solitary nodule in the scalp. We report a case of PTT in a young woman presenting exuberant, asymptomatic scalp tumors 7 years ago, which recurred after surgical exeresis. The histopathology confirmed the diagnosis, and surgical excisions and clinical follow-up were performed. PTT appears to originate from the wall of trichilemmal cysts, from the isthmus of the hair follicle's outer root sheath. Usually, it has benign biological potential with a low risk of malignancy and high recurrence. The therapy of choice is surgery.

**Keywords:** Cysts; Neoplasms; Scalp

## RESUMO

*Tumor triquilemal proliferante (TTP) é uma neoplasia benigna incomum que acomete, habitualmente, mulheres adultas acima de 60 anos, preferencialmente como nódulo solitário no couro cabeludo. Relata-se um caso de TTP em mulher jovem, apresentando exuberantes tumorações assintomáticas no couro cabeludo, há sete anos, que recorreram após exéreses cirúrgicas. O histopatológico confirmou o diagnóstico, tendo sido realizadas retiradas cirúrgicas e acompanhamento clínico. O TTP parece originar-se da parede dos cistos triquilemais, provenientes do istmo da bainha radicular externa do folículo piloso. Geralmente, apresenta potencial biológico benigno, com baixo risco de malignização e elevada recorrência. A terapia de escolha é a cirurgia.*

**Palavras-chave:** Cistos; Couro Cabeludo; Neoplasias

## INTRODUCTION

Proliferating trichilemmal tumor (PTT) is an epidermal adnexal neoplasia formed by several cysts containing squamous epithelium with trichilemmal keratinization, in other words, the abrupt transition of a nucleated epithelial cells to an anucleated in the absence of a granular layer.<sup>1-3</sup> PTT usually appears as a dermal nodule or solitary subcutaneous scalp of elderly women.<sup>1,3-13</sup> It was first described by Wilson-Jones in 1966, who named it a proliferating epidermoid cyst due to its clinical and histological resemblance to squamous cell carcinoma.<sup>1,3, 5,9-13</sup> Since then, PTT has received several other names, such as scalp pilaris tumor, proliferating trichilemmal cyst, trichilemic pillar tumor, invasive pilomatrixoma, hydatid keratinous cyst, trichoclamidocarcinoma, giant hair matrix tumor, hairy scalp tumor, and others.<sup>1,3,6</sup> It exhibits the ability to grow rapidly over

a given period of time, but the evolution to malignant PTT is uncommon.<sup>5,7,11,12</sup> Therefore, it presents heterogeneous histological behaviors ranging from benign, locally aggressive growth with chances of causing invasions in the underlying tissue layers up to that time, with local recurrence metastatic potential and regional lymph node metastasis.<sup>3,10,11,12</sup> PTT is a rare tumor that corresponds to 0.1% of benign cutaneous tumors and may form from a pre-existing or concomitant trichilemmal cyst or as an isolated lesion.<sup>5,11,12</sup>

### CLINICAL CASE

We report the history of a 24-year-old female patient from Uberlândia (MG), treated at the dermatology department of the Clinical Hospital of the Federal University of Uberlândia, complaining of painless nodules in scalp for seven years ago. It refers to progressive growth in recent months, followed by ulceration with output of bloody discharge. Reports recurrence of previously excised scalp lesions. She denies having suffered any kind of trauma.

Dermatological examination showed exophytic, painless, ulcerated tumor with sanguinolent exudation, measuring 10x5 cm in size, in the left parietal region (Figure 1), and several other smooth-surface tumors, soft consistency, measuring 1 to 3 cm in diameter, distributed on the scalp, some surrounded by alopecia (Figure 2). There was no palpable adenomegaly in the cervical and scalp. Two lesions were excised (Figure 3), whose pathological examination showed squamous cell proliferation in the dermis with formation of tumors with irregular multiple lobules of varying sizes, differentiating into large keratinocytes with dis-

crete atypia, abrupt keratinization with foci of calcification and absence of invasion of adjacent tissues (Figure 4).

Trichilemmal tumor, pilomatrixoma, protuberant dermatofibrosarcoma was clinically suspected, but the correlation between clinical and histopathological findings confirmed the diagnosis of PTT.

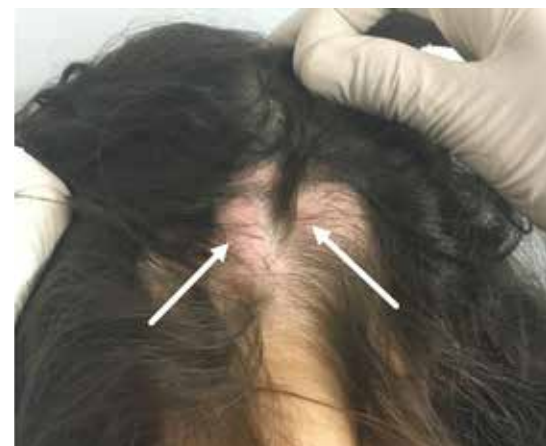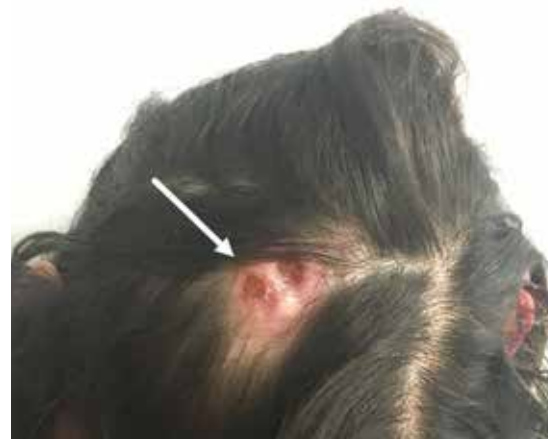Surgical treatment of some lesions has been proposed, with wide margin exercises and simple interrupted suture with good healing results. Due to the recurrent nature of the lesions, the patient remains in outpatient clinical follow-up and other injuries are scheduled.

### DISCUSSION

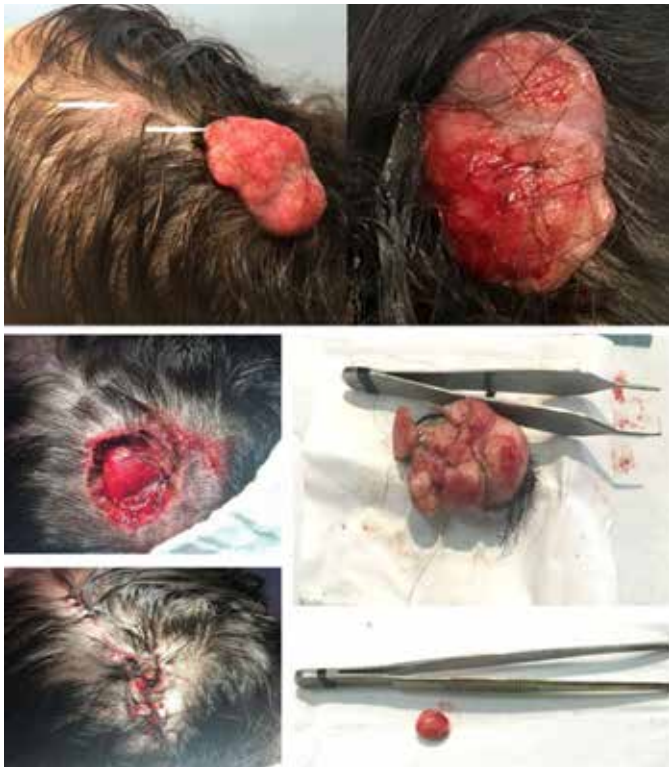Trichilemmal cysts correspond to 20% of cutaneous cysts, the others classified as epidermoid cysts originating from trichilemmal or external root sheath of the hair follicle.<sup>1,11</sup> PTT seems to originate from these lesions, presumably after inflammation or trauma, due to the fact that have areas with benign characteristics and others with malignant properties.<sup>1,5-12</sup> It differs from the trichilemmal cyst because it is uncommon, larger, and histologically more atypical, and the malignant proliferative trichilemmal tumor is less aggressive.<sup>9</sup> PTT occurs more frequently in women (79,5-87% of cases)



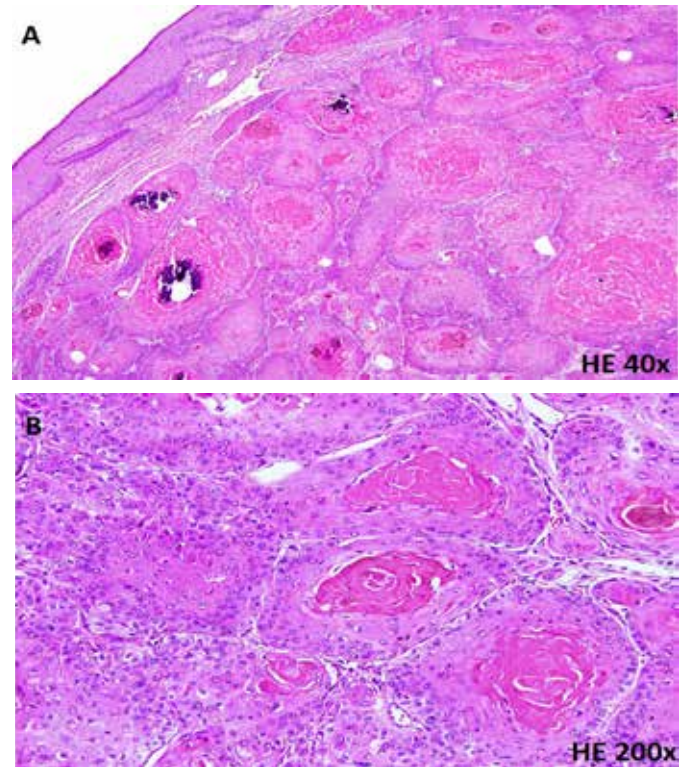
**FIGURE 1:** Exophytic, ulcerated, 10x5 cm tumor with sanguinolent exudation on the left parietal region



**FIGURE 2:** Soft, smooth, some ulcerated tumors, 1 to 3 cm, surrounded by an area of alopecia on the scalp



**FIGURA 3:** Extensive excision of two proliferating trichilemmal tumors on the scalp



**FIGURE 4:** (A) Dermal tumor with multiple lobules varying in sizes, squamous cell proliferation with abrupt keratinization and foci of calcification. (B) Squamous epithelial lobules with discrete atypia associated with amorphous keratin mass and absence of inflammatory infiltrate

with ages ranging from 21 to 88 years, mean 62.4 years, despite reports in children under 18 years.<sup>1,3,5,10-12</sup> Lesions are usually solitary nodules, smaller than 1 cm to 12 cm (average 3.3 cm), although there are citations of multiple nodules, sometimes ulcerated and larger than 25 cm.<sup>3,10-13</sup> It often presents a history of slow and progressive growth from months to years, followed by fast growth and exophytic appearance.<sup>2,10,12</sup> The preferred location is the scalp (85.4–90% of cases) and sometimes has alopecia.<sup>1,3,5,10-13</sup> The remaining 10% are mostly on the back and more rarely elsewhere, such as frontal, nose, eyelids, lips, oral cavity, neck, trunk, genital, buttocks, upper and lower limbs, and skull base.<sup>1,3,5,10-12</sup> The reported case manifested unusual features, such as the onset of PTT at 17 years, the presence of multiple nodules and some ulcerated lesions. Most of the PTT presents benign biological behavior, but with a chance of recurrence, in a period of six months to more than 10 years after surgery, especially in cases of cleft excision, and in very rare cases may have malignant biological potential.<sup>3,5,10-12</sup> Local recurrence rates (3.7%) and lymph node metastasis (1.2%) are low, but when occur they may cause invasion into deep tissue planes by continuity, contiguity or spread, resulting in high

morbidity rates and even mortality.<sup>3,5,10-12</sup> Some studies have shown the importance of researching Ki-67 immunoeexpression, a protein responsible for cell proliferation, because the expression index correlates with the degree of malignancy of the tumor.<sup>7,8</sup> The differential diagnosis of PTT includes squamous cell carcinoma, basal cell carcinoma, keratoacanthoma, pilomatricoma, sweat gland tumor, protuberant dermatofibrosarcoma, cylindroma, epidermoid cyst, malignant PTT, and angiosarcoma.<sup>1,4,11</sup> Histopathological findings of squamous epithelium lobules, cells with abundant eosinophilic cytoplasm with abrupt keratinization, variable cytological atypia and absence of infiltration into adjacent stroma.<sup>1,4,12,13</sup> PTTs are recurrent and potentially invasive, so, the therapy of choice is surgeries with a margins of 0.5 to 1 cm.<sup>5,7,9-12</sup> Among surgical techniques, Mohs' micrographic surgery has a good indication, because its margins may to exceed visible clinical limits and thus reduce the risk of relapse and metastasis.<sup>5,9,11</sup> Other treatments such as lymph node dissection, radiotherapy, and chemotherapy may be required in cases of metastatic dissemination or transformation to malignant PTT.<sup>5,11</sup> Therefore, long-term follow-up is indispensable.<sup>7,10-12</sup> ●



## REFERENCES

1. Peryassu MA, Peryassu BC, Peryassu RC, Piñeiro-Maceira J, Ramos-e-Silva M. Proliferating trichilemmal tumor: a case on the nose of a 70-year-old man. *Case Rep Dermatol*. 2013;5:248-53.
2. Rosmaninho A, Caetano M, Oliveira A, Almeida TP, Selores M, Alves R. Tumor triquilemal proliferante do nariz. *An Bras Dermatol*. 2012;87:914-6.
3. Ye J, Nappi O, Swanson PE, Patterson JW, Wick MR. Proliferating pilar tumors: a clinicopathologic study of 76 cases with a proposal for definition of benign and malignant variants. *Am J Clin Pathol*. 2004;122:566-74.
4. Miyachi H, Togawa Y, Yamamoto Y, Oguma R, Suehiro K, Matsue H. Proliferating trichilemmal tumour: a comparison of dermoscopic, ultrasonographic and histopathological features. *Eur J Dermatol*. 2016;26:400-2.
5. Capurso-Garcia MA, Bautista-Piña V, Pomerantz A, Galnares-Olalde JA, Blachman-Braun R, Rodríguez-Rodríguez S. Atypical proliferating trichilemmal cyst with malignant breast skin transformation: a case report and review of the literature. *Case Rep Oncol Med*. 2016;7481569. Epub 2016 Jun 14.
6. Deshmukh BD, Kulkarni MP, Momin YA, Sulhyan KR. Malignant proliferating trichilemmal tumor: a case report and review of literature. *J Cancer Res Ther*. 2014; 10:767-9.
7. Rangel-Gamboa L, Reyes-Castro M, Dominguez-Cherit J, Vega-Memije E. Proliferating trichilemmal cyst: the value of Ki67 immunostaining. *Int J Trichology*. 2013;5:115-7.
8. Takeda H, Ikenaga S, Kaneko T, Nakajima K, Harada K; Hanada K et al. Proliferating trichilemmal tumor developing in nevus sebaceous. *Eur J Dermatol*. 2010; 20:664-5.
9. Cavaleiro LH, Viana FO, Carneiro CM, Miranda MF. Proliferating trichilemmal tumor - Case Report. *An Bras Dermatol*. 2011;86:S190-2.
10. Bury Y, Bloxham C. Proliferating trichilemmal tumour. *Diagn Histopathol*. 2009; 15:273-7.
11. Satyaprakash Ak, Sheehan Dj, Sangüeza Op. Proliferating trichilemmal tumors: a review of the literature. *Dermatol Surg*. 2007;33:1102-8.
12. Arcaute LB, Taveras A, González L. Tumor triquilemal proliferante maligno. A propósito de un caso. *DermatologíaCMQ*. 2005;3:346-8.
13. Fonseca TC, Bandeira CL, Sousa BA, Farias TP, Eisenberg ALA. Proliferating trichilemmal tumor: case report. *J Bras Patol Med Lab*. 2016;52:120-3.

## AUTHORS ' CONTRIBUTION:

**Mabel Duarte Alves Gomides** |  ORCID 0000-0003-1253-9428

Approval of the final version of the manuscript; study design and planning; preparation and writing of the manuscript; active participation in research orientation; intellectual participation in propaedeutic and/or therapeutic conduct of studied cases; critical literature review; critical revision of the manuscript.

**Alceu Luiz Camargo Villela Berbert** |  ORCID 0000-0001-8441-7388

Approval of the final version of the manuscript; intellectual participation in propaedeutic and/or therapeutic conduct of studied cases.