



Surgical & Cosmetic Dermatology

ISSN: 1984-5510

ISSN: 1984-8773

Sociedade Brasileira de Dermatologia

Adriano, André Ricardo; Borges, Juliano; Costa, Jordano Luiz da
Carcinoma cuniculatum: lesão positiva para HPV 16 com reconstrução cirúrgica com enxerto abdominal
Surgical & Cosmetic Dermatology, vol. 12, no. 1, Supl., 2020, October-December, pp. 73-75
Sociedade Brasileira de Dermatologia

DOI: <https://doi.org/10.5935/scd1984-8773.20201241472>

Available in: <https://www.redalyc.org/articulo.oa?id=265568336017>

- How to cite
- Complete issue
- More information about this article
- Journal's webpage in redalyc.org

UABM [redalyc.org](https://www.redalyc.org)

Scientific Information System Redalyc

Network of Scientific Journals from Latin America and the Caribbean, Spain and Portugal

Project academic non-profit, developed under the open access initiative

Cuniculatum carcinoma: HPV 16 positive lesion with an abdominal graft surgical reconstruction.

Carcinoma cuniculatum: lesão positiva para HPV 16 com reconstrução cirúrgica com enxerto abdominal

DOI: <https://www.dx.doi.org/10.5935/scd1984-8773.20201241472>

ABSTRACT

The cuniculatum carcinoma is a rare, slow-growth, local aggressive subtype of the squamous cell carcinoma, presented as a verrucous lesion with a low metastasis capacity. Its histopathology shows keratin-filled crypts, and its etiology is linked with HPV, especially 11 and 16 subtypes. The treatment of choice is surgical excision, followed by regular monitoring due to the high risk of local recurrence. We report a case of a woman with Cuniculatum carcinoma treated with surgery with perioperative frozen section procedure, graft, and good evolution.

Keywords: Carcinoma; Carcinoma, Squamous Cell; Foot

RESUMO

O carcinoma cuniculatum consiste em um subtipo raro do carcinoma espinocelular, que se apresenta como uma lesão verrucosa, de crescimento lento, agressividade local e baixa capacidade de produzir metástases. Sua histopatologia revela criptas preenchidas por queratina, e sua etiologia tem ligação com o HPV, principalmente os subtipos 11 e 16. O tratamento de escolha é a excisão cirúrgica, seguida de acompanhamento regular pelo elevado risco de recidiva local. Relata-se caso de paciente feminina, portadora de carcinoma cuniculatum, tratada pela cirurgia com congelamento perioperatório, realização de enxerto e boa evolução.

Palavras-chave: Carcinoma; Carcinoma de Células Escamosas; Pé

INTRODUCTION

Squamous cell carcinoma is the second most common type of skin cancer, behind only basal cell carcinoma.¹ Carcinoma cuniculatum (CC) is a verrucous carcinoma (VC), a rare and indolent form of squamous cell carcinoma (SCC), well differentiated. Slow growth, local aggressiveness, and low capacity to cause metastasis characterize it. It penetrates the deep tissues, forming crypts filled with keratin.^{2,3}

It was first described in 1954 by Aird *et al.*^{1,5} It is more common in men than in women (5:1). Its pathogenesis has not been completely elucidated, but the association with human papillomavirus (HPV), especially subtypes 11 and 16, has been described.^{5,6}

The treatment of choice is surgical excision with margin control, and the patient must be regularly monitored for the risk of recurrences, even when the surgical margins are free.⁶

Case report

Authors:

André Ricardo Adriano¹

Juliano Borges¹

Jordano Luiz da Costa²

¹ Dermatology Institute Professor Rubem David Azulay, Santa Casa de Misericórdia do Rio de Janeiro, Rio de Janeiro (RJ), Brazil.

² Department of Medicine, Universidade Regional de Blumenau, Blumenau (SC), Brazil.

Correspondence:

André Ricardo Adriano

R. Marechal Floriano Peixoto, 222, sala 704

88160-076 Blumenau (SC)

E-mail: andrehrichardo@gmail.com

Received on: 07/01/2020

Approved on: 03/11/2020

Study conducted at the Dermatology Institute Professor Rubem David Azulay, Santa Casa da Misericórdia do Rio de Janeiro, Rio de Janeiro (RJ), Brazil.

Financial support: None.

Conflict of interest: None.

Acknowledgement: We thank Professor Azulay for the encouragement to study, publish, and share knowledge.



CASE REPORT

A 64-year-old woman, working as a sales clerk, sought medical care due to a lesion in the left plantar region two years ago, with a foul odor and associated local pain. The physical examination observed an exophytic lesion with a verrucous surface, 5 cm in diameter, with an infiltrated and ulcerated border (Figures 1 and 2). The image examination, X-ray of the left foot, showed a nodular image with a radiotransparent halo in soft tissues in the plantar region, without bone involvement (Figure 3).

A biopsy was performed based on the suggested hypotheses of VC, keratoacanthoma, common wart, and amelanotic melanoma. The result favored the diagnosis of VC. Excisional

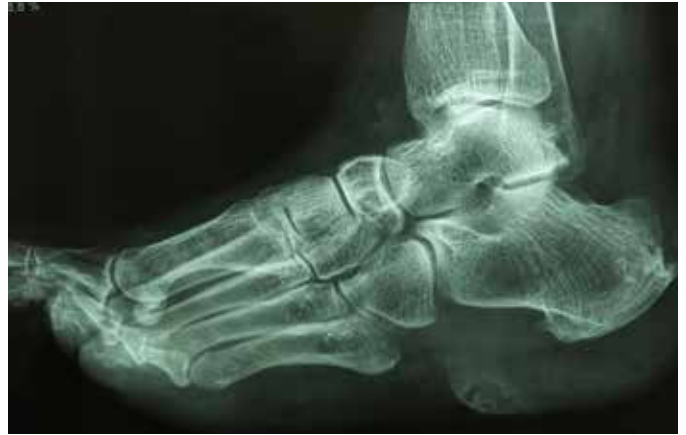

FIGURE 3: X-ray of the left foot
Nodular image with radiotransparent halo in soft tissues in the plantar region

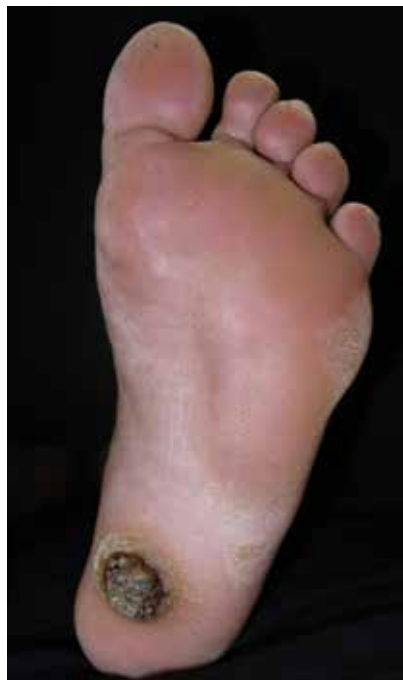

FIGURE 1: Exophytic lesion with verrucous surface, with infiltrated and ulcerated border in the left plantar region

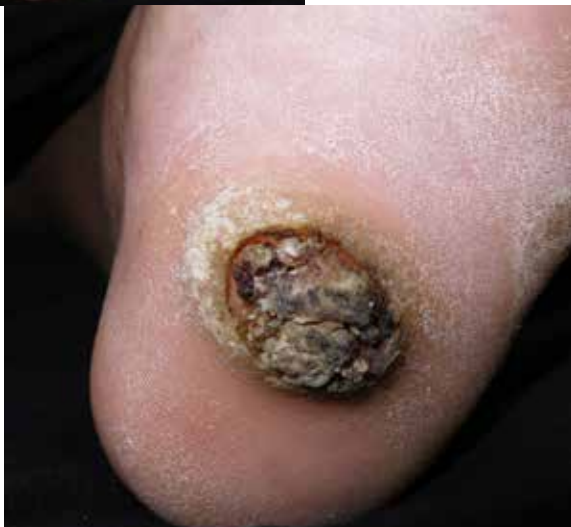

FIGURE 2: Approximate image of the left plantar lesion

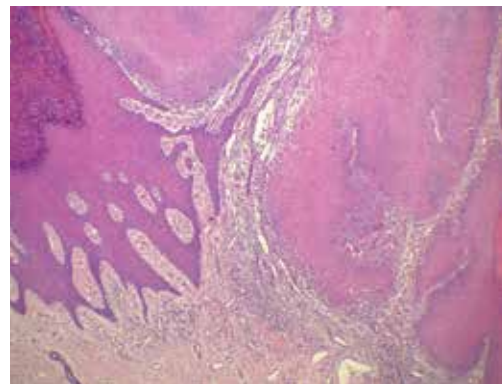


FIGURE 4:
Histopathological examination

Well-differentiated SCC, focally invasive, reaching the middle dermis (Hematoxylin & eosin 100x)

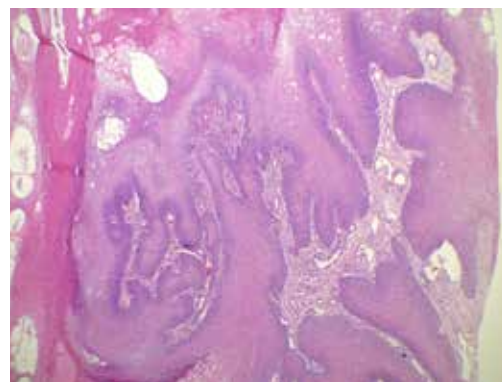


FIGURE 5:
Histopathological examination

Squamous cell proliferation with papillomatosis and dyskeratosis, high degree of cell differentiation, without atypias (Hematoxylin & eosin 100x)

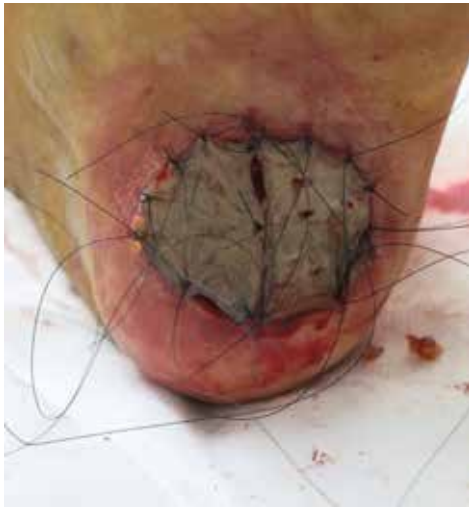

FIGURE 6:
Immediate post
surgery with
abdominal graft

The patient evolved with good graft healing and subsequent return to daily activities. After 1.5 years of follow-up, we observed no lesion recurrence.

DISCUSSION

CC is a VC, a rare and indolent form of SCC. It usually has characteristics of a benign, verrucous tumor, with slow growth, more expansive than invasive evolutionary pattern, good cell differentiation, and low tendency to metastasis.^{2,7}

REFERENCES

1. Feldmann R, Wruhs M, Peinhaupt T, Stella A, Breier F. Carcinoma cuniculatum of the right thenar region with bone involvement and lymph node metastases. *Case Rep Dermatol*. 2017;9:225-30.
2. Arisi M, Zane C, Edu I, Battocchio S, Petrilli G. Carcinoma cuniculatum of the foot invading the bone mimicking a pseudo-epitheliomatous reaction to an acute osteomyelitis. *Dermatol Ther*. 2016;6(1):95-9.
3. McArdle DJT, McArdle JP, Lee F, Mignanelli ED. Rare "inverted" verrucous carcinoma (Carcinoma Cuniculatum) of the sacrogluteal region: case report and literature review. *International Journal Of Surgical Pathology* 2017;25(5):438-42.
4. Kotwal M, Poflee S, Bobhate S. Carcinoma cuniculatum at various anatomical sites. *Ind J Dermatol*. 2005;50(4):216-220.
5. Chavez-Bolanos LJ, Díaz-Gómez CJ. Epitelioma cuniculatum plantar. *Dermatol Peru*. 2014;24(2):103-5.
6. McKay C, McBride P, Muir J. Plantar verrucous carcinoma masquerading as toe web intertigo. *Australas J Dermatol*. 2012;53(2):e20-2.
7. Zanini, M. Carcinoma Verrucoso. *Med Cutan Iber Lat Am*. 2011;39(1):26-9.
8. Kubik MJ, Rhatigan, RM. Carcinoma cuniculatum: not a verrucous carcinoma. *J Cutan Pathol*. 2012;39(12):1083-7.
9. Barreto, JE, Velazquez EP, Ayala E, Torres J, Cubilla AL. Carcinoma cuniculatum: a distinctive variant of penile squamous cell carcinoma: report of 7 cases. *Am J Surg Pathol*. 2007;31:71-5.

AUTHORS 'CONTRIBUTION:

André Ricardo Adriano |  ORCID 0000-0002-2986-959X

Approval of the final version of the manuscript; study design and planning; preparation and writing of the manuscript; data collection, analysis, and interpretation; active participation in research orientation; intellectual participation in propaedeutic and/or therapeutic conduct of studied cases; critical literature review; critical revision of the manuscript.

Jordano Luiz da Costa |  ORCID 0000-0003-1635-6944

Preparation and writing of the manuscript.

Juliano Borges |  ORCID 0000-0001-8291-0806

Critical literature review; critical revision of the manuscript.

Although its most common site is in the plantar region, it can occur in several other areas, such as the flank, legs, face, oral cavity, genital, and palmar region.⁴ It is called CC when it is located in the plantar area; Buschke-Lowenstein tumor, in the anogenital region; and Ackerman's tumor, when in the oral region.^{3,8}

It was first described in 1954 by Aird *et al.*^{1,5} It is more common in men than in women (5:1)⁵ – what makes the report of this case even rarer because it is a female patient. Its pathogenesis is unknown, but the association with human papillomavirus (HPV), especially subtypes 11 and 16, has been described,⁶ as identified in the case above.

Diagnosis is based on dermatological and histopathological examination.^{5,6} This carcinoma should be suspected when the patient has a recurrent lesion on usual therapy. The differential diagnosis is made with common wart and keratoacanthoma.^{6,9}

We observed scaly proliferation with papillomatosis and dyskeratosis in histopathology, a high degree of cell differentiation, without atypia. Keratin pseudocysts can be formed, sometimes with pus, generating a foul odor.³

The treatment of choice is surgical excision with margin control, and the patient must be regularly monitored for the risk of recurrences, even when free margins are obtained.^{6,7} In the case reported, we opted for surgery with a perioperative frozen section to control the margins and perform a graft on the patient's abdomen, with Brown dressing. The patient has been in follow-up for more than two years without recurrence so far. ●