



Surgical & Cosmetic Dermatology

ISSN: 1984-5510

ISSN: 1984-8773

Sociedade Brasileira de Dermatologia

Almeida, Debora Pedroso de; Wegher, Lissa Sabino  
de Matos; Mizumoto, Diogo Hiroshi; Simião, André Luiz  
Fibromatose desmoide extra-abdominal: a importância da  
cirurgia micrográfica de Mohs em um tumor raro e recidivante  
Surgical & Cosmetic Dermatology, vol. 12, no. 1, Supl., 2020, October-December, pp. 114-117  
Sociedade Brasileira de Dermatologia

DOI: <https://doi.org/10.5935/scd1984-8773.20201243602>

Available in: <https://www.redalyc.org/articulo.oa?id=265568336027>

- How to cite
- Complete issue
- More information about this article
- Journal's webpage in redalyc.org



Scientific Information System Redalyc  
Network of Scientific Journals from Latin America and the Caribbean, Spain and  
Portugal

Project academic non-profit, developed under the open access initiative

## Case report

### Authors:

Debora Pedroso de Almeida<sup>1</sup>  
Lissa Sabino de Matos Wegher<sup>1</sup>  
Diogo Hiroshi Mizumoto<sup>1</sup>  
André Luiz Simião<sup>2</sup>

<sup>1</sup> Dermatology Service, Pontifícia Universidade Católica de Campinas Hospital, Campinas (SP), Brazil.

<sup>2</sup> Department of Mohs Micrographic Surgery, Pontifícia Universidade Católica de Campinas, Campinas (SP), Brazil.

### Correspondence:

Debora Pedroso de Almeida  
Av. John Boyd Dunlop, s/n  
Jardim Ipaussurama  
13060-904 Campinas (SP)  
E-mail: deh-pedroso@hotmail.com

Received on: 20/05/2020

Approved on: 15/11/2020

Study conducted at the Dermatology Service of the Pontifícia Universidade Católica de Campinas, Campinas (SP), Brazil.

Financial support: None.

Conflict of interest: None.



# Extra-abdominal desmoid fibromatosis: the importance of Mohs micrographic surgery in a rare and recurrent tumor

*Fibromatose desmoide extra-abdominal: a importância da cirurgia micrográfica de Mohs em um tumor raro e recidivante*

DOI: <https://www.dx.doi.org/10.5935/scd1984-8773.20201243602>

## ABSTRACT

We report the case of a 13-year-old girl with a diagnosis of extra-abdominal desmoid fibromatosis, a neoplasm of benign origin but uncommon in the soft tissues. This study aims to expose the rarity of the tumor and its challenging therapeutic approach due to its high frequent local recurrence rates. For the treatment, Mohs micrographic surgery was performed in two stages to obtain a free margin.

**Keywords:** Fibromatosis, Aggressive; Mohs Surgery; Neoplasms

## RESUMO

Apresenta-se caso de paciente do gênero feminino, 13 anos, com diagnóstico de fibromatose desmoide extra-abdominal, neoplasia dos tecidos moles, de origem benigna, porém incomum. Nosso objetivo é expor este relato pela raridade do tumor bem como por sua desafiadora abordagem terapêutica e pelas altas taxas de recidiva local frequentes nesses tumores. Para o tratamento, realizou-se cirurgia micrográfica de Mohs em duas fases para obtenção de margens livres.

**Palavras-chave:** Cirurgia de Mohs; Fibromatose Agressiva; Neoplasias

## INTRODUCTION

Extra-abdominal desmoid fibromatosis is a rare, benign neoplasm, originating in fibroblastic cells and growing in a variable pattern. It can occur in almost any part of the body. Despite not presenting malignant behavior, such as metastases, the desmoid tumor has a high capacity for growth and local invasion. With few cases described in the literature, its surgical treatment is practically a consensus.<sup>1,2,3</sup> The Mohs micrographic surgery (MMS) approach considerably reduces the chances of frequent recurrence of these tumors, estimated at approximately 11% to 64%, depending on the treatment used.<sup>4</sup> We report a pediatric patient's case, with this neoplasm located on the lower lip, submitted to excision by micrographic surgery and followed for two years, without recurrence.

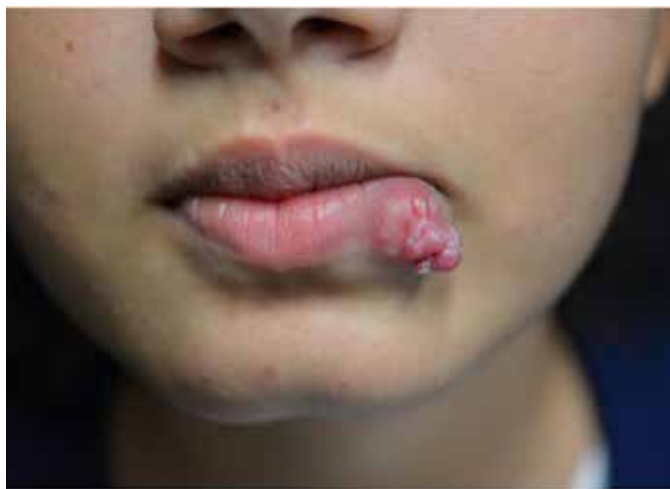## CASE REPORT

A 13-year-old girl presented a history of a lesion on the lower lip beginning seven months ago, with slow and progressive growth. She denied any symptoms or previous trauma at the site. The patient had a personal history of juvenile idiopathic arthritis (JIA), and she was using methotrexate, folic acid, and etanercept. The dermatological examination showed an erythematous-violaceous tumor, with a nipple-like surface and a well-defined fibroelastic consistency of approximately 2.5 cm on the lower lip, on the left. An excisional biopsy was performed, revealing fibromyxoid fusocellular mesenchymal proliferation, with an associated inflammatory cell component, on anatomopathological examination. The immunohistochemical panel showed diffuse and intense positivity of beta-catenin and vimentin and negative ALK-1. These findings pointed to the diagnosis of extra-abdominal desmoid fibromatosis.<sup>5</sup>

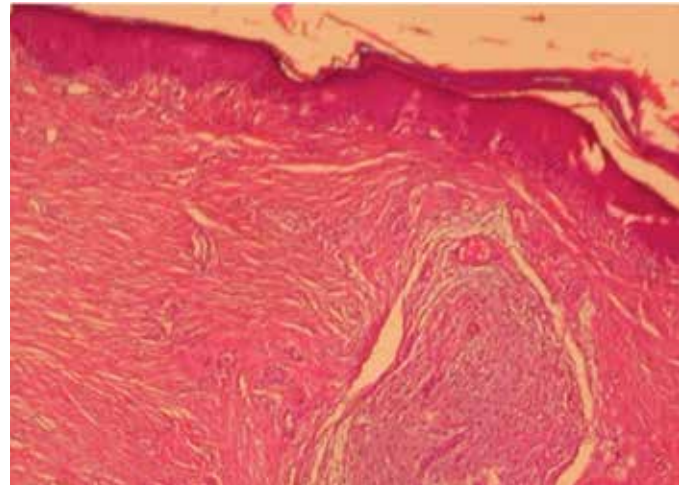
We opted for the excision of the lesion by Mohs micrographic surgery, revealing compromised margins in the first stage of the procedure and free margins after the surgical defect's enlargement. The patient was followed every three months in the first year and every six months in the second, with no clinical sign of recurrence of the lesion.

## DISCUSSION

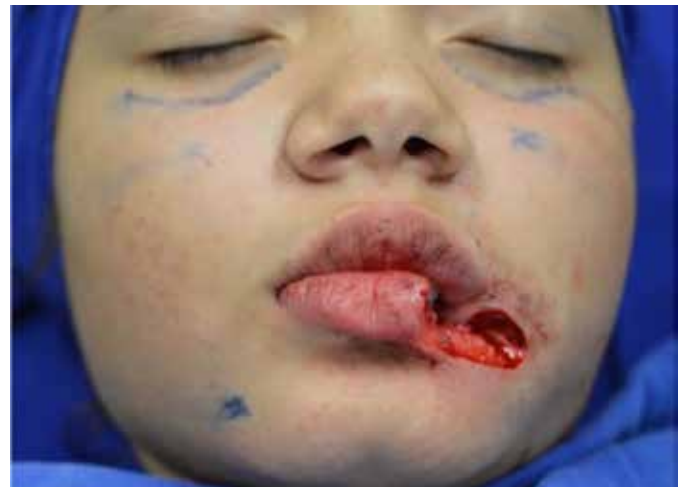The desmoid tumor or desmoid fibromatosis consists of fibroblastic proliferation, originating in the soft tissues, with benign behavior. McFarlane first described it in 1832, and Muller coined the term desmoid five years later, based on the myofibroblastic cells that constitute these tumors. It has an estimated frequency of 3% of all soft tissue tumors. It most commonly affects individuals between 15 and 60 years old, being rare in the pediatric age group and after the fourth decade, with a slight preference for women. Its most frequent form of presentation is intra-abdominal, accounting for about 70% of cases.<sup>6,7,8</sup>



**FIGURE 1:** Nodosidade eritemato-violácea, de superfície mamilonada e consistência fibroelástica



**FIGURE 2:** Proliferação mesenguimal fusocelular fibromixoide

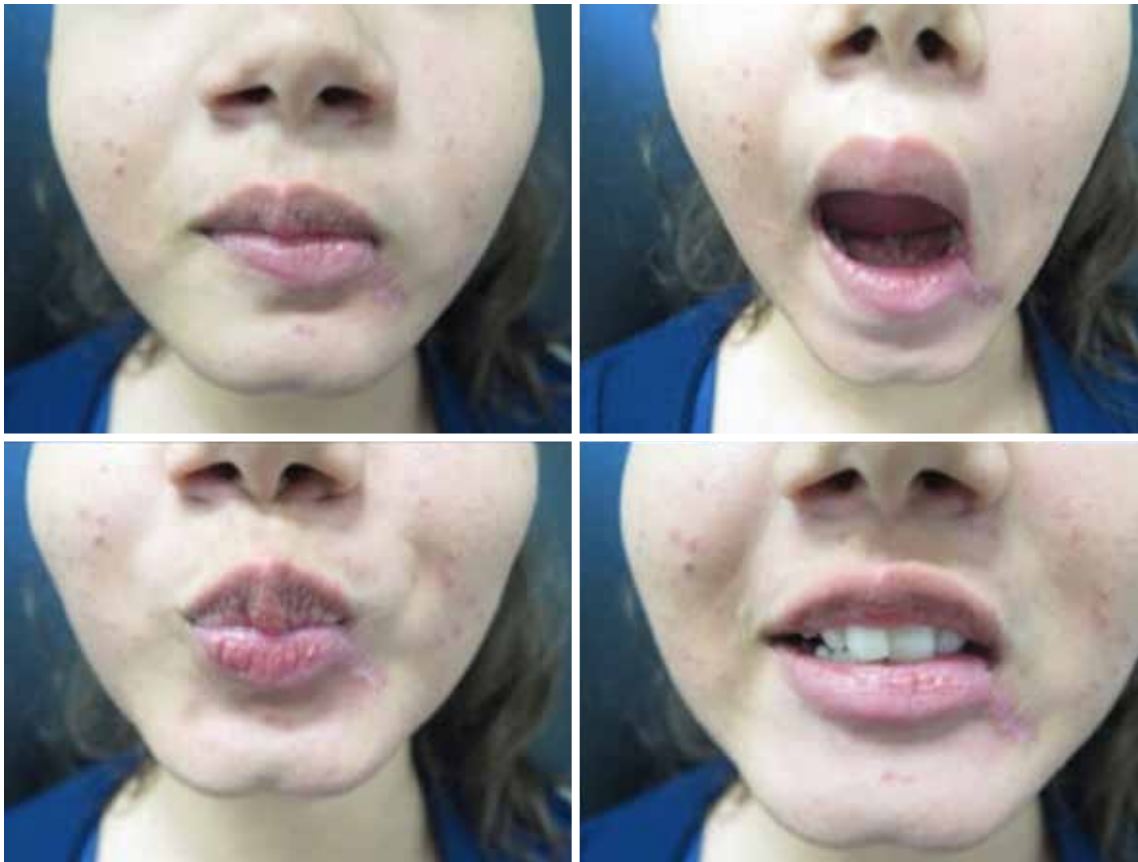

**FIGURE 3:** Defeito cirúrgico após excisão com controle de margens operatórias. Realizada sutura com aproximação primária das bordas aproximação primária

The vast majority of cases, around 90%, are sporadic. Somatic mutations of the beta-catenin protein, which makes up the CTNNB1 gene, may boost this tumor's development.<sup>9</sup> In addition to the genetic characteristics, other endocrine and physical factors, such as trauma, play an essential role in the disease's etiology.

In its rare, extra-abdominal form, its appearance in the extremities' soft tissues is more frequently observed, with half of the cases originating in the limbs, 43% in the chest, and only 7% in the head and neck region. However, any anatomical area is subject to its appearance.<sup>10,11,12</sup> Our report stands out for its atypical presentation, both by the age group and by its very unusual location.

These tumors are characterized by presenting different degrees of aggressiveness with unpredictable biological behavior. Their natural history ranges from indolent and self-limited lesions to infiltrative lesions and with rapid local proliferation. The symptomatology depends on the presentation site and adjacent



**FIGURE 4:**  
Paciente avaliada após  
1 ano do procedimento  
com bom resultado  
funcional

structures. The majority is asymptomatic; however, due to its significant regional growth, it can compress or compromise other structures, organs, or the functionality of the affected region.<sup>13,14</sup>

The diagnosis is made by anatomopathological examination that shows bundles of spindle cells, elongated, in the middle of stromal collagen, with variable vascularization. The cells are usually small, with clear cytoplasm and pale nuclei, showing no atypia or mitoses. Immunohistochemistry is positive for muscle cell markers, such as vimentin, desmin, and smooth muscle actin. In electron microscopy, spindle cells look like myofibroblasts.

The most common cases, intra-abdominal, usually require imaging methods to complement the diagnosis.<sup>7</sup>

According to most authors, the ideal treatment has not yet been established, although surgery is the first therapeutic option. The main challenge is the fact that, despite being histologically benign, they have high recurrence rates. Most of the cases described in the literature consist of intra-abdominal tumors where conservative treatment can be considered. However, there are few publications of lesions outside the abdominal cavity and

in pediatric patients. Nevertheless, when conventional deciding for local resection, it must contain a wide margin to avoid the risk of incomplete excision.<sup>6</sup> Other therapeutic options include chemotherapy, hormone therapy, and radiation therapy.

In the case reported, the surgical approach, especially the treatment with MMS, was strictly necessary, considering the patient's age, the unfavorable anatomical location in a prime area, and the relevant percentage of these tumors' recurrence. Two surgical stages were necessary to obtain the free margins.

## CONCLUSION

Health professionals must remember the desmoid tumor as a differential diagnosis of soft tissue tumors, and anatomopathological examination is essential for its diagnostic confirmation. The effectiveness of MMS is already widespread and should be indicated for the removal of tumors with potential for recurrence and in risk areas where tissue preservation is essential, as in our case. This approach was fundamental in healing, ensuring margin control and excellent aesthetic and functional results for the patient. ●

## REFERENCES

1. Meazza C, Bisogno G, Gronchi A, Fiore M, Cecchetto G, Alaggio R, et al. Aggressive fibromatosis in children and adolescents: the Italian experience. *Cancer* 2010;116(1):233-40.
2. Reitamo JJ, Scheinin TM, Hayry P. The desmoid syndrome: new aspects in the cause, pathogenesis and treatment of the desmoids tumor. *Am J Surg*. 1986;151(2):230-7.
3. van Broekhoven DLM, Verhoef C, Elias SG, Witkamp AJ, van Gorp JMHH, van Geel BAN, et al. Local recurrence after surgery for primary extra-abdominal desmoid-type fibromatosis. *Br J Surg* 2013;100(9):1214-9.
4. Mueller C, Croner R., Klein P, Grützmann R, Vassos, N. Primary and recurrent sporadic desmoids: Prognostic factors influencing recurrence-free survival after complete gross resection. *Int J Surg*. 2016;31:63-70.
5. Shen C, Wang C, Yan J, He T, Zhou X, Ma W, Zhang B. Clinicopathological characteristics, treatment, and survival outcomes of retroperitoneal desmoid-type fibromatosis. *Medicine (Baltimore)*. 2019;98(47):e18081.
6. Teixeira LEM, Arantes EC, Villela RF, Soares CBG, Costa RBC, Andrade MAP, et al. Extra abdominal desmoid tumor: local recurrence and treatment options. *Acta Ortop Bras*. 2016;24(3):147-50.
7. Valejo FAM, Tiezzi DM, Nai GA. Tumor desmoide abdômino-pélvico. *Rev Bras Ginecol Obstet*. 2009;31(1):35-40.
8. Reitamo JJ, Hayry P, Nykyri E, Saxén E. The desmoid tumour. I. Incidence, sex- age- and anatomical distribution in the Finnish population. *Am J Clin Pathol*. 1982;77(6):665-73.
9. Mullen JT, DeLaney TF, Rosenberg AE, Le L, Iafrate AJ, Kobayashi W, et al. b-Catenin mutation status and outcomes in sporadic desmoid tumors. *Oncologist* 2013;18(9):1043-9.
10. Rock MG, Pritchard DJ, Reiman HM, Soule EH, Brewster RC. Extra-abdominal desmoid tumors. *J Bone Joint Surg Am*. 1984;66(9):1369-74.
11. Siva AF, Alves JCRR, Portugal EH, Fonseca RPL, Almeida ACM, Pereira NA, et al. Fibromatose agressiva (tumor desmoide) associada ao implante mamário: revisão da literatura e apresentação de três novos casos. *Rev Bras Cir Plást*. 2017;32(3):361-71.
12. Merchant NB, Lewis JL, Woodruff JM, Leung DH, Brennan MF. Extremity and trunk desmoid tumors. A multifactorial analysis of outcome. *Cancer*. 1999;86 (10):2045-52.
13. Shields CJ, Winter DC, Kirwan WO, Redmond HP. Desmoid tumours. *Eur J Surg Oncol*. 2001;27(8):701-6.
14. Fallen T, Wilson M, Morlan B, Lindor NM. Desmoid tumors e a characterization of patients seen at Mayo Clinic 1976-1999. *Fam Cancer*. 2006;5(2):191-4


## AUTHORS 'CONTRIBUTION:

**Debora Pedroso de Almeida** |  ORCID 0000-0001-6543-5898

Study design and planning; preparation and writing of the manuscript; data collection, analysis, and interpretation; critical literature review.

**André Luiz Simião** |  ORCID 0000-0002-0246-2001

Approval of the final version of the manuscript; critical revision of the manuscript.

**Lissa Sabino de Matos Wegher** |  ORCID 0000-0002-3247-3393

Study design and planning; critical revision of the manuscript.

**Diogo Hiroshi Mizumoto** |  ORCID 0000-0002-4979-3959

Study design and planning; critical literature review.