



Surgical & Cosmetic Dermatology

ISSN: 1984-5510

ISSN: 1984-8773

Sociedade Brasileira de Dermatologia

Barros, Jefferson Alfredo de; Barros, Juliano Cesar de;
Narahara, Juliana Lika; Citrin, Anelise Damiani da Silva
Enxerto dermoepidérmico obtido por remoção da pápula formada pós-
enxertia com punch em vitiligo: melhora do padrão em paralelepípedo
Surgical & Cosmetic Dermatology, vol. 12, no. 1, Supl., 2020, October-December, pp. 118-120
Sociedade Brasileira de Dermatologia

DOI: <https://doi.org/10.5935/scd1984-8773.20201243626>

Available in: <https://www.redalyc.org/articulo.oa?id=265568336028>

- How to cite
- Complete issue
- More information about this article
- Journal's webpage in redalyc.org

redalyc.org

Scientific Information System Redalyc

Network of Scientific Journals from Latin America and the Caribbean, Spain and Portugal

Project academic non-profit, developed under the open access initiative

Case report

Authors:

Jefferson Alfredo de Barros¹
 Juliano Cesar de Barros¹
 Juliana Lika Narahara¹
 Anelise Damiani da Silva Citrin¹

¹ Department of Dermatology,
 Faculdade de Medicina do ABC,
 Santo André (SP), Brazil.

Correspondence:

Anelise Damiani da Silva Citrin
 Avenida Príncipe de Gales, 821
 Vila Príncipe de Gales
 09060-050 Santo André (SP)
 E-mail: anedamiani@gmail.com

Received on: 15/06/2020

Approved on: 15/11/2020

Study conducted at the Faculdade de
 Medicina do ABC, Santo André (SP),
 Brazil.

Financial support: None.

Conflict of interest: None.



Derμοepidermal grafting obtained by shave excision of papule formed post punch grafting in vitiligo: improvement of the cobblestone pattern

Enxerto derμοepidérmico obtido por remoção da pápula formada pós-enxertia com punch em vitiligo: melhora do padrão em paralelepípedo

DOI: <https://www.doi.org/10.5935/scd1984-8773.20201243626>

ABSTRACT

Vitiligo is an acquired dyschromia that affects 0,1–3% of the world population and can cause significant psychosocial distress in patients. Surgical management became essential in the last years. Mini-punch grafting is one of the cheapest and most straightforward approaches to all surgical treatments available. A limitation of this technique is the possibility of cobblestone-like repigmentation. We describe a new technique with a derμοepidermal grafting obtained by shave excision of papule formed post punch grafting in vitiligo. It could improve the cobblestone pattern in the donor site and the repigmentation in both donor and recipient areas.

Keywords: Dermatology; Hypopigmentation; Vitiligo

RESUMO

O vitiligo é uma discromia adquirida que afeta 0,1-3% da população mundial e pode causar sofrimento psicossocial significativo nos pacientes. O manejo cirúrgico tornou-se importante nos últimos anos. O minienxerto é uma das abordagens mais baratas e fáceis entre todos os tratamentos cirúrgicos disponíveis. Uma limitação desta técnica é a possibilidade de repigmentação em forma de paralelepípedos. Descreve-se uma nova técnica com enxerto derμοepidérmico obtido por remoção da pápula formada pós-enxertia com punches no vitiligo. Essa técnica pode melhorar o padrão em paralelepípedos no local doador e a repigmentação em ambas as áreas, doadora e receptora.

Palavras-chave: Dermatologia; Hipopigmentação; Vitiligo

INTRODUCTION

Vitiligo is an acquired depigmenting disease of polygenic inheritance, which affects 0.1–3% of the world population.^{1,2} It can cause significant psychosocial distress in patients. Among the treatments, mini punch grafting (MPG) proved to be one of the cheapest and easiest surgical approaches. A limitation of this technique is the possibility of cobblestone-like effect repigmentation.² We describe a new technique that can improve the appearance of repigmentation.

CASE REPORT

A 69-year-old woman with Fitzpatrick skin phototype V presented achromatic macules in the left frontotemporal and cervical region and upper limbs for 15 years. She underwent topical treatment with phototherapy with ultraviolet B and medium-potency corticosteroids, with improvement only in the lesions on the limbs. The condition remained stable for 12 years, when an autologous skin graft was performed, under local anesthesia, using the left cervical region as the donor site. We used a 2 mm punch at three points and implanted the material in areas of the same size and depth in the left frontotemporal region at 0.5 cm intervals. After one year, due to the presence of papules (cobblestone-like repigmentation) at the graft site, we decided to perform a new surgical intervention. The papules were incised close to the skin, and the domes were implanted at points in the left frontotemporal region (Figure 1). There was repigmentation of the recipient area in six months and aesthetic improvement of the donor site (Figure 2).

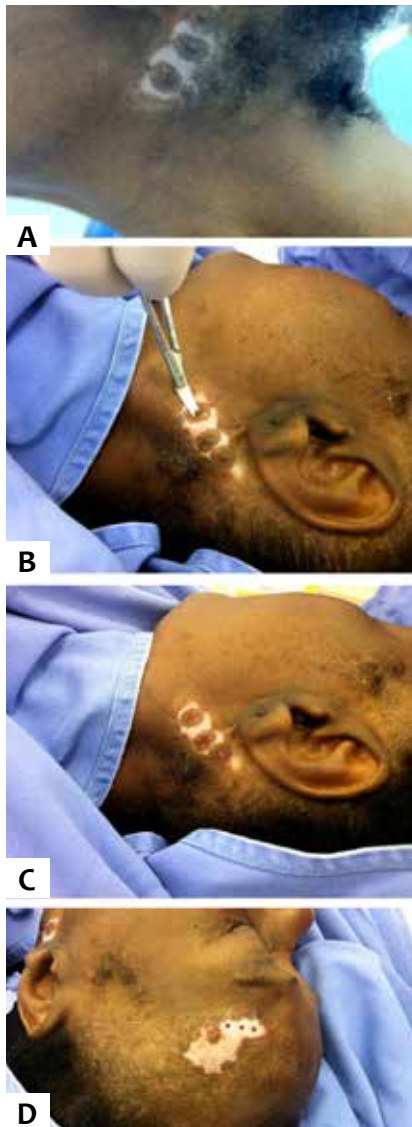


FIGURE 1:
Dermo-epidermal skin graft

A) Left cervical region: healing with a cobblestone-like effect;
B) Shaving of dermo-epidermal area;
C) Donor site after shaving;
D) Recipient site: left frontotemporal

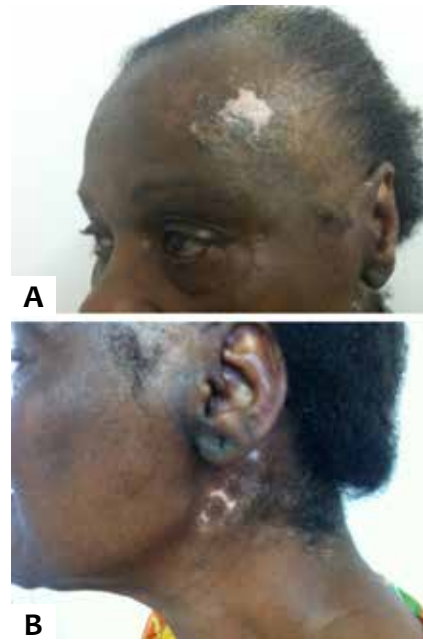

FIGURE 2:
Result after six months

Satisfactory result after six months:
A) Donor site;
B) Recipient site

DISCUSSION

Vitiligo is a common acquired depigmentation disorder. The literature has proposed several theories about this disease's etiopathogenic mechanisms, including autoimmune, oxidative stress, neural, and viral theories.^{1,2} Behl and Batia first described the dermo-epidermal graft in 1973.³ The surgery aims to introduce melanocytes into depigmented vitiligo lesions. The mini graft proved to have the best applicability among the surgical techniques due to its simplicity, without the need for specialized instruments, and at low cost. Repigmentation rates are usually higher than 65% of cases.^{1,2,3,4} An important limitation of this technique is the possibility of cobblestone-like effect in repigmentation, present in about 30% of cases.² To avoid this effect, it is recommended to use a punch of up to 1.5 mm and a pigmented donor site similar in thickness to the recipient site's location. Some studies suggest benefits in making a recipient site 1 mm deeper and 0.5 mm narrower than grafts from donor sites.^{1,5}

As the presence of the cobblestone-like effect after the graft is not uncommon, this study proposed a new technique with the dermo-epidermal graft obtained by removing the papule formed post-mini punch grafting. The aesthetic result and the repigmentation were satisfactory in the donor and recipient sites. Larger samples are needed to support this technique. ●

REFERENCES

1. Patel NS, Paghdal KV, Cohen GF. Advanced treatment modalities for vitiligo. *Dermatol Surg*. 2012;38(3):381-91.
2. Falabella R, Barona MI. Update on skin repigmentation therapies in vitiligo. *Pigment Cell Melanoma Res*. 2009;22(1):42-65.
3. Behl PN, Bhatia RK. Treatment of vitiligo with autologous thin Thiersch's grafts. *Int J Dermatol*. 1973;12(5):329-31.
4. Mulekar SV, Isedeh P. Surgical interventions for vitiligo: an evidence-based review. *Br J Dermatol*. 2013;169(Suppl 3):57-66.
5. Komen L, Vrijman C, Prinsen CA, van der Veen JP, Luiten RM, Wolkerstorfer A. Optimising size and depth of punch grafts in autologous transplantation of vitiligo and piebaldism: a randomised controlled trial. *J Dermatolog Treat*. 2017;28(1):86-91.

AUTHORS 'CONTRIBUTION:

Jefferson Alfredo de Barros |  ORCID 0000-0002-7553-2699

Approval of the final version of the manuscript; active participation in research orientation; intellectual participation in propaedeutic and/or therapeutic conduct of studied cases; critical revision of the manuscript.

Juliano Cesar de Barros |  ORCID 0000-0003-1494-7118

Approval of the final version of the manuscript; study design and planning; active participation in research orientation; intellectual participation in propaedeutic and/or therapeutic conduct of studied cases; critical revision of the manuscript.

Juliana Lika Narahara |  ORCID 0000-0002-6025-7823

Approval of the final version of the manuscript; study design and planning; preparation and writing of the manuscript.

Anelise Damiani da Silva Citrin |  ORCID 0000-0002-2986-6188

Approval of the final version of the manuscript; preparation and writing of the manuscript; critical literature review; critical revision of the manuscript.