



Surgical & Cosmetic Dermatology

ISSN: 1984-8773

Sociedade Brasileira de Dermatologia

Bloch, Leila David; Matsumoto, Cindy Tiemi  
Transplante capilar em transgêneros femininos: estudo de casos  
Surgical & Cosmetic Dermatology, vol. 16, e20240254, 2024  
Sociedade Brasileira de Dermatologia

DOI: <https://doi.org/10.5935/scd1984-8773.2024160254>

Available in: <https://www.redalyc.org/articulo.oa?id=265577623002>

- How to cite
- Complete issue
- More information about this article
- Journal's webpage in [redalyc.org](https://www.redalyc.org)

redalyc.org

Scientific Information System Redalyc  
Network of Scientific Journals from Latin America and the Caribbean, Spain and  
Portugal

Project academic non-profit, developed under the open access initiative

## Hair transplantation in transgender women: case report

*Transplante capilar em transgêneros femininos: estudo de casos*

DOI: <http://www.dx.doi.org/10.5935/scd1984-8773.2024160254>

### ABSTRACT

Hair transplantation is an option for anyone with Androgenetic Alopecia, including transgender patients who want to align their appearance with their gender identity. Thus, hair transplantation can help transform appearance and boost self-esteem, especially if hair loss is a source of gender dysphoria. We report two cases of hair transplantation in transgender patients with good results, using the Follicular Unit Extraction and Follicular Unit Transplantation techniques. Due to the scarcity of specific articles about hair transplantation in this population, we report these cases for a better understanding of the specific needs of these patients.

**Keywords:** Hair; Transplants; Transgender People; Gender Dysphoria; Gender Identity; Feminization.

### RESUMO

O transplante capilar é uma opção para aqueles com alopecia androgenética, incluindo pacientes transgênero que desejam alinhar sua aparência com sua identidade de gênero. Assim, o transplante capilar pode ajudar a transformar a aparência e aumentar a autoestima, especialmente se a perda capilar é uma fonte de disforia de gênero. Relatamos dois casos de transplante capilar em pacientes transgênero, com resultados satisfatórios, usando as técnicas Follicular Unit Extraction e Follicular Unit Transplantation. Como há escassez de artigos específicos sobre transplante capilar nesta população, relatamos estes casos para maior compreensão das necessidades específicas destes pacientes.

**Palavras-chave:** Cabelo; Transplante; Pessoas Transgênero; Disforia de Gênero; Identidade de Gênero; Feminização.

## Case report

### Authors:

Leila David Bloch<sup>1</sup>

Cindy Tiemi Matsumoto<sup>1</sup>

<sup>1</sup> Bloch Clinic, São Paulo (SP), Brazil.

### Correspondence:

Leila David Bloch

Email: [leilabloch@gmail.com](mailto:leilabloch@gmail.com) /

[enfermagemclinicabloch@gmail.com](mailto:enfermagemclinicabloch@gmail.com)

**Financial support:** None.

**Conflict of interest:** None.

**Submitted on:** 24/04/2023

**Approved on:** 07/01/2024

### How to cite this article:

Bloch LD, Matsumoto CT. Hair transplantation in transgender women: case report. Surg Cosmet Dermatol. 2024;16:e20240254.

## INTRODUCTION

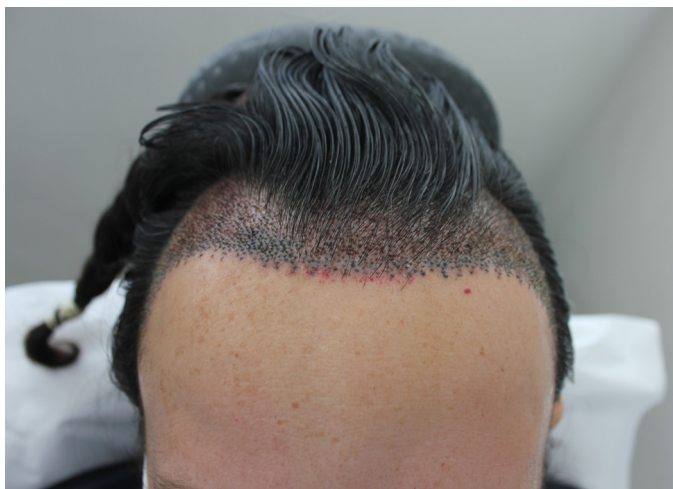The term transgender refers to a person who does not identify with the biological sex assigned at birth. The transgender population corresponds to 0.69% of the Brazilian population.<sup>1</sup> To adapt to the gender with which they identify, some undergo treatments that include surgeries, hormonal therapies, and dermatological procedures. During this transition to alleviate gender dysphoria, multidisciplinary monitoring with psychologists, psychiatrists, endocrinologists, dermatologists, and plastic surgeons, among others, is critical. Facial feminization surgery is an example of a procedure to transition from male to female, as some facial features are more typical of a woman's face while others are of a man's face. One of these characteristics is the hair implantation line, which usually has an oval pattern in women and an M-shaped pattern in men.<sup>2</sup> Thus, hair transplantation is an option for patients with androgenetic alopecia or those who want a reduction in the forehead and /or the bitemporal recesses for a more feminine appearance. We report cases of hair transplantation in transgender patients with satisfactory results.

## CASE REPORT

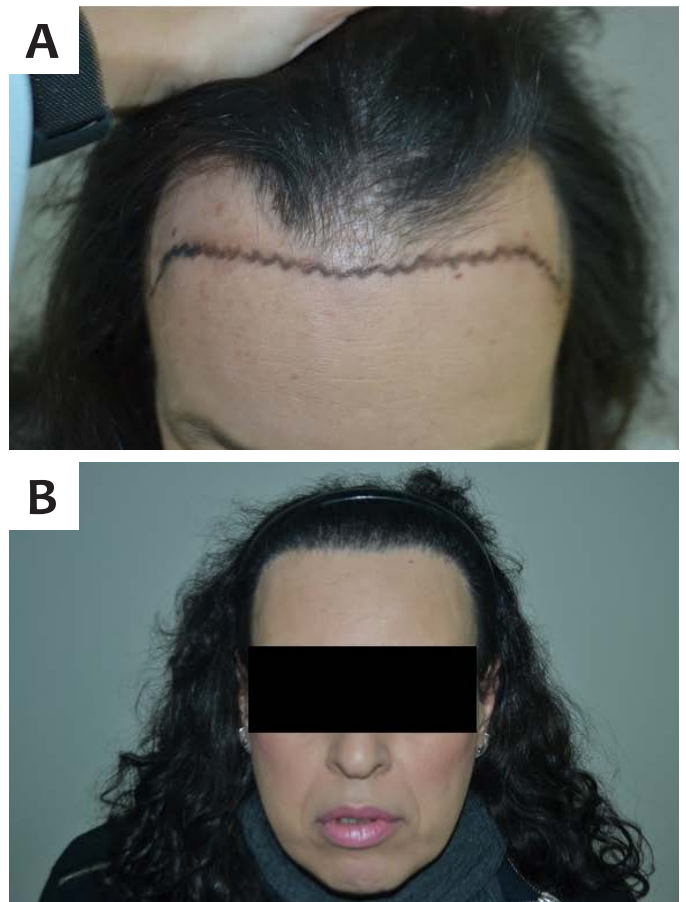A 45-year-old transgender woman came to our Service with a history of androgenetic alopecia for five years and gender-affirming hormone therapy for two and a half years, in maintenance for a year and a half with estradiol valerate 6 mg, aldactone 200 mg and blister of estradiol 6 mg and 1.2 mg. She denied previous hair treatments other than topical minoxidil 5% for a year. The patient had anxiety and was taking desvenlafaxine 50 mg, and did not intend to perform other facial surgical procedures. She presented a hairline 7 cm distant from the diagonal to the angle and 7 cm from the anterior line to the glabella. She started clinical treatment with finasteride 2.5 mg/day, minoxidil 2 mg/day, and topical minoxidil 5%. After three months and having verified the stability of the condition and adherence to therapy without adverse events, we performed hair transplan-

tion using the Follicular Unit Transplantation (FUT) technique to reduce the previous line, with 1,551 follicular units, totaling 2,896 hairs, with follow-up on the first day of postoperatively (Figure 1), one month, three months, five months, ten months, and one year after surgery (Figure 2).

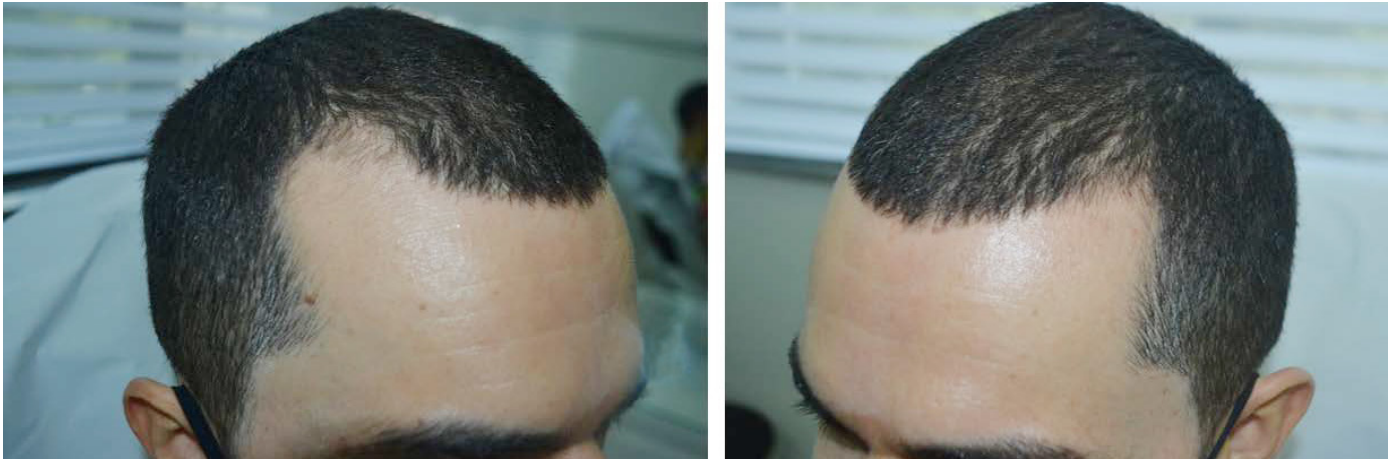A 37-year-old transgender woman with androgenetic alopecia, who already used dutasteride 0.5 mg and minoxidil lotion for seven months and had no intention of gender-affirming hormonal therapy, sought our Service. She presented an excellent donor area with follicular units with three hairs, good density, and a distance from the recess to the mid-pupillary line of 6.5 cm (Figure 3). We performed hair transplantation using the Follicular Unit Extraction (FUE) technique in the bitemporal region, maintaining the previous line. The design was 5 cm of bitemporal recess x 8.5 cm of anterior line x 8.5 cm from the glabella to the anterior line, and 1,750 follicular units were used, totaling 3,764 hairs (Figure 4). Follow-up took place on the first postoperative day, 15 days, three months, and six months after surgery (Figure 5) with excellent results.



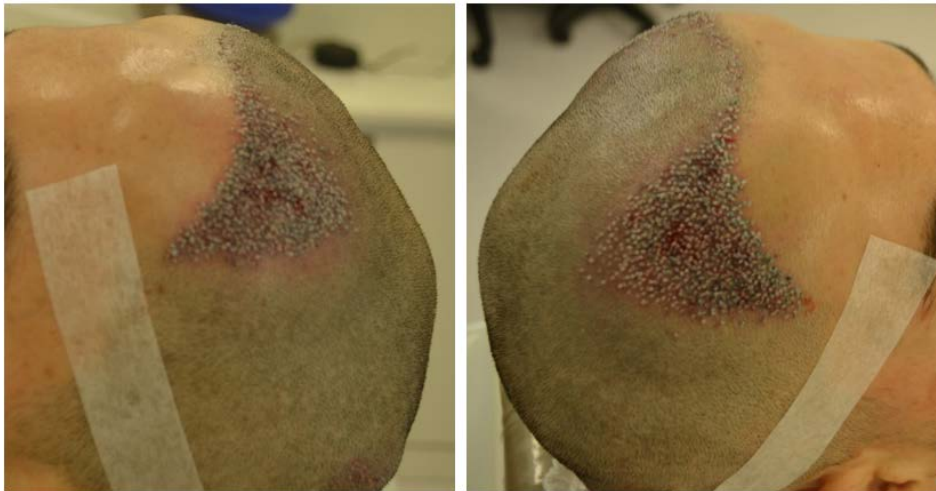
**FIGURE 1:** First day after hair transplantation using the Follicular Unit Transplantation (FUT) technique



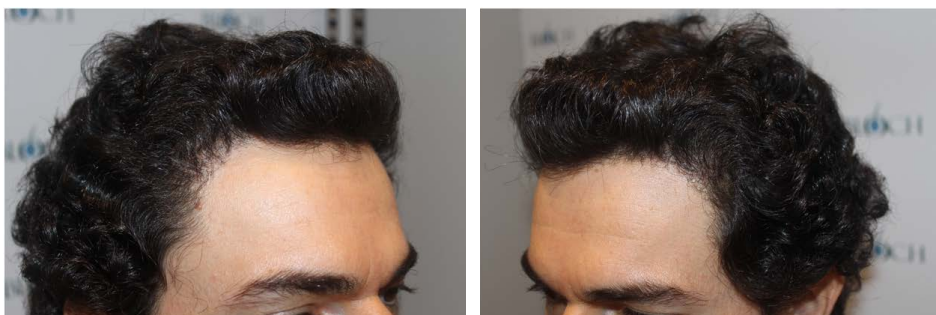**FIGURE 2:** A - Before transplantation; B - Final result after one year of hair transplant



**FIGURE 3:** Before hair transplant



**FIGURE 4:** Immediate postoperative period of hair transplantation with the Follicular Unit Extraction (FUE) technique



**FIGURE 5:** Result after six months of hair transplant

## DISCUSSION

While many transgender people seek medical treatments, such as hormone therapy or plastic surgery, to feel more comfortable in their skin, others are reluctant due to fear, financial reasons, or even bad experiences with prior medical care. Nevertheless, transgender people often undergo hormonal therapy to

improve their physical appearance and alleviate gender dysphoria due to the difficulty in both personal and social acceptance, which can lead to social stigma and isolation.

Hormone therapy involves estrogens and/or antiandrogens, such as spironolactone. The role of estrogens in the hair



cycle is still uncertain despite reducing androgen levels.<sup>3</sup> There is evidence of a pro-hair growth effect with an increase in the anagen phase and hair density in pre-menopausal and pregnant women.<sup>4</sup> However, not everyone wants to take gender-affirming hormone therapy.

The recessed anterior hairline design is stigmatized for transgender women, as people see the presence of bitemporal retractions or a more posterior frontal line as a more masculine facial pattern. For those diagnosed with androgenetic alopecia, treatment includes minoxidil antiandrogens and hair transplantation and is influenced by gender-affirming hormonal therapy.<sup>5</sup> There are reports of significant improvement in the pattern of androgenetic alopecia in transgender women with hormonal therapy with estrogen and spironolactone.<sup>6</sup> However, studies also show an inhibitory effect on hair growth.<sup>7</sup> Hair transplantation is an option for those who want a more feminine hair implantation line.

Transgender women seek hair transplantation due to the feminization of the face: the hairline is lower and rounded on the forehead, compared to the M or undefined shape in men,

and because it is a less aggressive option than facial feminization surgery. *Capitán et al.* recommend hair transplantation in patients with type II hair implantation lines, i.e., with bitemporal recess and good hair density and without active androgenetic alopecia. Type III patients have an indication for the hairline lowering procedure (reduction of the anterior line), which removes a strip of skin from the forehead, with an advancement of 1–2 cm.<sup>2</sup>

In patients with short hair, the FUE technique is selected, while in long hair with good skin elasticity, the FUT technique is chosen, or even FUE without shaving the hair or FUE in windows. The doctor in agreement with the patient decides on the technique. Although hair transplantation is a popular option for patients suffering from androgenetic alopecia, few studies specifically address the results and effectiveness of the procedure in transgender patients as well as the right timing for surgery, i.e., before or after other procedures such as facial feminization and hormone therapy. More studies are needed to identify improvements in the multidisciplinary and multidisciplinary approach to transgender patients, as well as consider the unique needs and characteristics of these patients. ●

#### REFERENCES:

1. Spizzirri G, Eufrásio R, Lima MCP, Nunes HRC, Kreukels BPC, Steensma TD, et al. Proportion of people identified as transgender and non-binary gender in Brazil. *Sci Rep.* 2021;11(1):2240.
2. Capitán L, Simon D, Meyer T, Alcaide A, Wells A, Bailón C, et al. Facial feminization surgery: simultaneous hair transplant during forehead reconstruction. *Plast Reconstr Surg.* 2017;139(3):573-584.
3. Dittrich R, Binder H, Cupisti S, Hoffmann I, Beckmann MW, Mueller A. Endocrine treatment of male-to-female transsexuals using gonadotropin-releasing hormone agonist. *Exp Clin Endocrinol Diabetes.* 2005;113(10):586-92.
4. Lynfield YL. Effect of pregnancy on the human hair cycle. *J Invest Dermatol.* 1960;35:323-7.
5. Motosko CC, Tosti A. Dermatologic care of hair in transgender patients: a systematic review of literature. *Dermatol Ther (Heidelb).* 2021;11(5):1457-1468.
6. Manson JE, Hsia J, Johnson KC, Rossouw JE, Assaf AR, Lasser NL, et al. Women's health initiative investigators. Estrogen plus progestin and the risk of Coronary Heart Disease. *N Engl J Med.* 2003;349(6):523-34.
7. Yip L, Rufaut N, Sinclair R. Role of genetics and sex steroid hormones in male androgenetic alopecia and female pattern hair loss: an update of what we now know. *Australas J Dermatol.* 2011;52(2):81-8.
8. Bared A, Epstein JS. Hair transplantation techniques for the transgender patient. *Facial Plast Surg Clin North Am.* 2019;27(2):227-232.

#### AUTHORS' CONTRIBUTION:

**Leila David Bloch**  ORCID 0000-0001-9596-9583

Approval of the final version of the manuscript; study design and planning; critical review of the manuscript.

**Cindy Tiemi Matsumoto**  ORCID 0000-0002-6562-1989

Preparation and writing of the manuscript; critical review of the literature.