

Endoscopic Retrieval of Migrated Coils in the Biliary Tract: Case Reports and Literature Review

Ileana Rocío Bautista-Parada,^{1*}  Ángel Rojas-Espinosa.¹ 

OPEN ACCESS

Citation:

Bautista-Parada IR, Rojas-Espinosa A. Endoscopic Retrieval of Migrated Coils in the Biliary Tract: Case Reports and Literature Review. *Revista. colomb. Gastroenterol.* 2025;40(1):84-87. <https://doi.org/10.22516/25007440.1193>

¹ Specialist in General Surgery, clinical-surgical gastroenterologist. Bucaramanga, Colombia.

*Correspondence: Ileana Rocío Bautista-Parada. ibautista4@hotmail.com

Received: 12/03/2024

Accepted: 21/10/2024



Abstract

Embolization is a widely used procedure for managing both vascular and nonvascular conditions. However, the potential migration of coils into the biliary tract has been documented in medical literature, with clinical presentations often resembling biliary obstruction caused by choledocholithiasis. This report discusses two cases of coil migration into the biliary tract following arterial embolization and their subsequent endoscopic removal. Endoscopic management is the preferred approach; however, the technique used depends on the patient's clinical condition and anatomical considerations.

Keywords

Biliary tract obstruction, choledocholithiasis, therapeutic embolization, foreign body migration.

INTRODUCTION

Embolization is a versatile procedure used in the treatment of a wide range of vascular and non-vascular pathologies. However, potential complications are also complex and varied. The success rate of hepatic embolization can be as high as 86%, while the associated morbidity can reach up to 58%, usually related to bile leaks, hepatic abscesses, or necrosis⁽¹⁾. Migration of coils or clips used in surgical procedures into the biliary tract has been reported in the literature, typically as a result of necrosis or fistulization of adjacent structures. Other theories include bacterial or fungal superinfection of pseudoaneurysms and coils, leading to subsequent inflammation and erosion⁽²⁻⁵⁾.

PRESENTATION OF CASES

Case 1

This is a 60-year-old male patient who presented in 2018 with recurrent choledocholithiasis (history of cholecystectomy in 2012). He underwent endoscopic retrograde cholangiopancreatography (ERCP) and biliary stent insertion due to a mismatch between the size of the stones and the distal biliary tract. Furthermore, three additional endoscopic procedures were performed without achieving complete stone removal. In January 2019, the patient consulted for an episode of cholangitis, which was managed with percutaneous biliary drainage. As a late complication, a pseu-

doaneurysm of the right hepatic artery developed, requiring emergent embolization with coils. In February 2019, he underwent open biliary exploration, sphincterotomy, and sphincteroplasty. He reconsulted in 2020 for residual choledocholithiasis and required endoscopic drainage and biliary stent insertion on two occasions.

In May 2022, the patient presented with jaundice. An ERCP was performed, revealing a 15 mm stone in the left hepatic lobe, which could not be extracted. Therefore, electrohydraulic lithotripsy via choledochoscopy was scheduled. During this procedure, multiple choledocholithiasis was identified in relation to migrated foreign bodies (coils) in the biliary duct (**Figures 1 and 2**). The stones and most of the visible coils were successfully removed, a biliary stent was left, and a new endoscopic procedure was scheduled. However, the patient reconsulted for another episode of cholangitis, and a medical board decided to perform a biliary-enteric bypass as definitive management.

Case 2

This is a 54-year-old female patient who underwent laparoscopic cholecystectomy in 2022, resulting in bile duct injury and a biliary fistula. Postoperatively, she required ERCP and stent insertion, as well as management of haemobilia with hemodynamic repercussions secondary to a pseudoaneurysm of the right hepatic artery, which required emergency embolization with coils. She was admitted to the gastroenterology service for a scheduled ERCP and

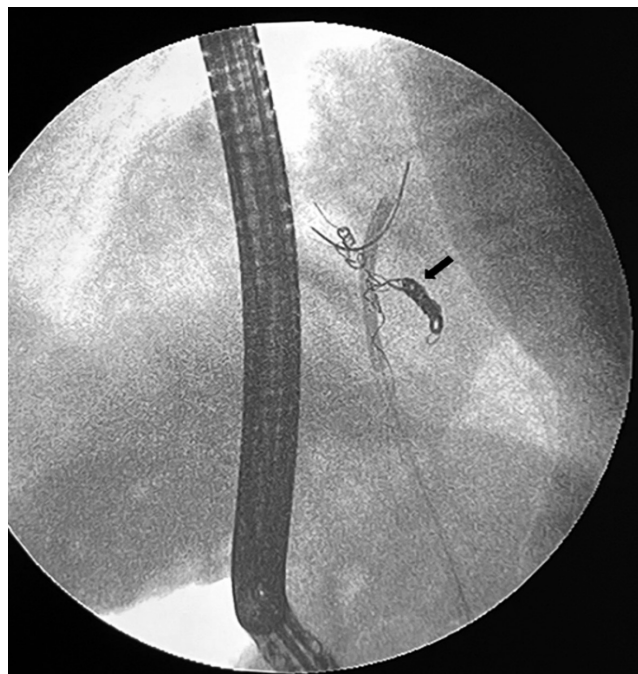

Figure 1. Fluoroscopic view, foreign bodies (coils) within the biliary tract (arrow). The image is the property of the authors.

biliary stent removal eight months after the initial procedure. Fluoroscopic imaging revealed a linear foreign body within the biliary tract, which was successfully extracted using a Dormia basket (coils) (**Figure 3**).

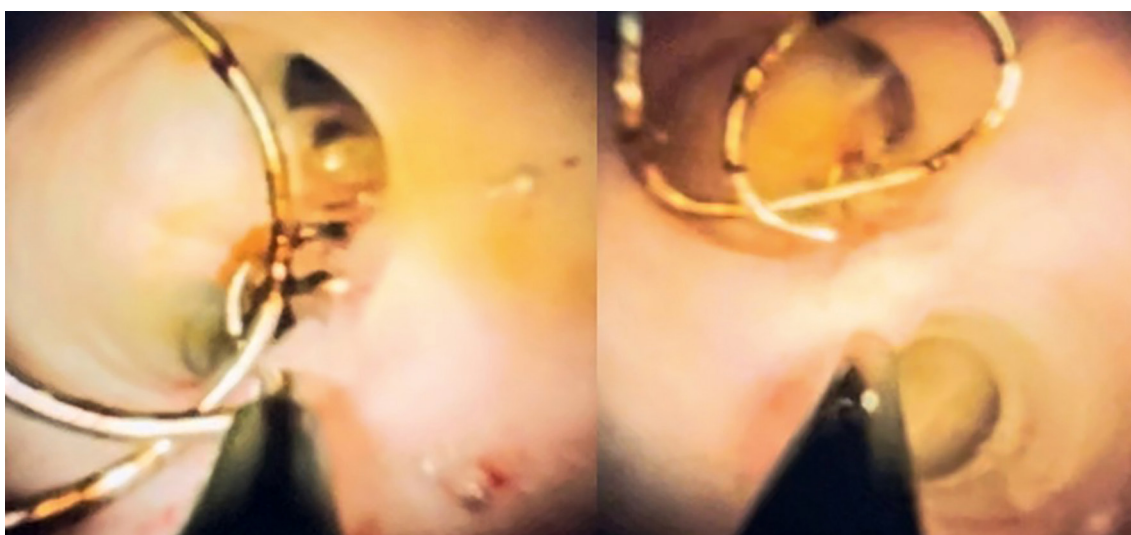


Figure 2. Endoscopic view of the biliary tract with coils inside, using the Spyglass® system. The image is the property of the authors.

DISCUSSION

The migration of intravascular coils into the biliary tract is uncommon and may promote stone formation, increasing the risk of cholangitis, recurrent abdominal pain, and biliary strictures⁽⁶⁾. Their extraction has been described in the literature in several case reports using conventional endoscopic methods, percutaneous approaches, or surgical techniques⁽⁵⁻⁹⁾. However, due to the low frequency of this complication, evidence and information are limited, and therefore, management must be individualized based on the patient's symptoms, clinical course, and anatomy⁽¹⁰⁻¹²⁾.

Endoscopic extraction through ERCP is ideal in the absence of anatomical alterations such as biliodigestive bypass or gastrectomy. Nevertheless, it is important to consider that fluoroscopic imaging may not always allow for the identification of foreign bodies, which are often embedded within stones and may present clinically as recurrent choledocholithiasis, as described in the first case.

Cholangioscopy using the Spyglass® system, through direct visualization of the biliary tract, allows not only for confirmation of the diagnosis but also for treatment, either through ERCP or via the percutaneous (transhepatic) route. It has become the endoscopic technique of choice for the extraction of foreign bodies from the biliary tract and for addressing associated secondary conditions such as choledocholithiasis⁽¹³⁾. However, surgical management may be required in some cases if definitive resolution is not achieved with this method.

CONCLUSIONS

The migration of foreign bodies into the biliary tract is unusual and serves as a contributing factor to stone formation and other complications. Clinical presentation is similar to that of primary or secondary biliary obstruction due to choledocholithiasis, and endoscopic extraction, whenever possible, is the treatment of choice.

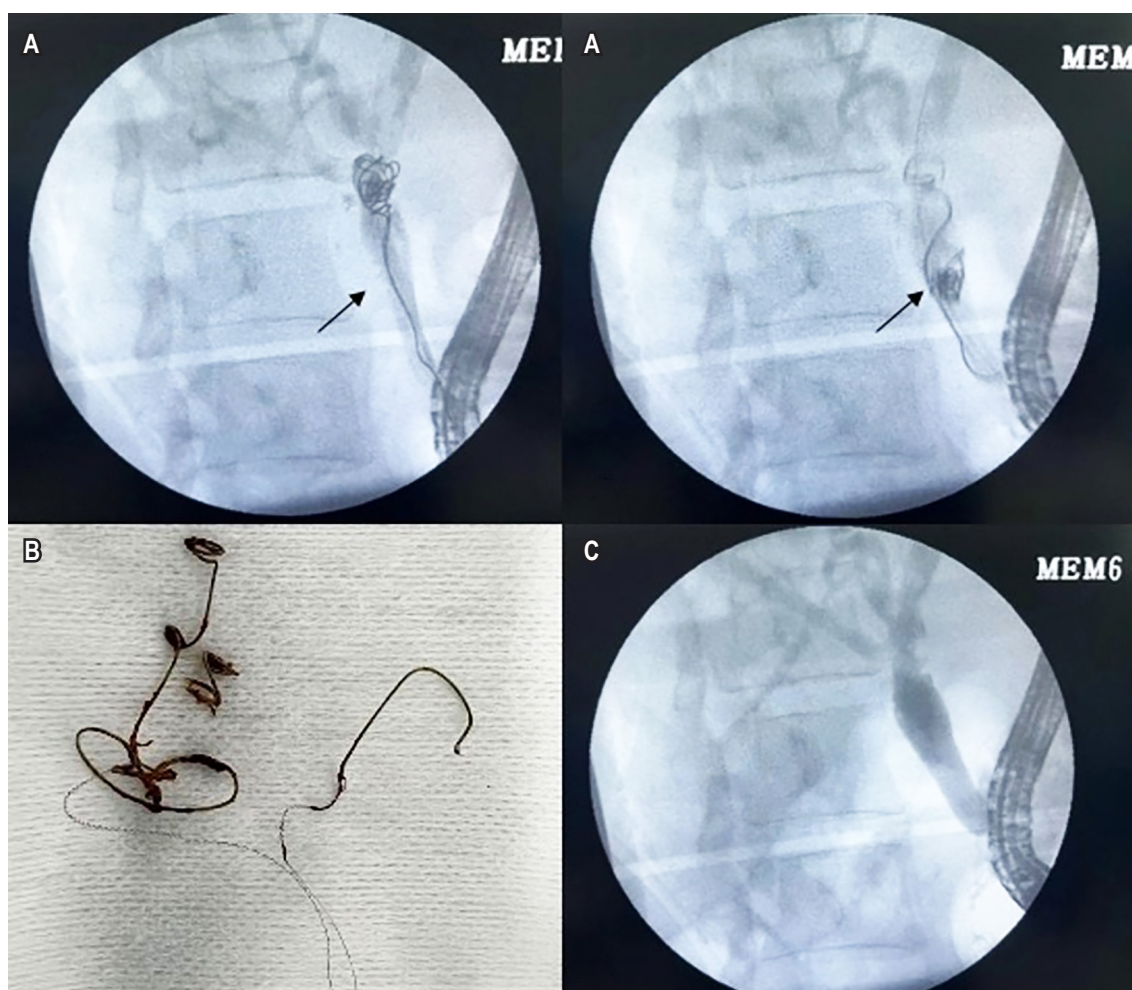


Figure 3. A. Fluoroscopic view, foreign bodies (coils) within the biliary tract (arrow). B. Coils extracted. C. Final cholangiogram. Images property of the authors.

REFERENCES

1. Bilbao JI, Martínez-Cuesta A, Urtasun F, Cosín O. Complications of embolization. *Semin Intervent Radiol*. 2006;23(2):126-42.
<https://doi.org/10.1055/s-2006-941443>
2. Skipworth JRA, Morkane C, Raptis DA, Kennedy L, Johal K, Pendse D, et al. Coil migration - A rare complication of endovascular exclusion of visceral artery pseudoaneurysms and aneurysms. *Ann R Coll Surg Engl*. 2011;93(4):19-23.
<https://doi.org/10.1308/003588411X13008844298652>
3. Bent CK, Wright L, Dong PR. "Coilcholelithiasis"-Common Bile Duct Obstruction Secondary to Migration of Right Hepatic Artery Pseudoaneurysm Coils. *J Vasc Interv Radiol*. 2016;27(11):1741-3.
<https://doi.org/10.1016/j.jvir.2016.07.005>
4. Zervos X, Molina E, Larsen MF. Colangitis secundaria a espirales metálicos emigrados al conducto biliar. *Acta Gastroenterol Latinoam*. 2013;43(2):146-8.
5. Turaga KK, Amirlak B, Davis RE, Yousef K, Richards A, Fitzgibbons RJ. Cholangitis after coil embolization of an iatrogenic hepatic artery pseudoaneurysm: An unusual case report. *Surg Laparosc Endosc Percutaneous Tech*. 2006;16(1):36-8.
<https://doi.org/10.1097/01.sle.0000202189.65160.ef>
6. Schreuder AM, Van Gulik TM, Rauws EAJ. Intrabiliary Migrated Clips and Coils as a Nidus for Biliary Stone Formation: A Rare Complication following Laparoscopic Cholecystectomy. *Case Rep Gastroenterol*. 2018;12(3):686-91.
<https://doi.org/10.1159/000493253>
7. Beard JI, Murphy S, Philips G. A Curious Case of Coil-Angitis. *ACG Case Reports J*. 2019;6(5):e00078.
<https://doi.org/10.14309/crj.0000000000000078>
8. Pua U. Hepatobiliary and Pancreatic: Migration of hepatic coils into the biliary system. *J Gastroenterol Hepatol*. 2012;27(7):1256-1256.
<https://doi.org/10.1111/j.1440-1746.2012.07193.x>
9. Zaafour H, Hasnaoui A, Essghaier S, Haddad D, Sabbah M, Bouhafa A, et al. Ascending Cholangitis secondary to migrated embolization coil of gastroduodenal artery pseudo-aneurysm a case report. *BMC Surg*. 2017;17(1):30.
<https://doi.org/10.1186/s12893-017-0227-9>
10. Alghamdi HS, Saeed MA, Altamimi AR, O'Hali WA, Khankan AA, Altraif IH. Endoscopic extraction of vascular embolization coils that have migrated into the biliary tract in a liver transplant recipient. *Dig Endosc*. 2012;24(6):462-5.
<https://doi.org/10.1111/j.1443-1661.2012.01307.x>
11. Ghalim F, Alatawi A, Leblanc S, Vienne A, Gaudric M, Chaussade S, et al. Endoscopic retrograde cholangioscopic removal of migrated vascular coils from the common bile duct. *Clin Res Hepatol Gastroenterol*. 2014;38(2):e31-2.
<https://doi.org/10.1016/j.clinre.2013.08.007>
12. Zuberi OS, Dinglasan LA V. Biliary obstruction necessitating choledochojunostomy as a complication of endovascular coil erosion. *Radiol Case Reports*. 2018;13(1):167-70.
<https://doi.org/10.1016/j.radcr.2017.10.015>
13. Lee YS. Could the "SpyGlass Direct Visualization" System Open New Horizons for Treating Biliary Tract Diseases as a Percutaneous Cholangioscopy? *Gut Liver*. 2022;16(1):1-2.
<https://doi.org/10.5009/gnl210574>



Available in:

<https://www.redalyc.org/articulo.oa?id=337782267013>

How to cite

Complete issue

More information about this article

Journal's webpage in redalyc.org

Scientific Information System Redalyc
Diamond Open Access scientific journal network
Non-commercial open infrastructure owned by academia

Ileana Rocío Bautista-Parada, Ángel Rojas-Espinosa
Endoscopic Retrieval of Migrated Coils in the Biliary Tract: Case Reports and Literature Review
Extracción endoscópica de coils migrados a la vía biliar: reporte de casos y revisión de la literatura

Revista colombiana de Gastroenterología
vol. 40, no. 1, p. 84 - 87, 2025
Asociación Colombiana de Gastroenterología,
ISSN: 0120-9957
ISSN-E: 2500-7440

DOI: <https://doi.org/10.22516/25007440.1193>