

Periampullary Mass as an Unusual Manifestation of Coccidioidomycosis. Case Report and Literature Review

Jhoan Sebastian Cruz-Barbosa,^{1*}  Andrés Felipe Valencia-Cardona,²  Armando Daniel Cortés-Buelvas.³ 

OPEN ACCESS

Citation:

Cruz-Barbosa JS, Valencia-Cardona AF, Cortés-Buelvas AD. Periampullary Mass as an Unusual Manifestation of Coccidioidomycosis. Case Report and Literature Review. *Revista. colomb. Gastroenterol.* 2023;38(3):373-377. <https://doi.org/10.22516/25007440.965>

¹ Physician and surgeon, Universidad del Valle. Pathological anatomy and clinical pathology resident, Hospital Universitario del Valle. Cali, Colombia.

² Physician, epidemiologist, Universidad del Valle. Second-year anatomy and pathology resident, Hospital Universitario del Valle. Cali, Colombia.

³ Pathological Anatomy and Clinical Laboratory specialist, Universidad del Valle. Head of the Pathology Department, Hospital Universitario del Valle. Cali, Colombia.

*Correspondence: Jhoan Sebastian Cruz-Barbosa.
sebastiancruz@gmail.com

Received: 11/09/2022

Accepted: 13/12/2022



Abstract

In Colombia, coccidioidomycosis is a rare entity, and the intestinal manifestation is infrequent, with around a dozen cases reported in the world literature. This article reports the case of a 29-year-old male Venezuelan immigrant with a 4-month history of abdominal pain, jaundice, nausea, and vomiting. The tomography and the endoscopic study revealed a circumferential exophytic mass in the second portion of the duodenum. The biopsy revealed multiple spherules filled with round fungal endospores with a final diagnosis of disseminated coccidioidomycosis. The patient was discharged before the final pathology report with fluconazole doses of 200 mg every other day and an order for outpatient magnetic resonance cholangiography for outpatient follow-up, which he has not attended.

Keywords

Coccidioides, Colombia, disseminated mycosis, jaundice, systemic mycosis, periampullary tumor.

INTRODUCTION

The ampulla of Vater is located in the second portion of the duodenum at the confluence of the common bile duct and the pancreatic duct of Wirsung. It is surrounded by smooth muscle fibers that make up the sphincter of Oddi⁽¹⁾. Different entities can be located at this level and comprise a broad spectrum, from those with benign biological behavior to carcinomas⁽²⁾. The first group includes adenomas, polyps (Peutz-Jeghers syndrome, juvenile polyposis, Cowden syndrome, familial adenomatous polyposis, and Gardner syndrome), lipomas, leiomyomas, vascular abnormalities, and infectious diseases, particularly tuberculo-

sis⁽²⁾. The malignant scenario includes adenocarcinomas, neuroendocrine tumors, lymphomas, stromal tumors, and metastases, to name a few⁽²⁾.

Coccidioidomycosis is a fungal disease endemic to America. It corresponds to a systemic mycosis that predominantly affects people who visit or reside in rural areas with a dry climate, alkaline soil, annual precipitation rates of around 10 cm, and temperatures of up to 50 °C, favorable environmental conditions for its propagation^(3,4). Most cases have been reported in the United States and Mexico, and *C. posadasii* (82%) is the most related etiological agent⁽⁵⁾.

Patients affected by this disease, in addition to residing in or visiting endemic areas, usually have some degree of

immunosuppression due to chronic diseases such as diabetes *mellitus*. In this scenario, the disease can evolve to severe forms with significant morbidity, characteristics that it shares with tuberculosis, an entity that can manifest synchronously⁽⁶⁾. *Coccidioides* infection occurs through inhalation of arthroconidia of the fungus, and in most cases, is usually asymptomatic and can be indistinguishable from influenza infections or other respiratory viruses, with even fatal manifestations⁽⁷⁾.

In Colombia, there are geographical areas with environmental characteristics conducive to the development of *Coccidioides*, particularly in La Guajira, Magdalena, and Cesar, located on the northern coast, where an exposure between 3% and 13% of the population has been reported through coccidioidin skin testing⁽⁵⁾. Only in two of the five Colombian cases described in the literature did the patient have a history of international travel before the development of the disease^(8,9), and in none of the cases reported to date did the patient have a duodenal mass, jaundice syndrome, and gastrointestinal symptoms.

The present paper seeks to enrich the registry of Colombian cases of *Coccidioides*. This rare pathology has only been reported five times in the last 60 years⁽¹⁰⁾, and to describe an unusual form of clinical manifestation.

CASE DESCRIPTION

We present the case of a 29-year-old Venezuelan male patient from Santander de Quilichao (Cauca, Colombia) who worked as a deliveryman. For 4 months, he had had pain in the epigastrium, emesis of food and bilious content, soft yellow stools, asthenia, and adynamia. In the last 10 days, he noticed a yellow tinge not associated with acholia or choluria, and in the previous 2 days, a single unquantified fever spike, in addition to the weight loss of 16 over the previous last 4 months. During interrogation, he denied any medical history. In the physical examination on admission, the vital signs were within normal ranges, the sclerae were icteric, the abdomen was painful on palpation of the epigastrium without signs of peritoneal irritation, and there was non-painful mobile bilateral inguinal lymphadenopathy. Blood tests showed serum polymerase chain reaction (PCR): 238 mg/dL, total bilirubin: 8.5 mg/dL, direct bilirubin: 4.9 mg/dL, alkaline phosphatase: 2013 UI/L, amylase: 64 U/L, alanine aminotransferase (ALT): 324 IU/L, aspartate aminotransferase (AST): 168 IU/L and blood count with leukocytes: 10,700/ μ L, hemoglobin: 12.3 g/dL, hematocrit: 37.7%, platelets: 467,000/ μ L and neutrophils: 79.8%. The total abdominal ultrasound showed dilation of the intra- and extrahepatic bile duct with an 11 mm common bile duct, without lesions in the liver parenchyma and multiple peripancreatic lymphadenopathy. Subsequently,

a simple and contrast-enhanced abdomen CT scan was ordered, confirming a mass at the periampullary level associated with multiple mesenteric and retroperitoneal lymphadenopathy (**Figure 1**).

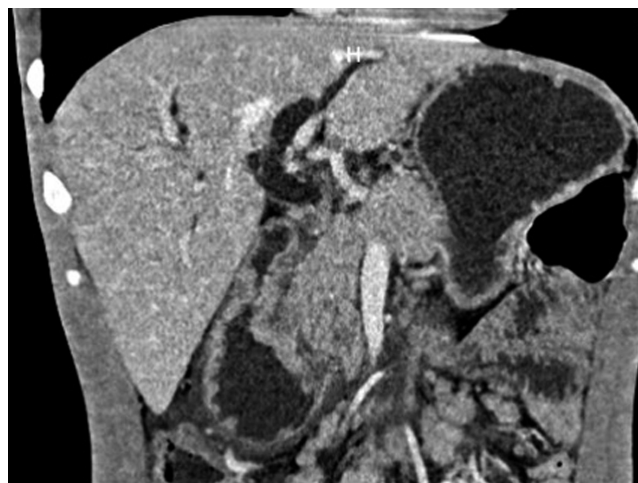


Figure 1. Simple and contrast-enhanced abdominal CT scan: dilation of the intra- and extrahepatic bile duct with a 14-millimeter common bile duct, the pancreas with slight dilation of the Wirsung duct, and loss of contours at the level of the head. The concentric circumferential wall thickened with enhancement after contrast administration and multiple mesenteric, retroperitoneal, latero-aortic, and intercaval-aortic lymphadenopathy in the periampullary region. Source: Radiology Department, Hospital Universitario del Valle.

The CA 19-9 and carcinoembryonic antigen were negative (less than 1.4 U/mL and 1.21 μ g/L, respectively), as was the PCR test for severe acute respiratory syndrome coronavirus type 2 (SARS-CoV-2). Given the imaging characteristics, paraclinical findings, and clinical history, an endoscopic study was considered, which revealed esophageal monilia-sis (KOSI III classification) and a tumor-like lesion in the second portion of the duodenum with stricture of 80% of the lumen. A test for HIV was performed, which was positive. The patient continued under medical management with intravenous fluids and analgesia with clinical and paraclinical improvement, so the study continued on an outpatient basis with antiretroviral therapy, fluconazole, and ivermectin, and he was summoned for a check-up with the results. However, the patient has not attended clinical follow-up.

The anatomopathological study of the endoscopic biopsy of the lesion identified acute and chronic ulcerated duodenitis with a granulomatous component and abundant blastoconidia compatible with *Coccidioides* spp (**Figure 2**).

During the clinical stay, it was considered that he most likely had a neoplasm of epithelial or hematolymphoid origin, and he was discharged for outpatient follow-up with an order for magnetic resonance cholangiography. Still, there were no follow-up data at the time of publication.

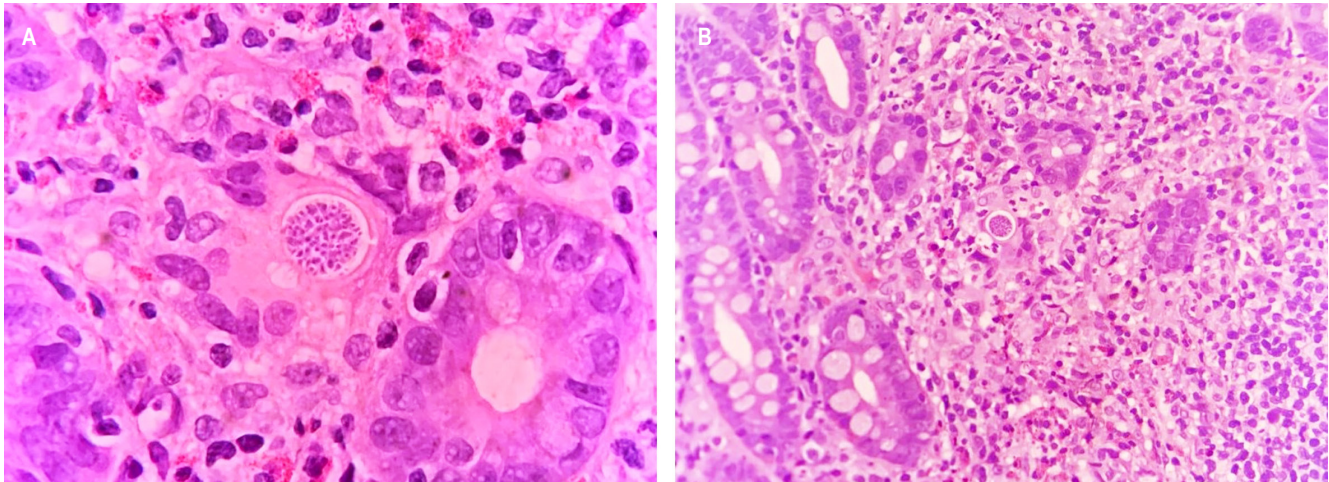


Figure 2. Spherules with endospores in a duodenal mucosa biopsy with mixed inflammatory infiltrate with neutrophils, epithelioid histiocytes, and eosinophils. Source: Pathology Department, Hospital Universitario del Valle.

DISCUSSION AND LITERATURE REVIEW

Disseminated coccidioidomycosis is a rare disease, and although Colombia has some areas with ideal environmental conditions for the proliferation of the microorganism, only five cases have been reported in the last 70 years⁽¹⁰⁾, two of which are related to the migrant population and the rest with the indigenous people. The case presented in this article is the sixth reported to date⁽¹⁰⁾; however, under-registration and difficulties in diagnosing it⁽¹¹⁾ (biosafety standards for culture and identification of *Coccidioides* or serological diagnosis) may mean that the local casuistry is poorly nourished.

Patients with this fungus infection are suspected to be immunosuppressed⁽¹²⁾ (HIV, organ transplant, use of immunomodulatory medications) and reside or have traveled to endemic areas, as is the case of the patient in question. Clinical manifestations fluctuate in a broad spectrum, from asymptomatic subjects (60%) to those requiring management in the ICU and even death⁽¹³⁾. When referring to disseminated mycosis, the manifestation is just as variable as the clinical course; skin, lymph nodes, bone, and central nervous system involvement may be found. Still, practically any organ or system can be affected⁽¹³⁾. Patients' different clinical and sociodemographic conditions have been related to less favorable scenarios. People with diabetes, tobacco users, and adults over 65 years of age exposed to biomass or archaeological sites have a higher risk of severe lung infection⁽¹²⁾. Ethnic origin seems to be a risk factor for severe disease and systemic dissemination: The Caucasian and African-American populations have significantly higher rates of these clinical manifestations⁽¹³⁾.

The extrapulmonary manifestation has been reported in less than 1% of cases in immunocompetent patients and up to 50% of immunocompromised patients⁽¹⁴⁾, as in the case presented, who had *de novo* HIV. Gastrointestinal involvement is rare and is more likely related to hematogenous transition or ingestion of secretions⁽¹⁵⁾.

Coccidioidomycosis is diagnosed by identifying the fungus in the anatomopathological study of the affected tissue, cultures, or PCR assays. The latter can be performed on fresh tissue and tissues fixed in formalin^(16,17). Furthermore, some tests are currently used preferentially in the epidemiological and research field since serological tests have high rates of false positives (up to 20%) and doctors are not familiar with their correct interpretation^(18,19).

Treatment of disseminated disease requires fluconazole at doses of 800 to 1,200 mg/day^(20,21). This medication has response rates of approximately 79%⁽²¹⁾. Nonetheless, lifelong prophylactic use is recommended in immunosuppressed patients due to the high rate of relapses and associated mortality⁽²²⁾.

CONCLUSIONS

Although coccidioidomycosis is an endemic disease in America, Colombia has a prevalence that is well below that of Venezuela and Brazil, probably due to under-reporting and difficulties in diagnosis, in addition to the country's environmental characteristics, which limit the macroenvironment favorable for the proliferation of *Coccidioides* to the northern region of the country.

This case is of particular interest because it initially manifested as a periampullary mass with high suspicion

of neoplasia and rapidly evolving jaundice syndrome, an unusual and unique manifestation according to previous cases reported in Colombia, which corresponded to pulmonary forms.

Mycosis due to this agent in Colombia has a low prevalence. The proximity to Venezuela and the high flow of migrants of this nationality should expand the spectrum of

differential diagnoses in the evaluation of patients with this symptomatology.

Conflicts of interest

The authors state no conflict of interest concerning the publication of this article.

REFERENCES

- Coffin A, Boulay-Coletta I, Sebbag-Sfez D, Zins M. Radioanatomy of the retroperitoneal space. *Diagn Interv Imaging*. 2015;96(2):171-86. <https://doi.org/10.1016/j.diii.2014.06.015>
- Barat M, Dohan A, Dautry R, Barral M, Boudiaf M, Hoeffel C, et al. Mass-forming lesions of the duodenum: A pictorial review. *Diagn Interv Imaging*. 2017;98(10):663-675. <https://doi.org/10.1016/j.diii.2017.01.004>
- Ajello L. Comparative ecology of respiratory mycotic disease agents. *Bacteriol Rev*. 1967;31(1):6-24. <https://doi.org/10.1128/br.31.1.6-24.1967>
- Laniado-Laborín R, Arathoon EG, Canteros C, Muñoz-Salazar R, Rendon A. Coccidioidomycosis in Latin America. *Med Mycol*. 2019;57(Supplement_1):S46-S55. <https://doi.org/10.1093/mmy/myy037>
- Tintelnot K, De Hoog GS, Antweiler E, Losert H, Seibold M, Brandt MA, Van Den Ende AH, Fisher MC. Taxonomic and diagnostic markers for identification of *Coccidioides immitis* and *Coccidioides posadasii*. *Med Mycol*. 2007;45(5):385-93. <https://doi.org/10.1080/13693780701288070>
- Forsbach Sánchez G, Fuentes Pensamiento R. Coccidioidomycosis pulmonar crónica progresiva en una paciente con diabetes mellitus tipo II. *Rev Invest Clin*. 1985;37(1):49-51.
- Saubolle MA, McKellar PP, Sussland D. Epidemiologic, clinical, and diagnostic aspects of coccidioidomycosis. *J Clin Microbiol*. 2007;45(1):26-30. <https://doi.org/10.1128/JCM.02230-06>
- Sales E. Coccidioidomycosis. *Rev Médico-Quirúrgica Atlántico*. 1958;2:289-94.
- Robledo M. Coccidioidomycosis. *Antioquia Med*. 1965;15(5):361-2.
- Canteros CE, Vélez HA, Toranzo AI, Suárez-Alvarez R, Tobón OÁ, Jiménez AMP, et al. Molecular identification of *Coccidioides immitis* in formalin-fixed, paraffin-embedded (FFPE) tissues from a Colombian patient. *Med Mycol*. 2015;53(5):520-7. <https://doi.org/10.1093/mmy/myv019>
- De Pauw B, Walsh TJ, Donnelly JP, Stevens DA, Edwards JE, Calandra T, et al. Revised definitions of invasive fungal disease from the European Organization for Research and Treatment of Cancer/Invasive Fungal Infections Cooperative Group and the National Institute of Allergy and Infectious Diseases Mycoses Study Group (EORTC/MSG) Consensus Group. *Clin Infect Dis*. 2008;46(12):1813-21. <https://doi.org/10.1086/588660>
- Odio CD, Marciano BE, Galgiani JN, Holland SM. Risk Factors for Disseminated Coccidioidomycosis, United States. *Emerg Infect Dis*. 2017;23(2):308-11. <https://doi.org/10.3201/eid2302.160505>
- Bays DJ, Thompson GR 3rd. Coccidioidomycosis. *Infect Dis Clin North Am*. 2021;35(2):453-469. <https://doi.org/10.1016/j.idc.2021.03.010>
- Galgiani JN, Ampel NM, Blair JE, Catanzaro A, Johnson RH, Stevens DA, et al. Coccidioidomycosis. *Clin Infect Dis*. 2005;41(9):1217-23. <https://doi.org/10.1086/496991>
- Malik U, Cheema H, Kandikatla R, Ahmed Y, Chakraborty K. Disseminated Coccidioidomycosis Presenting as Carcinomatosis Peritonei and Intestinal Coccidioidomycosis in a Patient with HIV. *Case Rep Gastroenterol*. 2017;11(1):114-9. <https://doi.org/10.1159/000456655>
- Luna-Isaac JA, Muñoz-Salazar R, Baptista-Rosas RC, Enríquez-Paredes LM, Castañón-Olivares LR, Contreras-Pérez C, et al. Genetic analysis of the endemic fungal pathogens *Coccidioides posadasii* and *Coccidioides immitis* in Mexico. *Med Mycol*. 2014;52(2):156-66. <https://doi.org/10.1093/mmy/myt005>
- Canteros CE, Toranzo A, Suárez-Alvarez R, Davel G, Castañón-Olivares LR, Nápoli J. Identidad genética del hongo causante del primer caso de coccidioidomycosis descrito por Alejandro Posadas en 1892. *Medicina (B Aires)*. 2009;69(2):215-20.
- Ampel NM, Robey I, Nguyen CT. An Analysis of Skin Test Responses to Spherulin-Based Coccidioidin (Spherusol®) Among a Group of Subjects with Various Forms of Active Coccidioidomycosis. *Mycopathologia*. 2019;184(4):533-538. <https://doi.org/10.1007/s11046-019-00356-5>
- McHardy IH, Dinh BN, Waldman S, Stewart E, Bays D, Pappagianis D, et al. Coccidioidomycosis Complement Fixation Titer Trends in the Age of Antifungals. *J Clin Microbiol*. 2018;56(12):e01318-18. <https://doi.org/10.1128/JCM.01318-18>

20. Johnson RH, Einstein HE. Coccidioidal meningitis. Clin Infect Dis. 2006;42(1):103-7.
<https://doi.org/10.1086/497596>
21. Galgiani JN, Catanzaro A, Cloud GA, Higgs J, Friedman BA, Larsen RA, et al. Fluconazole therapy for coccidioidal meningitis. The NIAID-Mycoses Study Group. Ann Intern Med. 1993;119(1):28-35.
<https://doi.org/10.7326/0003-4819-119-1-199307010-00005>
22. Dewsnap DH, Galgiani JN, Graybill JR, Diaz M, Rendon A, Cloud GA, et al. Is it ever safe to stop azole therapy for *Coccidioides immitis* meningitis? Ann Intern Med. 1996;124(3):305-10.
<https://doi.org/10.7326/0003-4819-124-3-199602010-00004>



Available in:

<https://www.redalyc.org/articulo.oa?id=337782275018>

How to cite

Complete issue

More information about this article

Journal's webpage in redalyc.org

Scientific Information System Redalyc
Diamond Open Access scientific journal network
Non-commercial open infrastructure owned by academia

Jhoan Sebastian Cruz-Barbosa,
Andrés Felipe Valencia-Cardona,
Armando Daniel Cortés-Buelvas

**Periampullary Mass as an Unusual Manifestation of
Coccidioidomycosis. Case Report and Literature Review
Masa periampular como presentación inusual de
coccidioidomicosis. Reporte de un caso y revisión de la
literatura**

Revista colombiana de Gastroenterología
vol. 38, no. 3, p. 373 - 377, 2023
Asociación Colombiana de Gastroenterología,
ISSN: 0120-9957
ISSN-E: 2500-7440

DOI: <https://doi.org/10.22516/25007440.965>