

Percutaneous Endoscopic Gastrostomy. Is It Truly Harmless?

Martín Alonso Gómez-Zuleta,^{1*}  Javier Humberto Riveros-Vega,²  Óscar Ruiz-Morales.³ 

OPEN ACCESS

Citation:

Gómez-Zuleta MA, Riveros-Vega JH, Ruiz-Morales O. Percutaneous Endoscopic Gastrostomy. Is It Truly Harmless?. *Revista. colomb. Gastroenterol.* 2023;38(4):467-471. <https://doi.org/10.22516/25007440.1037>

¹ Internist and gastroenterologist. Associate professor of Gastroenterology, coordinator of the Gastroenterology unit, Hospital Universitario Nacional de Colombia, Universidad Nacional de Colombia. Bogotá, Colombia.

² Internist and gastroenterologist, Universidad Nacional de Colombia. Bogotá, Colombia.

³ Internist and gastroenterologist, Hospital Universitario Nacional de Colombia. Bogotá, Colombia.

*Correspondence: Martín Alonso Gómez-Zuleta.
martinalonsogomez@gmail.com

Received: 08/03/2023

Accepted: 12/04/2023



Abstract

Percutaneous endoscopic gastrostomy (PEG) is performed quite frequently in our environment. In general, its complications are few and mostly minor; however, there is a 2.4% incidence of significant complications, particularly abnormal displacement of the internal bumper of the gastrostomy, known as *buried bumper syndrome* (BBS). Serious infections, tears, and fistulas can also occur. This work illustrates five cases of severe complications of PEG.

Keywords

Gastrostomy, complications, buried bumper, infection.

INTRODUCTION

Percutaneous endoscopic gastrostomy (PEG) is a method to guarantee nutrition for patients with dysphagia of different etiologies and risk of broncho-aspiration, among others. Since its introduction by Gauderer and Ponsky in 1980⁽¹⁾, it has become one of the most used methods for this purpose. In the United States, nearly 250,000 procedures are performed yearly⁽²⁾. Still, despite their safety and technical ease, complications can occur in 0.4% to 22.5%⁽³⁾, which, depending on their severity, can be classified as major and minor (**Table 1** and **Video 1**).

One of the most feared complications of gastrostomy is buried bumper syndrome (BBS), whose incidence is 1%

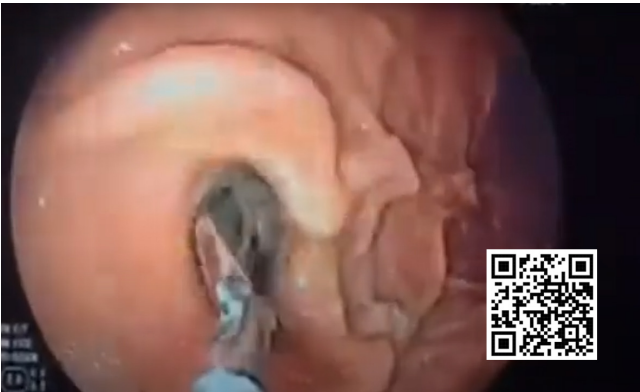
(0.3%–2.4%)⁽³⁾. It is characterized by the following triad: inability to insert the tube, loss of permeability, and leakage through the tube's stoma⁽⁴⁾, and occurs when the internal end of the gastrostomy migrates toward the stomach wall, even to the point of coming out of it. Therapy depends on migration related to the muscularis propria. In turn, BBS can cause other complications such as bleeding, perforation, peritonitis, and intra-abdominal or wall abscesses⁽⁵⁾.

From the pathophysiological point of view, BBS occurs due to an increase in pressure between the internal and external fixation of the gastrostomy, resulting in ischemia and necrosis of the tissue, then inflammation and fibrosis, and finally, the displacement of the external fixation and thus the BBS⁽⁵⁾. The main risk factors depend on the

Table 1. Complications of percutaneous endoscopic gastrostomy⁽³⁾

Major complications	Minor complications
Necrotizing fasciitis	Skin infection
Buried bumper syndrome	Peristomal leakage
Colocutaneous fistula	Pneumoperitoneum
Gastrocolic fistula	Ileus
Gastric perforation	Bleeding
Massive broncho-aspiration	Tube site ulceration
	Blockage due to food sediment
	Tube deterioration
	Gastric outlet obstruction

Taken from: Itkin M, et al. Gastroenterology. 2011;141(2):742-765.



Video 1. Video of the main complications of endoscopic gastrostomy. Source: Unidad de Gastroenterología y Ecoendoscopia UGEC (2019, August 25th). Gastrostomía [video]. YouTube. <https://n9.cl/fam1h>

tube, the procedure, care with the device, and the patient (**Figure 1**).

From a diagnostic perspective, once the characteristic triad is suspected, an endoscopy of the upper GI tract and imaging should be performed to assess the relationship of the external fixation with the gastric wall. Then, the best available therapy, which can be medical, endoscopic, or surgical, will be given (**Table 2**)⁽¹⁾.

Below is a series of clinical cases illustrating serious complications after endoscopic gastrostomy^(7,8). We must be aware of such complications and evaluate the patient

well before deciding whether the procedure is indicated, together with the patient and their family.

CASE 1

A 54-year-old female patient with a history of an extensive hemorrhagic stroke and severe compromise in the swallowing pattern without a good response to rehabilitation underwent a PEG. Ten days later, a call was received from the treatment group due to an obstruction to the nutrition passage of the gastrostomy. Due to suspicion of

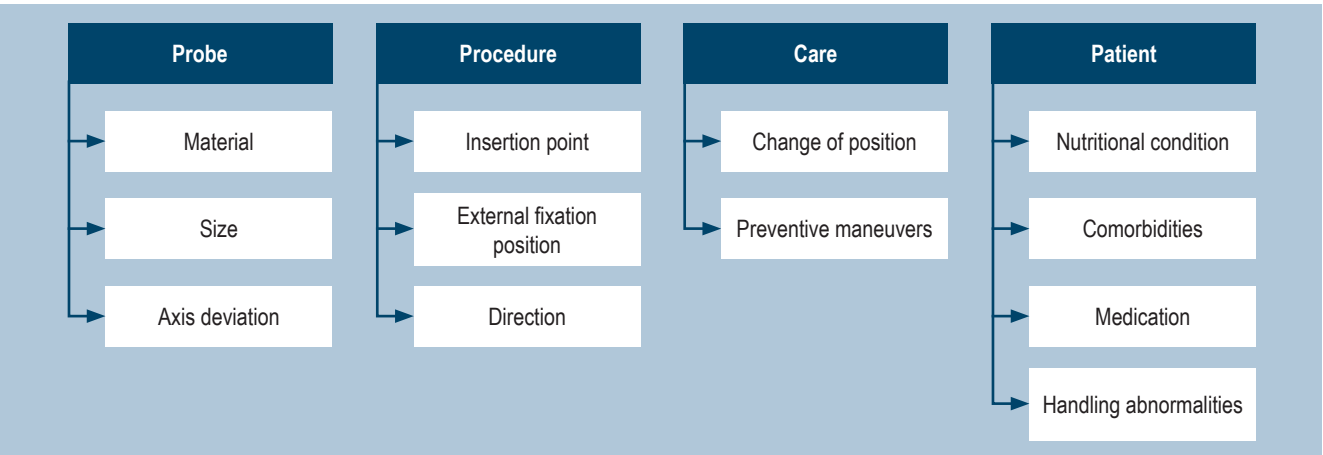


Figure 1. Risk factors for BBS⁽⁵⁾. Taken from: Schwartz HI et al. PEG feeding tube migration impaction in the abdominal wall. Gastrointest Endosc. 1989;35(2):134.

Table 2. BBS severity classification⁽⁶⁾

Grade	Clinical	Endoscopic	Radiological	Treatment
0	Movable	Normal	No	Prevention
1	Movable	Ulcer around the disc	No	Prevention
2	Fixed	>50% of the disk is visible	No	Endoscopy
3	Fixed	100% covered	Disc inside the stomach	Endoscopy, dissection
4	Fixed/Blocked	100% covered	Disc outside the stomach	Endoscopy, dissection
5	Subcutaneous disc	100% covered	No	Surgery/Extraction

Taken from: McClave SA, et al. *Gastrointest Endosc Clin N Am.* 2007;17(4):731-746.

BBS, we decided to perform an endoscopy, which showed the internal disc occluded by gastric tissue in more than 50% (**Figure 2**). An attempt was made to recover the foreign body with forceps unsuccessfully. So, a tube was cut before the external retention disc, and the guidewire was advanced through it. It was retrieved with a handle and attached to the gastrostomy tube, which was pulled using the push-pull technique. Once it came out through the abdominal wall, the tube was recovered, and the fistula was left patent with the new tube in a suitable position.

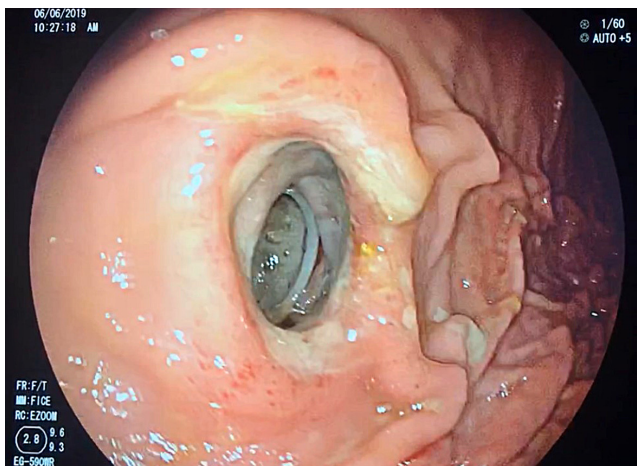


Figure 2. Type 2 buried bumper syndrome. The internal disc shows an occlusion of less than 50%. Authors' archive.

CASE 2

A 44-year-old female patient with a history of severe head trauma and severe swallowing disorder required a PEG. She was received through interconsultation for not having adequate mobility of the tube and a peristomal leak. We

decided to take her to an endoscopy, showing an absence of the internal disc in the gastric cavity. Finally, she was diagnosed with Type 3 BBS (**Figure 3**). We performed a precut dissection in which the affected internal disc was found in the gastric wall. Once freed, it was successfully extracted.

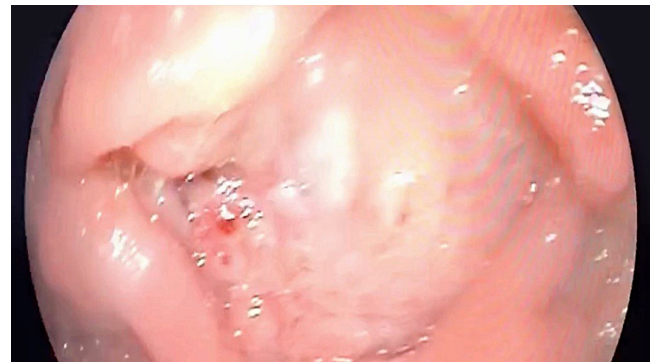

Figure 3. Type 3 buried bumper syndrome: gastrostomy disc completely covered by gastric mucosa. Authors' archive.

CASE 3

A 65-year-old male patient with sequelae of post-cardiac arrest hypoxic-ischemic encephalopathy required PEG due to a severe swallowing disorder. The attending group requested an evaluation (15 days after the gastrostomy) due to liquid stools with the same characteristics as the nutrition each time it was administered through a tube. He underwent an endoscopy, and the internal disc was not found. Given the clinical picture, displacement of the internal disc outside the stomach (gastrocolic fistula) was suspected (**Figure 4**). A total colonoscopy was performed, finding the internal retention disc of the gastrostomy at the transverse colon level. We decided to remove the tube and

leave him under observation for seven days, after which total closure of the fistula was observed on endoscopic follow-up.

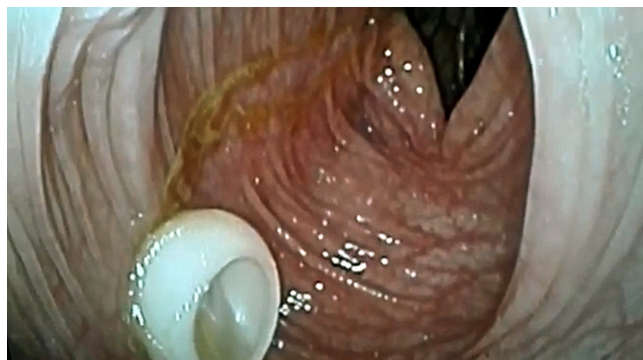


Figure 4. Gastrocolic fistula: internal disc outside the gastric cavity at the transverse colon level. Authors' archive.

CASE 4

A 74-year-old male patient with sequelae of an ischemic stroke required endoscopic gastrostomy. Once the tube was pulled toward the wall and the external retention disc was fixed, an endoscopy was performed to assess the position, finding a severe tear of the gastric mucosa toward the greater curvature (**Figure 5**); no overt perforation was observed endoscopically. The patient did not have an acute abdomen on physical examination, so the gastrostomy was fixed and left under observation. A new endoscopy was performed seven days later, noting that the tear had healed.

CASE 5

A 50-year-old male patient with sequelae of an ischemic stroke underwent PEG for a swallowing disorder. Seventy-two hours after the procedure, edema and erythema were found in the peristomal area, rapidly progressing to the rest of the abdominal wall, forming fasciitis (**Figure 6**). A soft tissue ultrasound was performed without finding wall collections but fascia inflammation. With the diagnosis of surgical site infection, the tube was removed, and parenteral antibiotic therapy was started. The nasogastric nutrition tube was advanced to ensure enteral nutrition. Once the infection resolved, a new gastrostomy was performed without complications.

CONCLUSIONS

Endoscopic gastrostomy is a therapeutic procedure performed regularly in clinical practice, given the high incidence of diseases that result in swallowing disorders or oral tolerance. However, the frequent use of this procedure does

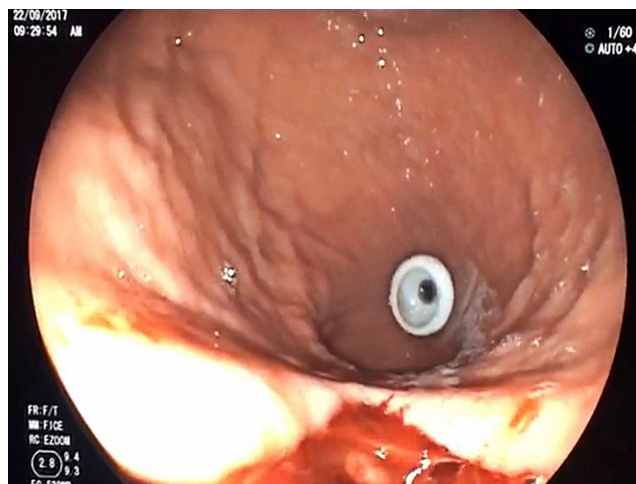


Figure 5. Tear of the gastric mucosa due to the passage of the internal disc. Authors' archive.

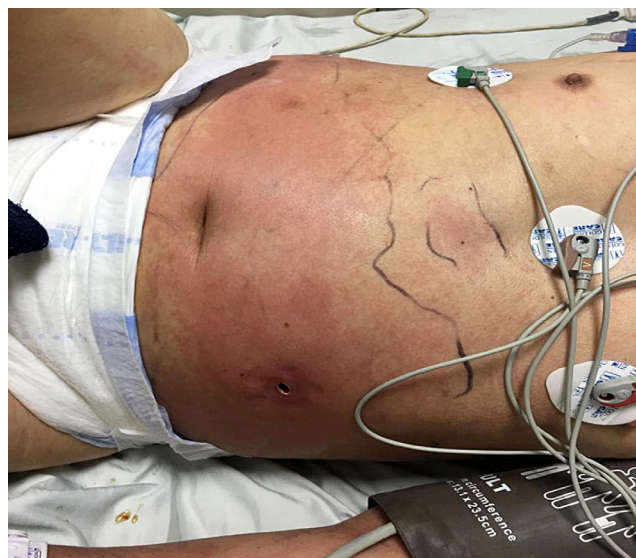

Figure 6. Infection of the abdominal wall. Authors' archive.

not exempt it from mild or complex complications, such as those shown in this work.

Infection, bleeding, and diverse types of BBS are the most common complications. These depend on multiple factors, which must be controlled to prevent their occurrence. Once suspected, the physical examination is vital, and the tube seeks to assess the triad of BBS: absence of mobility, parastomal leak, and obstruction to fluid passage. The assessment must be complemented with an endoscopy and, if necessary, a radiological study to classify the complication and plan the best possible treatment, ranging from observation to endoscopic or surgical management.

REFERENCES

1. Gauderer MW, Ponsky JL, Izant RJ. Gastrostomy without laparotomy: a percutaneous endoscopic technique. *J Pediatr Surg.* 1980;15(6):872-875. [https://doi.org/10.1016/S0022-3468\(80\)80296-X](https://doi.org/10.1016/S0022-3468(80)80296-X)
2. Cyrany J, Rejchrt S, Kopacova M, Bures J. Buried bumper syndrome: complication of percutaneous endoscopic gastrostomy. *World J Gastroenterol.* 2016;22(2):618-627. <https://doi.org/10.3748/wjg.v22.i2.618>
3. Itkin M, DeLegge MH, Fang JC, McClave SA, Kundu S, d'Othee BJ, et al. Multidisciplinary practical guidelines for gastrointestinal access for enteral nutrition and decompression from the Society of Interventional Radiology and American Gastroenterological Association (AGA) Institute, with endorsement by Canadian Interventional Radiological Association (CIRA) and Cardiovascular and Interventional Radiological Society of Europe (CIRSE). *Gastroenterology.* 2011;141(2):742-765. <https://doi.org/10.1053/j.gastro.2011.06.001>
4. El AZ, Arvanitakis M, Ballarin A, Devière J, Le Moine O, Van Gossum A. Buried bumper syndrome: low incidence and safe endoscopic management. *Acta Gastroenterol Belg.* 2011;74(2):312-316.
5. Schwartz HI, Goldberg RI, Barkin JS, Phillips RS, Land A, Hecht M. PEG feeding tube migration impaction in the abdominal wall. *Gastrointest Endosc.* 1989;35(2):134. [https://doi.org/10.1016/S0016-5107\(89\)72735-8](https://doi.org/10.1016/S0016-5107(89)72735-8)
6. McClave SA, Jafri NS. Spectrum of morbidity related to bolster placement at time of percutaneous endoscopic gastrostomy: buried bumper syndrome to eakage and peritonitis. *Gastrointest Endosc Clin N Am.* 2007;17(4):731-746. <https://doi.org/10.1016/j.giec.2007.07.011>
7. Cyrany J, Repak R, Douda T, Rejchrt S, Kopacova M, Bures J. Buried bumper syndrome - management based of accurate staging. *United European Gastroenterol J.* 2014;2 Suppl 1:A170.
8. Boeykens K, Duysburgh I. Prevention and management of major complications in percutaneous endoscopic gastrostomy. *BMJ Open Gastroenterol.* 2021;8(1):e000628. <https://doi.org/10.1136/bmjgast-2021-000628>



Disponible en:

<https://www.redalyc.org/articulo.oa?id=337782276008>

Cómo citar el artículo

Número completo

Más información del artículo

Página de la revista en redalyc.org

Sistema de Información Científica Redalyc
Red de revistas científicas de Acceso Abierto diamante
Infraestructura abierta no comercial propiedad de la
academia

Martín Alonso Gómez-Zuleta, Javier Humberto Riveros-Vega,
Óscar Ruiz-Morales

**Percutaneous Endoscopic Gastrostomy. Is It Truly
Harmless?**

**Gastrostomía endoscópica percutánea. ¿Es realmente
inofensiva?**

Revista colombiana de Gastroenterología

vol. 38, núm. 4, p. 467 - 471, 2023

Asociación Colombiana de Gastroenterología,

ISSN: 0120-9957

ISSN-E: 2500-7440

DOI: <https://doi.org/10.22516/25007440.1037>