

# Giant Submucosal Lipoma of the Right Colon Spontaneously Expelled Rectally: Case Report

Faruk Hernández-Sampayo,<sup>1</sup>  Pablo Salomón Montes-Arcón,<sup>2\*</sup>  Paola María Blanco-Pertuz,<sup>3</sup>  Gloria Caterine Pérez-Mingán.<sup>3</sup> 

## OPEN ACCESS

### Citation:

Hernández-Sampayo F, Montes-Arcón PS, Blanco-Pertuz PM, Pérez-Mingán GC. Giant Submucosal Lipoma of the Right Colon Spontaneously Expelled Rectally: Case Report. *Revista. colomb. Gastroenterol.* 2023;38(4):539-542. <https://doi.org/10.22516/25007440.998>

<sup>1</sup> General surgeon, Universidad Metropolitana; gastroenterology resident, Universidad de Cartagena. Cartagena, Colombia.

<sup>2</sup> Second-year resident, Pathology graduate program, Universidad de Cartagena. Cartagena, Bolívar, Colombia.

<sup>3</sup> Second-year resident, Internal Medicine graduate program, Universidad de Cartagena. Cartagena, Colombia.

\*Correspondence: Pablo Salomón Montes-Arcón.  
[pmontesarcon@gmail.com](mailto:pmontesarcon@gmail.com)

Received: 13/12/2022

Accepted: 06/07/2023



## Abstract

Colonic lipomas are benign tumors originating in mesenchymal tissue and are considered the second most common benign tumor in the colon after adenomatous polyps. They tend to affect women more; their most frequent location is the right colon. Generally, these lipomas do not exhibit symptoms, but when they reach a considerable size, they can cause manifestations. They can also result in complications such as obstruction, intussusception, and perforation.

Since their radiological characteristics are similar to fat, they can be visualized using computed tomography. Still, the final diagnosis is made through colonoscopy, where a fatty mass with an oval shape and elastic capacity is observed. Lesions can be removed endoscopically or surgically. Spontaneous expulsion of a lipoma rectally is rare, and its mechanism is not yet fully understood. Although the literature establishes a cut-off point of 2 cm to decide between endoscopic or laparoscopic resection, the former is increasing and can extend this limit. Surgical resection is recommended in cases such as the one in this article. This case is the biggest reported colonic lipoma (13 cm) expelled spontaneously.

## Keywords

Lipoma, tumor, colon, intestine.

## INTRODUCTION

Lipomas are soft tissue tumors derived from mature adipocytes, first described by Bauer in 1757, which are macroscopically and radiologically indistinguishable from normal adipose tissue; epidemiologically, they are the most frequent injuries derived from soft tissues in adult patients, with a slight predominance in male patients<sup>(1)</sup>.

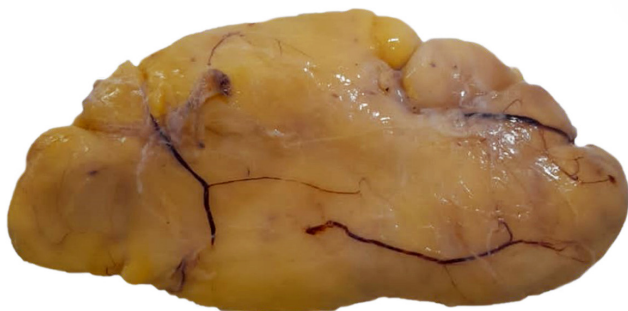Location in the GI tract is infrequent and generally asymptomatic, which can be detected incidentally during surgery, colonoscopy, or autopsy<sup>(2)</sup>. Lipomas are often soli-

tary lesions of submucosal origin found in the proximal colon and typically measure less than 2 cm in size, with a maximum diameter of 8.5 cm reported in the literature<sup>(3)</sup>. Despite new techniques for radiological diagnosis, the gold standard continues to be a histopathological evaluation that leads to the precise diagnosis of this entity; the manner of removal depends on the manifestation of the case and could result in elective or emergent removal<sup>(4)</sup>.

The article reports the case of a female patient who spontaneously expelled part of a giant submucosal lipoma via the rectum and required a secondary laparoscopic resection of the entire surgical specimen.

## CASE DESCRIPTION

A 42-year-old female patient with no significant pathological history consulted for a clinical condition of one year of evolution that had worsened in the previous 12 hours. It was characterized by non-radiating colic-type pain in the mesogastrium, without mitigating or aggravating factors, whose intensity was 5/10 on the visual analog scale. It was accompanied by the expulsion of a soft, non-fouling, yellowish mass through the rectum (**Figure 1**).



**Figure 1.** Lipoma expelled rectally with well-defined walls and no signs of bleeding. Source: Authors' archive.

Therefore, the patient attended the emergency department. During the interrogation, she reported a condition of intestinal intussusception ten months ago of unknown cause, which self-resolved and required hospitalization for three days. Considering this and the abdominal pain, a contrast-enhanced abdomen CT was requested, describing a lipomatous-type lesion at the ascending colon level (**Figure 2**).

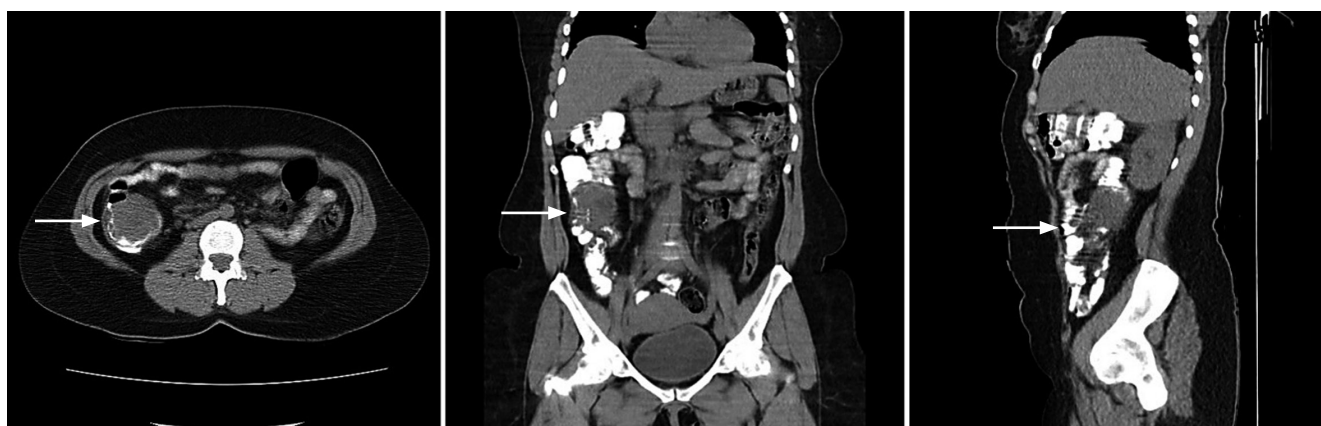
In this context, the general surgery service evaluated the patient and suggested a total colonoscopy. It showed a raised, sessile, mamelonated, subepithelial lesion of approximately 6 cm in diameter at the right colon level near the cecum, which occupied one-third of the lumen of the colon (**Figure 3**).

The final pathological diagnosis of the spontaneously expelled specimen was a lipoma measuring  $7 \times 5 \times 4$  cm and weighing 117 g. A medical meeting was held with the gastroenterology and general surgery team, where they determined to perform a laparoscopic resection of the residual lesion, taking into account the history of intussusception less than one year ago and the reports in the literature, which will be addressed in the discussion of this article. A laparoscopic segmental colectomy-type procedure with end-to-end anastomosis was performed using mechanical staplers with negative margins. The patient remains asymptomatic one year after the procedure.

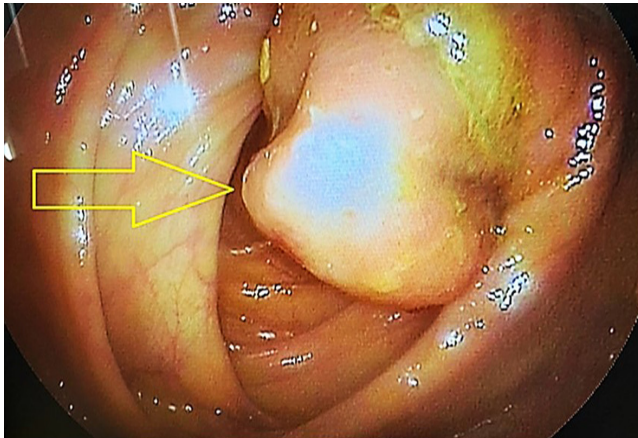
## DISCUSSION

Colonic lipomas are benign tumors of mesenchymal origin whose manifestation is exceptional. They are consolidated as the most common benign colonic tumor, only preceded by adenomatous polyps<sup>(5)</sup>. Its incidence ranges between 0.2% and 4.4%, with a predominance in the female sex; the age of onset is, on average, between 40 and 50 years. Regarding its location, the most frequent location is the right colon, which represents 65% to 75% of all cases<sup>(6,7)</sup>.

Other authors, such as Rogy et al., published a series of cases evaluated over ten years in referral centers and found that lipomas represented 0.3% of colorectal diseases in general and 1.8% of benign colon tumors, with a greater



**Figure 2.** CT image showing, in different sections, a radiolucent tumor with well-defined edges in the right colon. Source: Authors' archive.



**Figure 3.** Endoscopic view of a subepithelial lesion occupying one-third of the colon's lumen. Source: Authors' archive.

frequency in women, in the right colon, and solitary in 90%; the remaining 10% corresponded to multiple manifestations<sup>(8)</sup>.

Generally, these lesions are asymptomatic; however, 30% of large lesions will cause symptoms, especially when they measure more than 2 cm; the most common manifestations include abdominal pain, rectal bleeding, and changes in bowel movements<sup>(9,10)</sup>. It should be noted that abdominal pain may be secondary to permanent intestinal intussusception, and the lipoma serves as the head of the intussusception. At the same time, rectal bleeding could be explained by ulceration of the mucosa that covers the lipoma. Unusual complications of colonic lipoma include obstruction, intussusception, perforation, and severe bleeding<sup>(11)</sup>.

The clinical significance of lipoma is the high probability of being confused with malignant neoplasms of the colon due to similar characteristics in clinical manifestations; however, no malignant changes associated with this type of lesion have been reported<sup>(12)</sup>.

Concerning the diagnosis, the radiolucent characteristics of the fat mean that these tumors can be visualized by CT of the abdomen and barium enema, which makes it clear that it has a low sensitivity to tumors smaller than 1.5 cm;

still, the diagnosis is fundamentally endoscopic, which can visualize a fatty, ovoid-looking mass with a specific elastic capacity to return to its initial shape after being pinched with a clamp (pillow sign)<sup>(8)</sup>. Since it is below the normal mucosa, a lesion biopsy is not recommended due to the low diagnostic yield. On the contrary, it increases the risks of bleeding and perforation. The gold standard for diagnosing colonic lipoma is based on histopathological diagnosis<sup>(13)</sup>.

Treatment varies according to the lesion size; in lesions smaller than 2 cm, endoscopic en bloc resection can be considered; however, surgical resection is recommended in those with a diameter greater than 2 cm due to the risk of existing perforation since fatty tissue is a poor electrical conductor and can increase the risk of complications in endoscopic resection. Usually, lesions with complete resection do not recur, and the procedures are curative. This controversial analysis occurred between the gastroenterology and general surgery teams when choosing the surgical procedure for the patient. Lipomas are benign tumors with null degeneration, so resection is justified to prevent or treat complications<sup>(8,14,15)</sup>.

The spontaneous expulsion of a lipoma rectally is rare and practically anecdotal; the mechanism of self-dissection of a lipoma is unknown. It is believed that in pedunculated lipomas, the pedicle could suffer strangulation and subsequent necrosis, causing its detachment. Another way would be the ulceration of the mucosa that covers the lipoma and its exit into the colonic lumen<sup>(16)</sup>.

## CONCLUSION

It is important to emphasize that, although the literature is emphatic in taking 2 cm as a cut-off point to choose between endoscopic versus laparoscopic resection, the endoscopic experience curve is currently increasing, which will undoubtedly lead to new consensuses that expand this diameter to attempt more advanced resections. However, in this case, considering that the lesion measured 6 cm, no one on the endoscopic team considered they had the expertise to perform it. If we add the 6 cm of the colonic lesion plus the spontaneously expelled 7 cm, it measures 13 cm, making this case the most giant colon lipoma reported to date.

## REFERENCES

1. Liyen Cartelle A, Uy PP, Yap JEL. Giant Colonic Lipoma Presenting as Intermittent Colonic Obstruction with Hematochezia. *Cureus*. 2020;12(11):e11434. <https://doi.org/10.7759/cureus.11434>
2. Farfour AN, Abu Omar NA, Alsohaibani FI. Lipoma grande de colon ascendente: reporte de un caso y revisión de la literatura. *J Surg Case Rep*. 2020;2020(9):rjaa354. <https://doi.org/10.1093/jscr/rjaa354>

3. Sapalidis K, Laskou S, Kosmidis C, Passos I, Mantalobas S, Michalopoulos N, et al. Symptomatic colonic lipomas: Report of two cases and a review of the literature. *SAGE Open Med Case Rep.* 2019;7:2050313X19830477. <https://doi.org/10.1177/2050313X19830477>
4. Menegon Tasselli F, Urraro F, Sciaudone G, Bagaglini G, Pagliuca F, Reginelli A, et al. Colonic Lipoma Causing Bowel Intussusception: An Up-to-Date Systematic Review. *J Clin Med.* 2021;10(21):5149. <https://doi.org/10.3390/jcm10215149>
5. An HH, Duong TT, Van Truong N, Van Quoc L, Son VN, Thang NP, et al. A large lipoma of the descending colon: A rare case report. *Radiol Case Rep.* 2021;16(11):3396-99. <https://doi.org/10.1016/j.radcr.2021.08.013>
6. Ozen O, Guler Y, Yuksel Y. Giant colonic lipoma causing intussusception: CT scan and clinical findings. *Pan Afr Med J.* 2019;32:27. <https://doi.org/10.11604/pamj.2019.32.27.18040>
7. Chahri N, Querol V, Ballesta E. Expulsión espontánea de gran lipoma de colon izquierdo. *Rev Esp Enferm Dig.* 2013;105(8):502-3. <https://doi.org/10.4321/S1130-01082013000800013>
8. Pastor C, Valentí V, Poveda I, Martí P, Zozaya G, Baixauli J, et al. Lipomas submucosos de colon. *Rev. esp. enferm. dig.* 2007;99(5): 299-300.
9. Zenaidi H, Ismail IB, Rekik F, Aziz M, Rebii S, Zoghliami A. Large pedunculated colonic lipoma: a rare cause of colorectal intussusception in adults. *Pan Afr Med J.* 2020;36:200. <https://doi.org/10.11604/pamj.2020.36.200.24606>
10. Yeom JO, Kim SY, Jang EC, Yu JY, Chang ED, Cho YS. Colonic lipoma covered by hyperplastic epithelium: Case report. *World J Clin Cases.* 2013;1(3):124-7. <https://doi.org/10.12998/wjcc.v1.i3.124>
11. Presti ME, Flynn ME, Schuval DM, Vollmar TM, Zotos VD. Colonic Lipoma With Gastrointestinal Bleeding and Intussusception. *ACG Case Rep J.* 2015;2(3):135-6. <https://doi.org/10.14309/crj.2015.32>
12. Lee JM, Kim JH, Kim M, Kim JH, Lee YB, Lee JH, et al. Endoscopic submucosal dissection of a large colonic lipoma: Report of two cases. *World J Gastroenterol.* 2015;21(10):3127-31. <https://doi.org/10.3748/wjg.v21.i10.3127>
13. Zhou XC, Hu KQ, Jiang Y. A 4-cm lipoma of the transverse colon causing colonic intussusception: A case report and literature review. *Oncol Lett.* 2014;8(3):1090-92. <https://doi.org/10.3892/ol.2014.2278>
14. Meunier M, Limgba A, Schumacker I, Mehdi A. Intussusception related to transverse colonic lipoma: a case report and review of the literature. *Acta Chir Belg.* 2022;122(1):51-5. <https://doi.org/10.1080/00015458.2020.1739843>
15. Chase MP, Yarze JC. Giant lipoma-to attempt endoscopic resection or not? *Am J Gastroenterol.* 2000;95(8):2143-4. <https://doi.org/10.1111/j.1572-0241.2000.02221.x>
16. Allawati M, Logman T, Al Qubtan MT. Colonic Lipoma as a Leading Cause of Intussusception Resulting in Bowel Obstruction. *Cureus.* 2021;13(9):e18261. <https://doi.org/10.7759/cureus.18261>



**Disponible en:**

<https://www.redalyc.org/articulo.oa?id=337782276020>

Cómo citar el artículo

Número completo

Más información del artículo

Página de la revista en redalyc.org

Sistema de Información Científica Redalyc  
Red de revistas científicas de Acceso Abierto diamante  
Infraestructura abierta no comercial propiedad de la  
academia

Faruk Hernández-Sampayo, Pablo Salomón Montes-Arcón,  
Paola María Blanco-Pertuz, Gloria Catherine Pérez-Mingán

**Giant Submucosal Lipoma of the Right Colon  
Spontaneously Expelled Rectally: Case Report**  
**Lipoma gigante submucoso de colon derecho expulsado  
de manera espontánea por vía rectal: reporte de caso**

*Revista colombiana de Gastroenterología*  
vol. 38, núm. 4, p. 539 - 542, 2023  
Asociación Colombiana de Gastroenterología,  
**ISSN:** 0120-9957  
**ISSN-E:** 2500-7440

**DOI:** <https://doi.org/10.22516/25007440.998>