

Endoscopic Management of Sharp Force Injury in the Esophagus: Case Report

Juan Sebastián Pardo-Barbosa,^{1*} Lorena García-Agudelo,² Edgardo Sánchez-Gamboa.³

OPEN ACCESS

Citation:

Pardo-Barbosa JS, García-Agudelo L, Sánchez-Gamboa E. Endoscopic Management of Sharp Force Injury in the Esophagus: Case Report. *Revista Colomb. Gastroenterol.* 2024;39(1):94-98. <https://doi.org/10.22516/25007440.994>

¹ General Practitioner, Operating Room Physician, Hospital Regional de la Orinoquia. Yopal, Colombia.

² Specialist in Epidemiology, Hospital Regional de la Orinoquia. Yopal, Colombia.

³ Specialist in General Surgery and Gastroenterology, Hospital Regional de la Orinoquia. Yopal, Colombia.

*Correspondence: Juan Sebastián Pardo-Barbosa. juansebas_09@hotmail.com

Received: 03/03/2023

Accepted: 24/07/2023



Abstract

Introduction: Esophageal trauma is a challenge because it may go unnoticed. These injuries are associated with high morbidity and mortality due to the increased risk of local or systemic infections that progress to sepsis and, finally, death. **Objective:** To describe a case of endoscopic management of a sharp force injury in the esophagus, which was corrected with hemostatic clips. **Case description:** A 28-year-old male patient with no significant history was referred due to a penetrating injury caused by a sharp weapon in region I of the neck at the sternal fork level. He had imaging findings suggestive of pneumomediastinum, so we opted for an endoscopic intervention with the initial plan of placing a fully covered esophageal prosthesis. However, given the location of the lesion and other risk factors, endoscopic management with hemostatic clips was performed, the evolution of which was satisfactory, and the patient was discharged without any complications. **Conclusions:** Esophageal perforation due to trauma continues to be a clinical situation that requires a high index of suspicion, so all tools for early diagnosis must be exhausted. Systemic complications such as mediastinitis must be avoided, given the high morbidity and mortality with which it is associated. Besides, each patient must be individualized according to their hemodynamic stability to determine the most appropriate intervention and reduce hospital stay. Endoscopy is an excellent alternative.

Keywords

Esophagus, trauma, gastrointestinal endoscopies, clips.

INTRODUCTION

Located anterior to the spinal column within the posterior and superior mediastinum, the esophagus's positioning renders injuries from trauma an uncommon occurrence. Literature suggests an incidence rate of approximately 10%⁽¹⁾. The severity of these injuries is largely contingent upon the nature of the trauma and the involvement of adjacent critical structures such as major blood vessels, the airway, and the heart, with mortality rates ranging from 12% to 50% among patients presenting with any form of

fistula. These percentages can rise in instances of undiagnosed conditions^(1,2).

Diagnosing esophageal trauma presents a significant challenge due to the potential for injuries to remain unnoticed. When esophageal injuries lead to contamination of neighboring structures, they are associated with high rates of morbidity and mortality due to the risk of local or systemic infections, including mediastinitis. This condition can progress to sepsis, shock, and ultimately, death. Additionally, complications such as the development of abscesses, tracheoesophageal, or esophagocutaneous fis-

tulas necessitate complex surgical interventions at advanced stages⁽³⁾.

For any suspected case of esophageal injury, initiating antibiotic therapy and withholding oral intake are recommended to mitigate the high risk of mediastinitis. Surgical intervention serves as the primary management approach, supplemented by diagnostic imaging aids in patients without hemodynamic instability⁽⁴⁾.

Esophageal trauma is deemed a surgical emergency. However, management strategies have primarily been outlined through a limited number of retrospective studies and expert recommendations, including options such as exploratory surgery and endoscopy⁽⁵⁾. This context sets the stage for presenting a case study focused on the successful endoscopic management of a sharp force injury to the thoracic esophagus.

CASE PRESENTATION

We report on a 28-year-old male, employed in informal work, with no notable medical history, who was transferred to our emergency department from a lower complexity hospital. The patient presented with a sharp force injury to the face and neck, which had occurred two hours prior and resulted in significant bleeding.

Upon initial assessment at the originating center, the patient received primary care that included wound irrigation and suturing, fluid therapy, broad-spectrum antibiotics comprising clindamycin 600 mg and gentamicin 240 mg intravenously, and a single dose of tetanus toxoid administered intramuscularly.

Upon admission to our secondary care facility, the patient's vital signs were within normal ranges: blood pressure (BP) at 120/70 mm Hg, heart rate (HR) at 60 beats per minute (bpm), partial oxygen saturation (SpO₂) at 95%, and no signs of respiratory distress. The patient exhibited generalized pallor, weighed 75 kg, had a height of 173 cm, and a body mass index (BMI) of 25.1 kg/m². Physical examination revealed a sutured wound approximately 1 cm in length in region I of the neck at the sternal notch level, covered with a dressing without active bleeding, and a wound on the left temporal region with a dressing, showing signs of old bleeding, mild edema, and periorbital bruising. No subcutaneous emphysema was palpable, and no other significant findings were noted on examination.

An upper gastrointestinal endoscopy (UGIE) performed at a secondary institution revealed linear mirror-image wounds of 1 and 2 cm in length, located 25 cm from the dental arch, with an extrinsic perilesional hematoma. There was no clear evidence of a break in continuity, and the Z line and diaphragmatic pinch were observed at the same level without erosions. The preliminary diagnosis was a wound

in the upper third of the esophagus with no complications (**Figure 1**), and the patient was advised against oral intake.

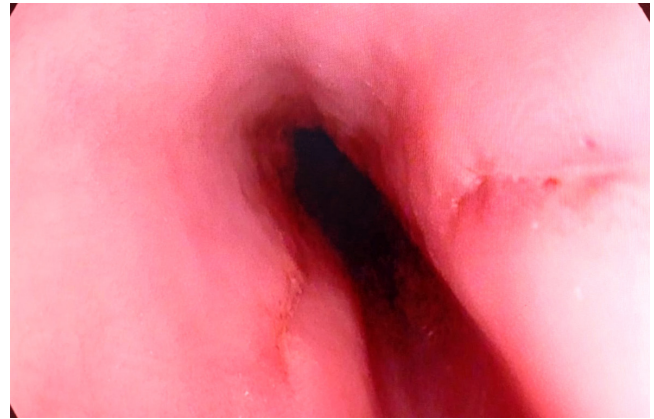


Figure 1. Linear mirror-image wounds of 1 and 2 cm in length. Courtesy of Dr. Edgardo Sánchez Gamboa.

The initial chest radiography was inconclusive, leading to further imaging with a contrast-enhanced neck CT scan. This imaging revealed the presence of air in the perivertebral, carotid, and retropharyngeal spaces, extending into the thoracic and posterior cervical regions (**Figure 2**). A contrast-enhanced chest CT scan confirmed a diagnosis of pneumomediastinum, indicated by a hypodense image consistent with air tracing from the neck through the visceral and prevertebral spaces and involving the mediastinum (**Figure 3**). A multidisciplinary team decided upon a repeat UGIE to attempt the placement of a fully covered self-expandable metal stent to avert the development of mediastinitis.

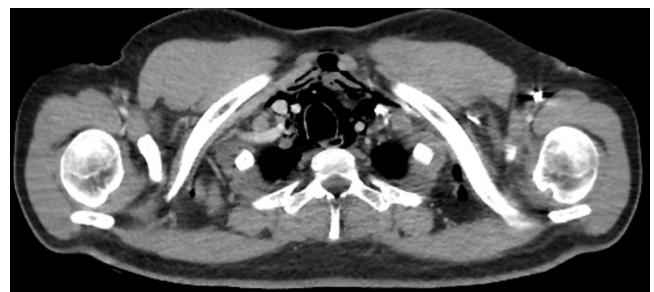

Figure 2. Neck CT scan with contrast, showing the presence of air in the perivertebral space with adjacent edema. Courtesy of Dr. Edgardo Sánchez Gamboa.

During the follow-up esophagoscopy, linear mirror-image wounds with well-defined edges, measuring 1 and 2 cm in length at 25 cm from the dental arch, were identified and approximated with two endoscopic clips each (**Figure 4**). A nasogastric feeding tube was placed under endoscopic guidance. The placement of a fully covered esophageal stent was

deemed inadvisable due to its proximity to the cricopharyngeal muscle and the associated high risk of stent migration.

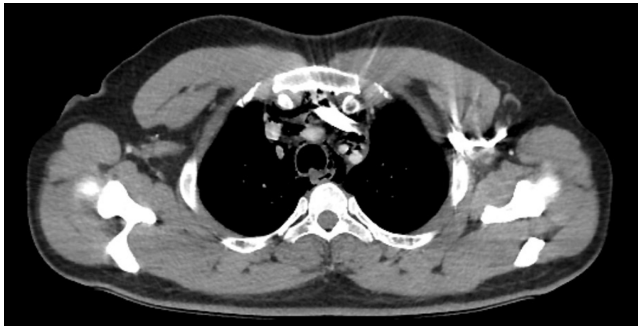


Figure 3. Chest CT scan with contrast, illustrating pneumomediastinum as evidenced by a hypodense air image in the visceral and prevertebral space. Courtesy of Dr. Edgardo Sánchez Gamboa.

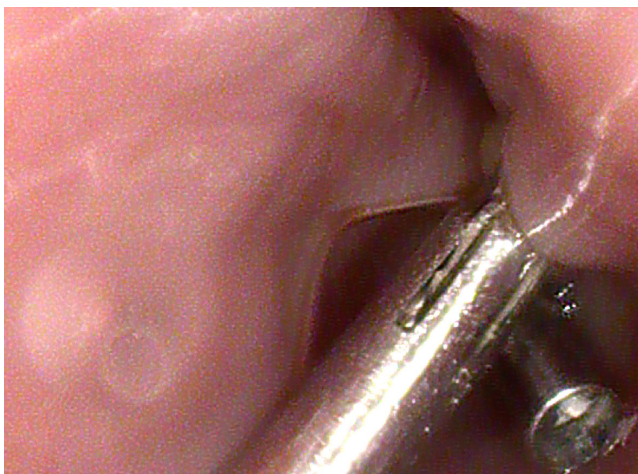


Figure 4. Linear mirror-image wounds approximated with double endoscopic clips. Courtesy of Dr. Edgardo Sánchez Gamboa.

On the seventh day following surgery, an esophagram was conducted to guide postoperative management strategies. This imaging study showed a satisfactory passage of contrast material through the esophagus into the stomach, without any indication of a tracheoesophageal fistula (**Figure 5**). Given the patient's swallowing difficulties, another UGIE was advised.

During the third UGIE, a healing wound was observed in the proximal esophagus. The patient subsequently recovered without any complications or difficulties swallowing, leading to his discharge from the hospital.

DISCUSSION

Esophageal trauma is acknowledged as a clinical condition linked to significant mortality. Hence, the essence of its management lies in the prompt identification and

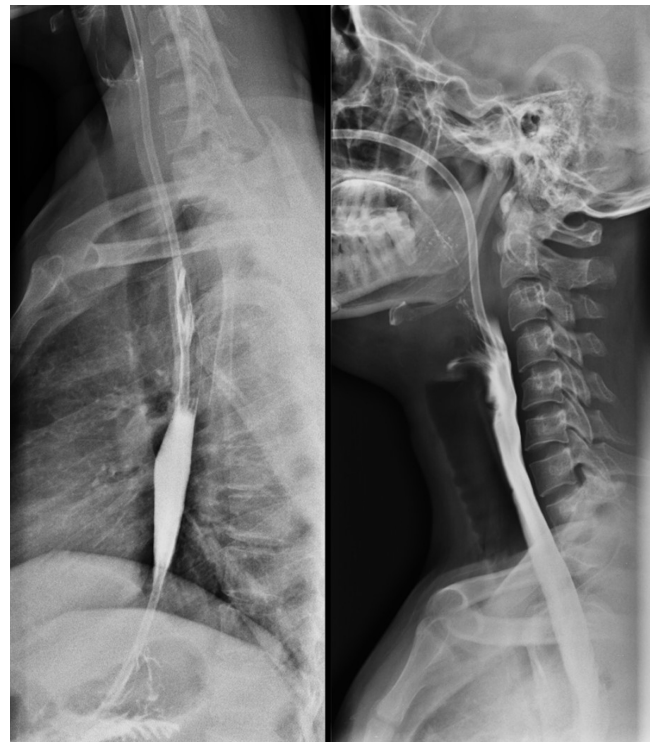


Figure 5. Esophagram demonstrating appropriate flow of contrast medium through the esophagus. Courtesy of Dr. Edgardo Sánchez Gamboa.

early intervention⁽⁶⁾. Surgical exploration is warranted for patients exhibiting hemodynamic instability, whereas stable patients might start with diagnostic imaging, such as plain chest radiography. This method is particularly useful for detecting free air within the mediastinum⁽⁷⁾. In our case, however, the initial chest radiograph did not provide conclusive results, prompting further assessment through UGIE, known for its 100% sensitivity in excluding injuries⁽⁸⁾. During the procedure, only a linear mirror-image wound was observed. There was no evident disruption of continuity, nor suspicion of mediastinal air, suggesting that withholding oral intake could be the most appropriate approach. Subsequent diagnostic evaluations, including contrast-enhanced CT scans of the chest and neck, confirmed the presence of pneumomediastinum. CT imaging has been documented as a valuable tool for identifying esophageal trauma and its associated local complications⁽⁹⁾, as the case we present.

Management strategies vary from conservative approaches, such as the cessation of oral intake, administration of broad-spectrum antibiotics, and radiological monitoring, to surgical interventions like esophagectomy. Situated between these conservative and surgical extremes is minimally invasive management via endoscopic

techniques, reserved for patients without local or systemic complications who are stable from a hemodynamic standpoint⁽¹⁰⁾. In this case report, the patient maintained hemodynamic stability without any signs of an inflammatory response or clinical decline. Thus, the possibility of an endoscopic approach involving the placement of a fully covered esophageal stent was contemplated as a therapeutic option. However, this strategy was ultimately not pursued due to concerns over bronchoaspiration and intolerance of the device, largely because of its proximity to the cricopharyngeal muscle and a high risk of stent migration—a complication observed in up to 34% of patients with fully covered stents⁽¹¹⁾.

Given the patient's clinical stability, the specific locations of the two esophageal wounds, their linear nature with well-defined edges, and to circumvent additional complications, the decision was made to apply endoscopic clips to approximate the traumatic wounds. This method has rarely been delineated in the context of esophageal perforation treatment. Case reports have documented the use of over-the-scope clips (OTSC) and hemostatic clips, achieving up to a 100% effectiveness in restoring continuity in instances of esophageal perforation among patients undergoing peroral endoscopic myotomy (POEM)⁽¹²⁾. In contrast to our investigation, where conventional hemostatic clips were employed for esophageal perforation closure, there is scant literature, even though recent years have seen the introduction of less invasive techniques for gastroesophageal tract repairs. This topic remains contentious due to the lack of standardization in clip usage, with the preference still leaning towards the insertion of fully covered stents as the initial treatment choice⁽¹³⁾.

It is pertinent to mention that the European Society of Gastrointestinal Endoscopy supports the deployment of clips for sealing perforations of up to 2 cm⁽¹⁴⁾. Our study aligns with the criteria for such intervention, deemed an appropriate approach in patients exhibiting hemodynamic stability. Furthermore, there is a noted case of successful esophageal fistula correction using endoscopic clips in a patient suffering from esophageal trauma due to a foreign

body. Follow-up examination revealed total resolution of the leakage⁽¹⁵⁾, reinforcing the potential of endoscopic clips as a viable emergency alternative for managing traumatic esophageal perforations.

CONCLUSION

Digestive endoscopy offers a minimally invasive therapeutic avenue, which results in decreased hospitalization duration, reduction in work-related leaves, lowered risk of systemic complications such as mediastinitis, and diminished pain from more invasive surgical techniques. At present, various strategies exist for the treatment of esophageal trauma, dependent on the patient's hemodynamic condition, and the wound's location, shape, and size, necessitating personalized treatment plans for each patient.

Conflict of Interest

The authors affirm that they have no conflicts of interest.

Funding Sources

This study did not receive any financial support.

Author Contributions

The research project was planned and developed by LGA, JSPB, ESG; LGA and JSPB were responsible for the design and data gathering; LGA, JSPB, ESG analyzed the clinical case; manuscript preparation for the dissemination of new knowledge to the scientific community was undertaken by LGA, JSPB, ESG; the final manuscript was reviewed and approved by LGA, JSPB, ESG.

Acknowledgments

The authors extend their gratitude to the Department of Gastroenterology and Endoscopy at Hospital Regional de la Orinoquía for their support.

REFERENCES

1. Mubang RN, Sigmon DF, Stawicki SP. Esophageal Trauma. 2023 Jul 25. In: StatPearls [Internet]. Treasure Island (FL): StatPearls Publishing; 2024.
2. Anderloni A, Genco C, Massidda M, Di Leo M, Fumagalli UR, Rosati R, et al. Self-Expanding Metal Stents for the Treatment of Post-Surgical Esophageal Leaks: A Tertiary Referral Center Experience. *Dig Surg*. 2019;36(4):309-316. <https://doi.org/10.1159/000489817>
3. Millán M, Parra M, Sánchez-Restrepo B, Caicedo Y, Serna C, González-Hadad A, et al. Primary repair: damage control surgery in esophageal trauma. *Colomb Med (Cali)*. 2021;52(2):e4094806. <https://doi.org/10.25100/cm.v52i2.4806>

4. Reyes-Carrillo A, Villela-Cañas E, Padilla-López J, Enríquez-Sánchez LB, Carrillo-Gorena MJ, Carbajal-Vega MA, et al. Manejo de lesión traqueoesofágica completa con anastomosis esofágica y traqueal terminoterminal más esofagostomía con colocación de sonda en T. *Rev Hosp Jua Mex.* 2020;87(4):188-192.
<https://doi.org/10.24875/RHJM.20000083>
5. Nieto K, Luna J, Palacios N, Barrera E, Mares A. Manejo quirúrgico de perforación esofágica. *Interciencia Méd.* 2022;12(1):59-63.
<https://doi.org/10.56838/icmed.v12i1.85>
6. Petrone P, Kassimi K, Jiménez-Gómez M, Betancourt A, Axelrad A, Marini CP. Management of esophageal injuries secondary to trauma. *Injury.* 2017;48(8):1735-1742.
<https://doi.org/10.1016/j.injury.2017.06.012>
7. De Lusong MAA, Timbol ABG, Tuazon DJS. Management of esophageal caustic injury. *World J Gastrointest Pharmacol Ther.* 2017;8(2):90-98.
<https://doi.org/10.4292/wjgpt.v8.i2.90>
8. Sudarshan M, Cassivi SD. Management of traumatic esophageal injuries. *J Thorac Dis.* 2019;11(Suppl 2):S172-S176.
<https://doi.org/10.21037/jtd.2018.10.86>
9. Liguori C, Gagliardi N, Saturnino PP, Pinto A, Romano L. Multidetector Computed Tomography of Pharyngo-Esophageal Perforations. *Semin Ultrasound CT MR.* 2016;37(1):10-15.
<https://doi.org/10.1053/j.sult.2015.10.005>
10. Gurwara S, Clayton S. Esophageal Perforations: An Endoscopic Approach to Management. *Curr Gastroenterol Rep.* 2019;21(11):57.
<https://doi.org/10.1007/s11894-019-0730-5>
11. Vanbiervliet G, Filippi J, Karimjee BS, Venissac N, Iannelli A, Rahili A, et al. The role of clips in preventing migration of fully covered metallic esophageal stents: a pilot comparative study. *Surg Endosc.* 2012;26(1):53-59.
<https://doi.org/10.1007/s00464-011-1827-6>
12. Saxena P, Chavez YH, Kord Valeshabad A, Kalloo AN, Khashab MA. An alternative method for mucosal flap closure during peroral endoscopic myotomy using an over-the-scope clipping device. *Endoscopy.* 2013;45(7):579-581.
<https://doi.org/10.1055/s-0032-1326398>
13. Lee JH, Kedia P, Stavropoulos SN, Carr-Locke D. AGA Clinical Practice Update on Endoscopic Management of Perforations in Gastrointestinal Tract: Expert Review. *Clin Gastroenterol Hepatol.* 2021;19(11):2252-2261.e2.
<https://doi.org/10.1016/j.cgh.2021.06.045>
14. Chen S, Shapira-Galitz Y, Garber D, Amin MR. Management of Iatrogenic Cervical Esophageal Perforations: A Narrative Review. *JAMA Otolaryngol Head Neck Surg.* 2020;146(5):488-494.
<https://doi.org/10.1001/jamaoto.2020.0088>
15. Mezzetto L, Treppiedi E, Scorsone L, Giacomuzzi S, Perandini S, Macri M, et al. Thoracic Aortic Pseudoaneurysm after Esophageal Perforation and Mediastinitis Caused by Accidental Ingestion of a Mutton Bone: A Case Report on Staged Endoscopic and Endovascular Treatments. *Ann Vasc Surg.* 2016;30:307.e15-9.
<https://doi.org/10.1016/j.avsg.2015.07.025>



Available in:

<https://www.redalyc.org/articulo.oa?id=337782277016>

How to cite

Complete issue

More information about this article

Journal's webpage in redalyc.org

Scientific Information System Redalyc
Diamond Open Access scientific journal network
Non-commercial open infrastructure owned by academia

Juan Sebastián Pardo-Barbosa, Lorena García-Agudelo,
Edgardo Sánchez-Gamboa

**Endoscopic Management of Sharp Force Injury in the
Esophagus: Case Report**

**Manejo endoscópico de herida por arma cortopunzante
en el esófago: reporte de caso**

Revista colombiana de Gastroenterología

vol. 39, no. 1, p. 94 - 98, 2024

Asociación Colombiana de Gastroenterología,

ISSN: 0120-9957

ISSN-E: 2500-7440

DOI: <https://doi.org/10.22516/25007440.1041>