

Case Report of Intrahepatic Cholestasis Associated with ATP8B1 Gene Mutation in a Patient with Human Immunodeficiency Virus (HIV) Infection: A Diagnostic Challenge

Darwin Jhoan Ariza-Rodríguez,¹  Valentina Dávila,^{1*}  Carmen Yanette Suárez-Quintero,²  Sandra Amado-Garzón.¹ 

OPEN ACCESS

Citation:

Ariza-Rodríguez DJ, Dávila V, Suárez-Quintero CY, Amado-Garzón S. Case Report of Intrahepatic Cholestasis Associated with ATP8B1 Gene Mutation in a Patient with Human Immunodeficiency Virus (HIV) Infection: A Diagnostic Challenge. *Revista. colomb. Gastroenterol.* 2024;39(3):323-327. <https://doi.org/10.22516/25007440.1120>

¹ Specialist in Internal Medicine, Internist, Hospital Universitario San Ignacio. Bogotá, Colombia.

² Specialist in Internal Medicine, Gastroenterology, and Clinical Hepatology. Gastroenterologist, Hospital Universitario San Ignacio. Bogotá, Colombia.

*Correspondence: Valentina Dávila.
v.davila@javeriana.edu.co

Received: 25/07/2023

Accepted: 24/11/2023



Abstract

Benign recurrent intrahepatic cholestasis (BRIC) is a rare condition that is part of a spectrum of disorders known as familial intrahepatic cholestasis. It is characterized by episodes of cholestasis lasting weeks to months with complete resolution between episodes. BRIC is associated with a good prognosis compared to other conditions, due to its later onset and lower association with fibrosis. Diagnosis is one of exclusion, posing a diagnostic challenge that requires a high index of suspicion and is confirmed by identifying the ATP8B1 gene mutation.

This report presents the case of a patient with human immunodeficiency virus (HIV) who developed severe intrahepatic cholestasis and had a history of recurrent jaundice throughout his life. After extensive studies of intrahepatic cholestasis, he was diagnosed with symptomatic BRIC with the ATP8B1 gene mutation.

Keywords

Jaundice, intrahepatic cholestasis, mutation.

INTRODUCTION

Familial intrahepatic cholestasis is a group of heterogeneous disorders characterized by impaired bile secretion by hepatocytes due to mutations in genes encoding proteins expressed on the apical membrane of hepatocytes. These disorders include progressive familial intrahepatic cholestasis (PFIC) and benign recurrent intrahepatic cholestasis (BRIC). PFIC has four types, and BRIC has two types, each distinguished by the specific gene mutation involved, the age of onset of cholestatic manifestations, prognosis,

and risk of progression to cirrhosis or hepatocellular carcinoma^(1,2).

PFIC has an incidence of approximately one in 50,000 to one in 100,000 individuals per year^(3,4) and is marked by persistent early-onset cholestasis that advances to cirrhosis and end-stage liver disease in childhood⁽⁵⁾. BRIC, on the other hand, is characterized by episodes of cholestasis lasting from weeks to months, followed by complete resolution between episodes^(6,7). It has a favorable prognosis and, unlike PFIC, typically presents at later ages and usually does not progress to fibrosis⁽⁸⁾. However, there have been

reports of BRIC progressing to PFIC, suggesting that both conditions are part of a spectrum^(9,10).

The ATP8B1 gene mutation, located on chromosome 18q21, is responsible for causing both PFIC type 1 and BRIC type 1⁽¹¹⁾. The ATP8B1 gene encodes the FIC1 protein, a P-type adenosine triphosphatase (ATPase) located on the canalicular membrane and cholangiocytes. This protein functions by coupling ATP hydrolysis to the translocation of aminophospholipids, thereby maintaining phospholipid asymmetry across membranes, including the bile canalicular membrane. Its defect disrupts membrane structure and associated membrane proteins, such as the bile salt export pump⁽¹²⁾.

This case report presents a clinical instance of BRIC in a 63-year-old patient with a history of human immunodeficiency virus (HIV) infection, experiencing recurrent episodes of intrahepatic cholestasis. After an extensive evaluation ruling out other causes, the diagnosis was reached.

CLINICAL CASE

The patient is a 63-year-old male with a 20-year history of HIV infection, managed with dolutegravir and emtricitabine/tenofovir, showing good adherence and immunovirological control. He presented with a two-month history of jaundice that began on the chest and subsequently became generalized, accompanied by asthenia, adynamia, generalized nocturnal pruritus, acholia, dark urine, and an unintentional weight loss of 5 kg over the past two months. Systemic review revealed recurrent episodes of jaundice since he was 18 years old and a family history of two brothers with similar symptoms.

On physical examination, generalized jaundice was noted, with no other significant findings. Admission laboratory tests indicated elevated alkaline phosphatase, transaminase levels two to four times the upper limit, marked hyperbilirubinemia with a predominance of direct bilirubin, hypoalbuminemia, and a prolonged international normalized ratio (INR) (**Table 1**). Baseline laboratory tests from two months prior had been normal. A hepatobiliary ultrasound showed no dilatation of the extrahepatic bile duct or choledocholithiasis. Given the severe cholestasis, further imaging with magnetic resonance cholangiography was performed, which also showed no obstructions. Additional tests were conducted to rule out infectious hepatitis (hepatitis B surface antigen [HBsAg], hepatitis B core antigen [HBcAg], hepatitis C antibodies [anti-HCV], cytomegalovirus [CMV], Epstein-Barr virus [EBV], rapid plasma reagin [RPR], and HIV), all of which were negative, as well as autoimmune disease markers (antinuclear antibodies [ANA], anti-mitochondrial antibodies [AMA], and anti-smooth muscle antibodies [ASMA], all negative). A consultation with infectious disease specialists considered the possibility of antiretroviral therapy (ART)-associated hepatotoxicity, but this was ruled out due to the lack of improvement following medication discontinuation and the history of jaundice episodes predating ART initiation.

A percutaneous liver biopsy was performed, revealing severe, predominantly intracanalicular cholestasis located pericentrally (soft cholestasis), with mild portal inflammation, and no evidence of necroinflammatory disease or autoimmune hepatitis. This finding suggested a cholestasis of possible genetic origin, which was confirmed by the detection of an ATP8B1 gene mutation.

Table 1. Relevant Laboratory Findings

Laboratory Tests	Admission	Follow-Up	Reference Range
Alkaline phosphatase	506 U/L	250 U/L	30-120 U/L
Total bilirubin	42.9 mg/dL	1.4 mg/dL	0.3-1 mg/dL
Direct bilirubin	26.2 mg/dL	0.8 mg/dL	0-0.2 mg/dL
Indirect bilirubin	16.7 mg/dL	0.6 mg/dL	0-1.1 mg/dL
GGT	168 U/L	113 U/L	12-73 U/L
Albumin	3.0 g/dL	4.3 mg/dL	4.2-5.5 g/dL
AST	124 U/L	51 U/L	0-50 U/L
ALT	70 U/L	38 U/L	0-50 U/L
INR	2.33	1.6	0.8-1.2

ALT: alanine aminotransferase; AST: aspartate aminotransferase; GGT: γ -glutamyltransferase; INR: international normalized ratio. Author's own research.

Given the clinical presentation and absence of cirrhosis, a diagnosis of benign recurrent intrahepatic cholestasis (BRIC) was established. The patient received symptomatic treatment for pruritus with topical betamethasone and loratadine, as well as ursodeoxycholic acid at a dose of 1,200 mg/day. At a follow-up 20 months later, marked reduction in bilirubin levels was observed (**Figure 1**), along with normalization of other liver function tests.

DISCUSSION

Intrahepatic cholestasis is characterized by impaired bile production and excretion, leading to accumulation of bile pigments in the skin, sclerae, and mucous membranes, resulting in jaundice and pruritus⁽³⁾. A group of autosomal recessive familial disorders exhibit intrahepatic cholestasis, with ATP8B gene mutations implicated in their pathogenesis.

This report presents a case of BRIC in a patient whose diagnostic challenge stemmed from other possible causes of liver profile abnormalities due to a history of HIV infection and the use of antiretroviral drugs associated with hepatotoxicity. This is the first reported case of BRIC in a patient with HIV.

BRIC typically manifests at later ages (in contrast to PFIC, which begins in childhood), presents with recurrent

jaundice episodes, and follows a benign course without fibrosis; however, there is a risk of progression to PFIC. **Table 2** provides a comparative overview of these two conditions. In this case, liver biopsy showed no fibrosis but did reveal severe, predominantly intracanalicular cholestasis with mild portal inflammation, characteristic of BRIC⁽¹³⁾.

The distinctive laboratory characteristics of cholestatic episodes in patients with BRIC1, BRIC2, PFIC1, and PFIC2 include elevated total and direct bilirubin, normal or slightly elevated serum γ -glutamyltransferase (GGT) (in PFIC3, GGT is markedly elevated), elevated alkaline phosphatase, and ALT and AST levels that are normal or moderately elevated⁽⁶⁾.

In the presented case, although the GGT level was elevated, it showed only a minimal increase, less than twice the upper limit of normal. A review by Velimir and colleagues reported a BRIC patient with minimal GGT elevation⁽¹³⁾.

The diagnosis of BRIC is based on the diagnostic criteria proposed by Luketic and Shiffman⁽¹³⁾, which include at least two jaundice episodes separated by intervals ranging from weeks to years without any symptoms, laboratory findings consistent with intrahepatic cholestasis, normal or minimally elevated GGT, severe pruritus due to cholestasis, histology showing centrilobular cholestasis, normal intra- and extrahepatic bile ducts on cholangiography, and the

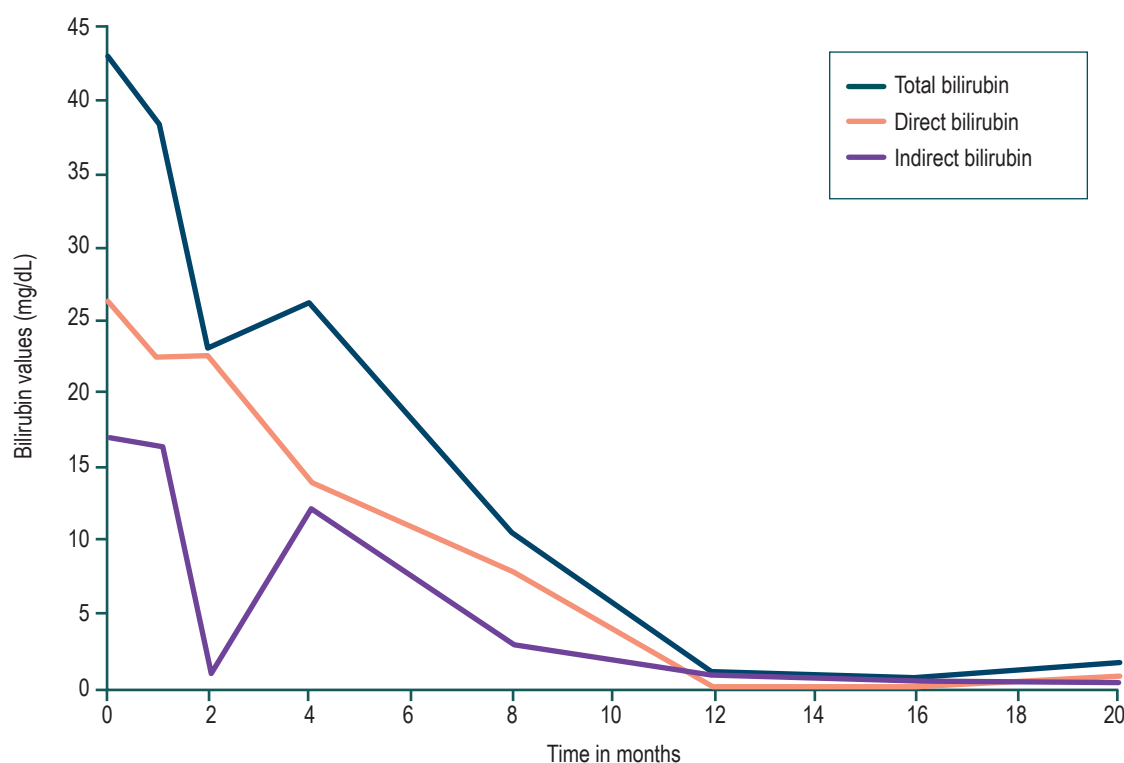


Figure 1. Bilirubin levels over time. Author's own research.

Table 2. Comparison between Progressive Familial Intrahepatic Cholestasis (PFIC) and Benign Recurrent Intrahepatic Cholestasis (BRIC)

Characteristics	PFIC	BRIC
Condition type	Progressive	Recurrent
Severity	Progression to fibrosis	Lower risk of fibrosis
Symptoms	Intense pruritus, jaundice, liver failure	Jaundice, milder pruritus
Age of onset	Childhood	Early adulthood or adolescence
Genetic mutations	ATP8B1, ABCB11, ABCB4, TJP2	ATP8B1, ABCB11
Treatment response	May require liver transplant	Medical management; symptoms may improve over time

Author’s own research.

exclusion of other causes of cholestasis, such as extrahepatic cholestasis, primary biliary cirrhosis, primary sclerosing cholangitis, viral or toxic hepatitis, infiltrative diseases, and malignancy. As mentioned, the diagnosis is confirmed by identifying an ATP8B1 gene mutation⁽⁶⁾.

Management of the disease is symptomatic, aimed at pruritus control. Various medications have been tried, including ursodeoxycholic acid, cholestyramine, rifampicin, and antihistamines, providing symptomatic relief but with no effect on preventing recurrent jaundice episodes⁽¹⁴⁾.

The diagnosis of BRIC1 is by exclusion and confirmed through genetic testing. In our patient, other causes of cholestasis and liver dysfunction were reasonably ruled out, and a history of similar episodes since age 18 led to the expansion of diagnostic testing to include genetic causes. High clinical suspicion and careful discernment are required, as in this case, particularly due to the concurrent use of medications with a high risk of hepatotoxicity.

CONCLUSION

Familial intrahepatic cholestasis is a heterogeneous group of rare disorders characterized by persistent or recurrent

cholestasis due to mutations in genes involved in bile excretion. Depending on the type, these disorders may progress to cirrhosis or follow a benign course. A high index of suspicion is important for diagnosis, and this condition should be considered in the differential diagnosis of cholestatic liver diseases.

Ethical Considerations

This study was submitted to the research and ethics committee of Hospital San Ignacio and Pontificia Universidad Javeriana, in compliance with current research regulations and with the patient’s informed consent. The authors declare there is no personal information that could identify the patient.

Funding Sources

This work did not receive any funding.

Conflict of Interest

The authors declare no conflict of interest.

REFERENCES

1. Halawi A, Ibrahim N, Bitar R. Triggers of benign recurrent intrahepatic cholestasis and its pathophysiology: a review of literature. *Acta Gastroenterol Belg.* 2021;84(3):477-86. <https://doi.org/10.51821/84.3.013>

2. van der Woerd WL, van Mil SWC, Stapelbroek JM, Klomp LWJ, van de Graaf SEJ, Houwen RHJ. Familial cholestasis: Progressive familial intrahepatic cholestasis, benign recurrent intrahepatic cholestasis and intrahepatic cholestasis of pregnancy. *Best Pract Res Clin Gastroenterol.* 2010;24(5):541-53. <https://doi.org/10.1016/j.bpg.2010.07.010>

3. Gunaydin M, Bozkurter Cil AT. Progressive familial intrahepatic cholestasis: diagnosis, management, and treatment.

- Hepat Med. 2018;10:95-104.
<https://doi.org/10.2147/HMER.S137209>
4. Felzen A, Verkade HJ. The spectrum of Progressive Familial Intrahepatic Cholestasis diseases: Update on pathophysiology and emerging treatments. *Eur J Med Genet*. 2021;64(11):104317.
<https://doi.org/10.1016/j.ejmg.2021.104317>
 5. van Wessel DBE, Thompson RJ, Gonzales E, Jankowska I, Shneider BL, Sokal E, et al. Impact of Genotype, Serum Bile Acids, and Surgical Biliary Diversion on Native Liver Survival in FIC1 Deficiency. *Hepatology*. 2021;74(2):892-906.
<https://doi.org/10.1002/hep.31787>
 6. Folvik G, Hilde O, Helge GO. Benign recurrent intrahepatic cholestasis: review and long-term follow-up of five cases. *Scand J Gastroenterol*. 2012;47(4):482-8.
<https://doi.org/10.3109/00365521.2011.650191>
 7. De Vloo C, Nevens F. Cholestatic pruritus: an update. *Acta Gastroenterol Belg*. 2019;82(1):75-82.
 8. Van Berge Henegouwen GP. Benign recurrent intrahepatic cholestasis and Byler's disease: one gene, two diseases? *J Hepatol*. 1996;25(3):395-7.
[https://doi.org/10.1016/S0168-8278\(96\)80128-0](https://doi.org/10.1016/S0168-8278(96)80128-0)
 9. van Ooteghem NAM, Klomp LWJ, van Berge-Henegouwen GP, Houwen RHJ. Benign recurrent intrahepatic cholestasis progressing to progressive familial intrahepatic cholestasis: low GGT cholestasis is a clinical continuum. *J Hepatol*. 2002;36(3):439-43.
[https://doi.org/10.1016/S0168-8278\(01\)00299-9](https://doi.org/10.1016/S0168-8278(01)00299-9)
 10. van Mil SW, Klomp LW, Bull LN, Houwen RH. FIC1 Disease: A Spectrum of Intrahepatic Cholestatic Disorders. *Semin Liver Dis*. 2001;21(04):535-44.
<https://doi.org/10.1055/s-2001-19034>
 11. Amirneni S, Haep N, Gad MA, Soto-Gutierrez A, Squires JE, Florentino RM. Molecular overview of progressive familial intrahepatic cholestasis. *World J Gastroenterol*. 2020;26(47):7470-84.
<https://doi.org/10.3748/wjg.v26.i47.7470>
 12. Andersen JP, Vestergaard AL, Mikkelsen SA, Mogensen LS, Chalat M, Molday RS. P4-ATPases as Phospholipid Flippases-Structure, Function, and Enigmas. *Front Physiol*. 2016;7:275.
<https://doi.org/10.3389/fphys.2016.00275>
 13. Luketic VA, Shiffman ML. Benign recurrent intrahepatic cholestasis. *Clin Liver Dis*. 2004;8(1):133-149.
[https://doi.org/10.1016/S1089-3261\(03\)00133-8](https://doi.org/10.1016/S1089-3261(03)00133-8)
 14. Crosigani A, Podda M, Bertolini E, Battezzati PM, Zuin M, Setchell KDR. Failure of ursodeoxycholic acid to prevent a cholestatic episode in a patient with benign recurrent intrahepatic cholestasis: A study of bile acid metabolism. *Hepatology*. 1991;13(6):1076-83.
<https://doi.org/10.1002/hep.1840130612>



Available in:

<https://www.redalyc.org/articulo.oa?id=337782279012>

How to cite

Complete issue

More information about this article

Journal's webpage in redalyc.org

Scientific Information System Redalyc
Diamond Open Access scientific journal network
Non-commercial open infrastructure owned by academia

Darwin Jhoan Ariza-Rodríguez,, Valentina Dávila,
Carmen Yanette Suárez-Quintero, Sandra Amado-Garzón
**Case Report of Intrahepatic Cholestasis Associated with
ATP8B1 Gene Mutation in a Patient with Human
Immunodeficiency Virus (HIV) Infection: A Diagnostic
Challenge**
**Reporte de caso de colestasis intrahepática asociada a
mutación del gen ATP8B1 en un paciente con infección
por virus de la inmunodeficiencia humana (VIH): un reto
diagnóstico**

Revista colombiana de Gastroenterología
vol. 39, no. 3, p. 323 - 327, 2024
Asociación Colombiana de Gastroenterología,
ISSN: 0120-9957
ISSN-E: 2500-7440

DOI: <https://doi.org/10.22516/25007440.1120>