

Blue Rubber Bleb Nevus Syndrome in the Colon, Tongue, and Supraglottic Region: Case Report

Fabián Eduardo Puentes-Manosalva,¹  Rubén Darío Londoño-López,^{2*}  Andrés Sánchez-Gil,¹  Lázaro Antonio Arango-Molano.³ 

OPEN ACCESS

Citation:

Puentes-Manosalva FE, Londoño-López RD, Sánchez-Gil A, Arango-Molano LA. Blue Rubber Bleb Nevus Syndrome in the Colon, Tongue, and Supraglottic Region: Case Report. *Revista Colomb. Gastroenterol.* 2024;39(3):337-343. <https://doi.org/10.22516/25007440.1113>

¹ Specialist in General Surgery, Subspecialist in Clinical-Surgical Gastroenterology. Professor in the Clinical-Surgical Gastroenterology Program, Universidad de Caldas. Manizales, Colombia.

² Specialist in General Surgery, Clinical-Surgical Gastroenterology Fellow, Universidad de Caldas. Manizales, Colombia.

³ Specialist in General Surgery, Subspecialist in Clinical-Surgical Gastroenterology, Head of the Clinical-Surgical Gastroenterology Program, Universidad de Caldas. Manizales, Colombia.

*Correspondence: Rubén Darío Londoño-López.
rudamed78@yahoo.es

Received: 24/07/2023
Accepted: 25/08/2023



Abstract

Blue Rubber Bleb Nevus Syndrome (BRBNS) is an extremely rare and likely hereditary condition characterized by the presence of numerous hemangiomatous lesions that are purplish, raised, and elastic, primarily affecting the skin and the digestive system. These lesions become prominent and rubbery to the touch. BRBNS can also affect other organs. Clinically, it may be asymptomatic or present with painful skin lesions, hyperhidrosis, abdominal pain, gastrointestinal bleeding, anemia, and hematuria, among other signs and symptoms. Treatment options include conservative management, pharmacological intervention, endoscopic procedures, or surgery. This report presents the clinical case of a 22-year-old woman with a history of BRBNS affecting the skin and lips but with no gastrointestinal symptoms. She is under dermatological follow-up and management. The patient was seen on an outpatient basis at the endoscopy unit of Unión de Cirujanos S.A.S. in Manizales, Colombia, at the Clinical-Surgical Gastroenterology Service of the Universidad de Caldas. An upper digestive endoscopy (EVDA) and ileocolonoscopy were performed to rule out the presence of similar lesions in the gastrointestinal tract. The EVDA revealed vascular, raised, rubbery lesions at the base of the tongue and in the supraglottic region, with no involvement of the esophagus, stomach, or duodenum. The ileocolonoscopy showed multiple vascular, raised lesions in the cecum, transverse colon, and descending colon.

Keywords

Blue Rubber Bleb Nevus Syndrome, colon, tongue, glottis.

INTRODUCTION

Blue rubber bleb nevus syndrome (BRBNS) is characterized by the formation of multiple vascular malformations and hemangiomas that can affect various organs, particularly the skin and gastrointestinal tract⁽¹⁾. Although gastrointestinal BRBNS is the second most commonly affected site after the skin, it is rare, with the small intestine being the most frequently involved area, followed by the colon. It can present with gastrointestinal bleeding and anemia. BRBNS is usually diagnosed at birth or during childhood; however,

it may also be identified in adulthood and can even present without cutaneous manifestations^(1,2). Other possible sites of involvement include the central nervous system (CNS), eyes, thyroid, kidneys, spleen, and extremities⁽²⁾.

CLINICAL CASE

The patient is a 22-year-old woman with a history of blue rubber bleb nevus syndrome (BRBNS) affecting the skin throughout her body, including her lips (**Figure 1**). She was under dermatological follow-up without gastrointes-

tinal symptoms and was referred as an outpatient to the endoscopy unit at Unión de Cirujanos S.A.S. in Manizales, Colombia, part of the Clinical-Surgical Gastroenterology Service at the Universidad de Caldas, for an upper gastrointestinal endoscopy and colonoscopy to rule out similar lesions in the gastrointestinal tract.

Upper gastrointestinal endoscopy revealed BRBNS manifested as vascular lesions with a raised, nodular appearance, approximately 15 mm in size, at the base of the tongue (**Figure 2**) and in the supraglottic region (**Figure 3**), which restricted the mobility of the vocal folds. No lesions were observed in the esophagus, stomach, or duodenum.

Ileocolonoscopy demonstrated BRBNS with multiple vascular, nodular lesions measuring between three and five mm in the cecum (**Figure 4**), transverse colon, and descending colon (**Figure 5**). No lesions were observed in

the remaining segments examined, including 15 cm of the distal ileum.

The patient is currently under clinical follow-up with dermatology, gastroenterology, and otolaryngology services.

DISCUSSION

Blue rubber bleb nevus syndrome (BRBNS) was first described by Gascoyen in 1860. However, William Bennett Bean later named the disease in 1958, and it is thus also referred to as *Bean syndrome*. BRBNS is an extremely rare and potentially hereditary condition, with an estimated incidence of 1 in 14,000 live births and only about 200 cases reported globally^(2,4-6). This syndrome is characterized by numerous hemangiomatous, violaceous, raised, and elastic lesions, primarily affecting the skin and digestive system.

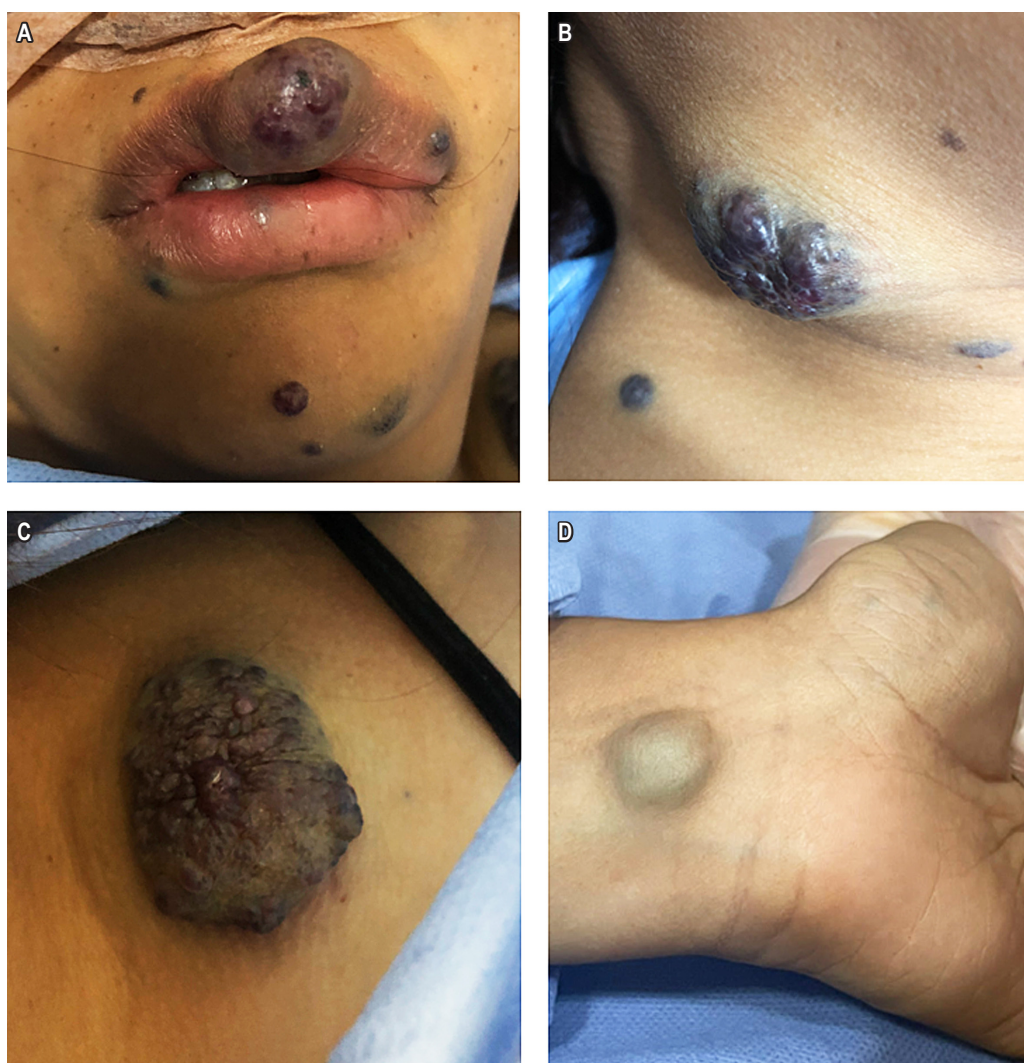

Figure 1. BRBNS in the lip and skin. **A.** Upper lip and facial area. **B.** Neck. **C.** Chest. **D.** Wrist. Images from the files of Unión de Cirujanos S.A.S., Manizales, Colombia, Clinical-Surgical Gastroenterology Service, Universidad de Caldas.

These lesions are notable for their prominent, rubbery texture; they empty upon compression and rapidly refill once pressure is released, a key diagnostic sign^(1,3,4). Most cases are sporadic, although mutations in the TEK gene have been found to cause BRBNS with an autosomal dominant inheritance pattern linked to chromosome 9p, with a male predominance in a 2:1 ratio^(2,4).

Skin lesions commonly allow for diagnosis during childhood, with only 4% of cases identified in adulthood; some cases have even been diagnosed in patients over 80 years old^(2,3). After the skin, the gastrointestinal tract is the

second most affected region, primarily involving the small intestine, followed by the colon. However, lesions can appear in various locations from the tongue to the anus. BRBNS lesions may also affect other organs, including the central nervous system (CNS), eyes, thyroid, nasopharynx, larynx, trachea, lungs, pleura, heart, liver, pancreas, kidneys, spleen, peritoneum, urinary tract, skeletal muscle, and joints, among others⁽¹⁻⁸⁾.

BRBNS is classified into three types: type 1 presents as a large, deforming cavernous angioma that may obstruct vital tissue; type 2, the most common, appears as a “blue rub-

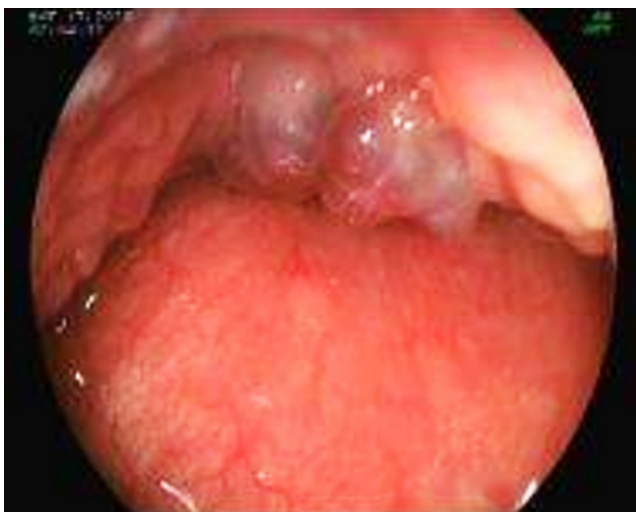

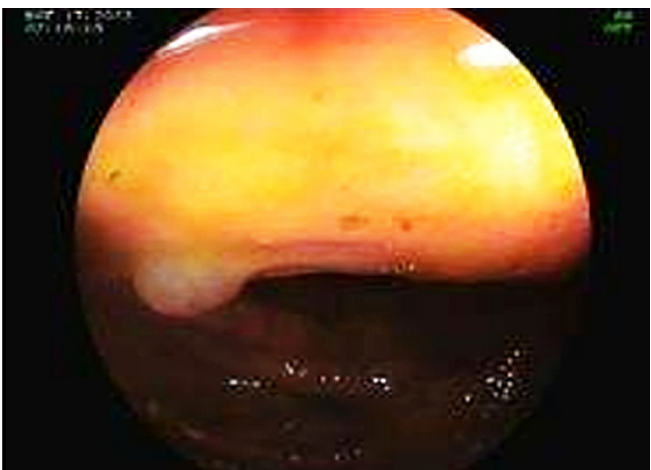
Figure 2. BRBNS at the base of the tongue. Image courtesy of Dr. Fabián Eduardo Puentes Manosalva, Unión de Cirujanos S.A.S., Manizales, Colombia, Clinical-Surgical Gastroenterology Service, Universidad de Caldas.

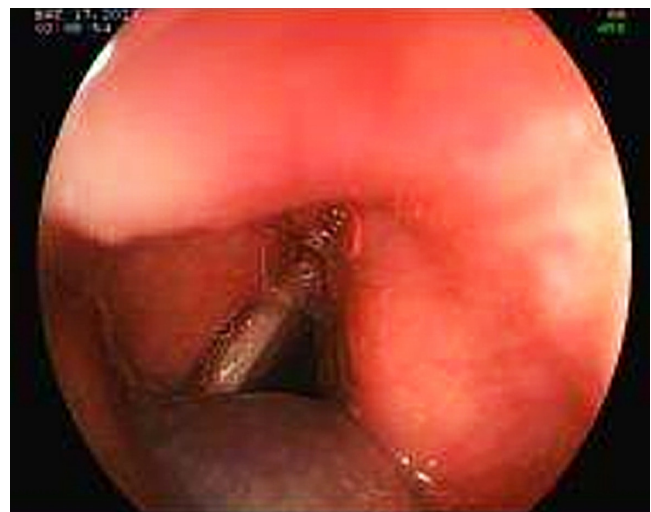

Figure 3. BRBNS in the supraglottic region. Image courtesy of Dr. Fabián Eduardo Puentes Manosalva, Unión de Cirujanos S.A.S., Manizales, Colombia, Clinical-Surgical Gastroenterology Service, Universidad de Caldas.

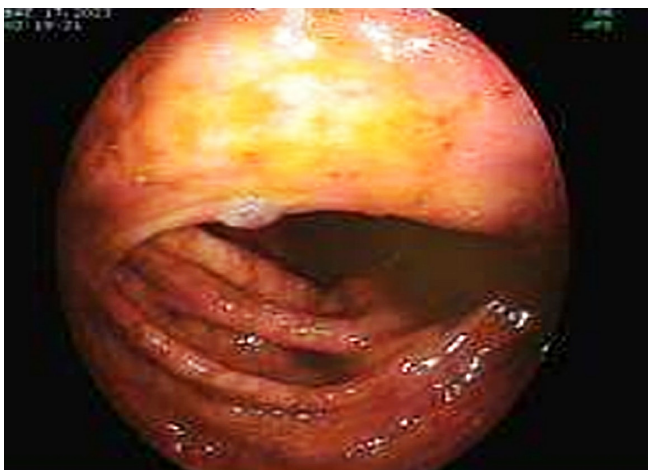

Figure 4. BRBNS in the cecum. Image courtesy of Dr. Fabián Eduardo Puentes Manosalva, Unión de Cirujanos S.A.S., Manizales, Colombia, Clinical-Surgical Gastroenterology Service, Universidad de Caldas.



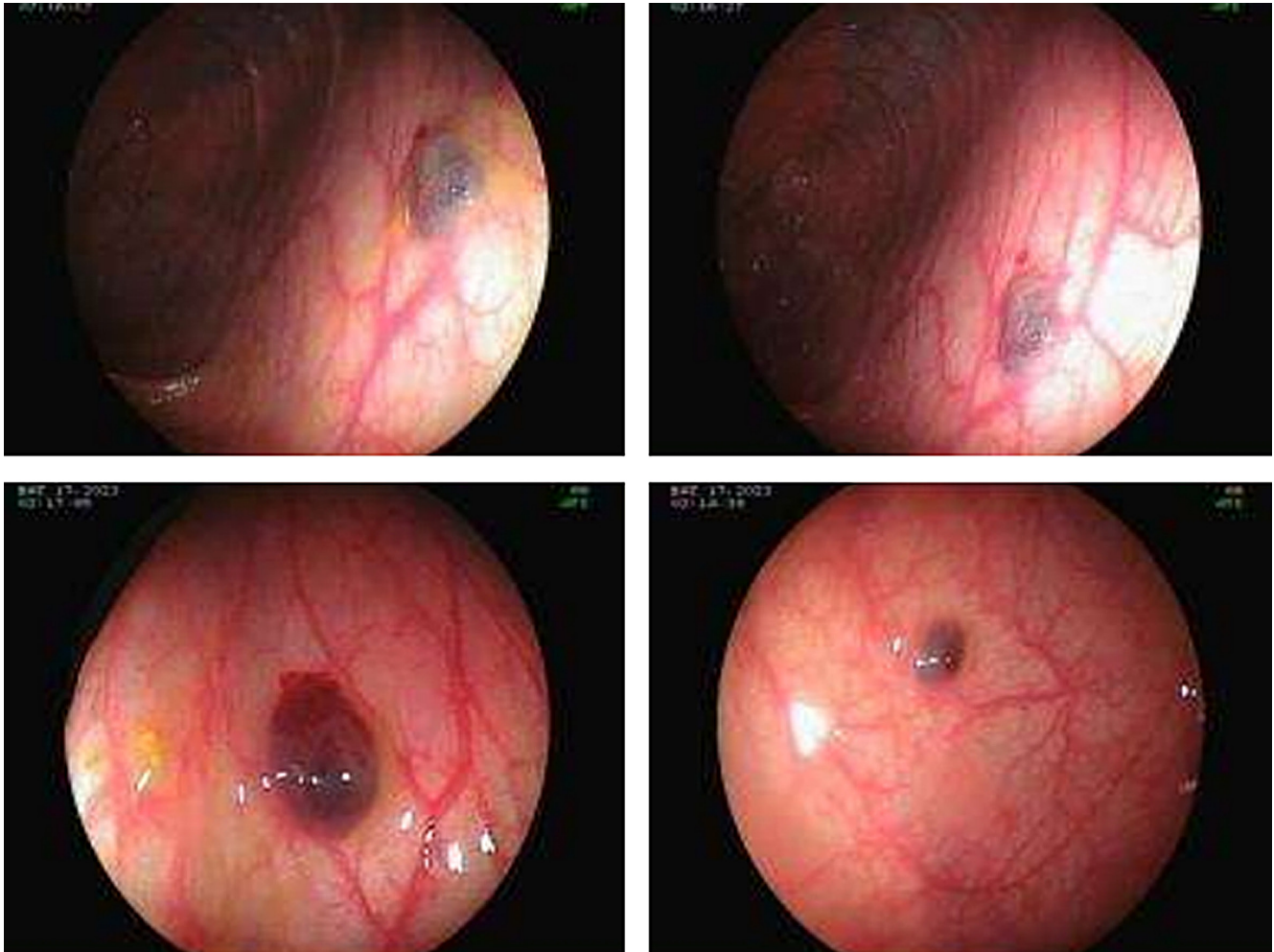


Figure 5. BRBNS in the transverse and descending colon. Images courtesy of Dr. Fabián Eduardo Puentes Manosalva, Unión de Cirujanos S.A.S., Manizales, Colombia, Clinical-Surgical Gastroenterology Service, Universidad de Caldas.

ber bleb” covered by thin, compressible skin that reappears upon releasing digital pressure; and type 3 includes irregular blue or black macules or papules that do not blanch with digital pressure^(5,9). Histologically, vascular malformations are evident without malignant changes, featuring dilated capillaries, flattened endothelium, connective tissue stroma, and a deficiency of smooth muscle cells^(5,6).

Cutaneous lesions vary in size and number and are often asymptomatic, though they may occasionally be accompanied by pain and hyperhidrosis. Some deeper lesions can invade muscle, joints, and bone, potentially causing bone deformities, pathologic fractures, hemarthrosis, and early-onset osteoarthritis. When located outside the skin, lesions often produce symptoms specific to their site, such as abdominal pain, melena, hematochezia, rectal bleeding,

anemia, hematuria, orbital malformations, intussusception, volvulus, intestinal ischemia, spinal cord compression, and others^(2,9-12). Oral lesions may present as superficial and deep angiomatoid tumors, commonly on the tongue, frequently causing pain⁽¹¹⁾. Differential diagnoses primarily include Osler-Weber-Rendu syndrome, Klippel-Trénaunay syndrome, Maffucci syndrome, Von Hippel-Lindau syndrome, Sturge-Weber syndrome, Cobb syndrome, and multiple glomangiomas^(11,13).

Diagnosis can be clinical, histopathological, and radiological. It can also be complemented with endoscopic examination, fecal occult blood testing, urinalysis, complete blood count, and iron kinetics studies. Lesions may be detected by Doppler ultrasound and computed tomography (CT), but magnetic resonance imaging (MRI) with

venous and arterial contrast and fat suppression offers superior visualization^(6,7,9).

Since these are low-flow venous malformations, the possibility of thrombosis should be considered, identified by tenderness on palpation, warmth, and edema at the lesion sites. Splenoportal thrombosis with splenic infarction has also been reported. In addition to hemorrhage, other complications can arise, such as calcifications (phleboliths), and, in less frequent cases, consumption coagulopathy and thrombocytopenia^(4,9,11,12).

Up to 97% of patients have cutaneous involvement; 87% may present involvement of more than one organ, 76% have gastrointestinal hemangiomas, and 13% may experience CNS involvement⁽⁹⁾.

Morbidity and mortality depend on the extent and number of visceral lesions. Severe cases often present as major gastrointestinal bleeding. Gastrointestinal lesions in BRBNS may appear as multilobulated, nodular, pedunculated, sessile, ulcerated, angiomatoid lesions with a wine-red or violaceous color, raised above the mucosa, with a rough surface or even slightly depressed with central umbilication^(3,12). For a complete diagnosis, various endoscopic studies, including esophagogastroduodenoscopy, colonoscopy, enteroscopy, and capsule endoscopy, are very useful. Endoscopic ultrasound may also be used for lesions accessible to this technique, helping to determine if they are transmural, which guides endoscopic management⁽¹²⁾.

A multidisciplinary approach is recommended for BRBNS to determine the extent of the disease and therapeutic plan. Treatment should be individualized based on the size, number, and location of the lesions. Surgical resection may be considered for cutaneous lesions, primarily for aesthetic purposes or if they are painful, especially for small superficial lesions between two and four cm that do not invade other structures. If these criteria are not met, preoperative embolization may be performed. Another management option is sclerotherapy, which induces thrombosis and necrosis of the malformation, ultrasound-guided cryoablation, or laser therapy^(7,9,12).

Currently, there is no curative treatment. For gastrointestinal lesions, management is symptomatic and generally conservative, with iron supplementation or blood transfusions as needed. Specific endoscopic therapies are also possible, including sclerotherapy, rubber band ligation, argon plasma coagulation, electrocautery, cyanoacrylate injection, or surgery (such as segmental intestinal resections or colectomies). When gastrointestinal lesions are too extensive and uniformly distributed throughout the intestine, surgical resection is not feasible due to the risk of short bowel syndrome. If the lesions are not bleeding, BRBNS patients may be monitored clinically^(4,9,10,12), as in the case of the patient presented in this

article, who is under follow-up by dermatology, gastroenterology, and otolaryngology services.

Pharmacological management has also been described, involving drugs such as propranolol, corticosteroids, octreotide, and interferon-alpha. Additionally, with more promising results, sirolimus (rapamycin) has been used, an immunosuppressant that inhibits the mTOR (mammalian target of rapamycin) pathway. Due to its antineoplastic properties, which inhibit neovascularization and tumor cell proliferation, sirolimus has shown benefits in reducing the number and size of BRBNS lesions^(9,10).

For patients requiring surgery under general anesthesia, airway management can be challenging when BRBNS lesions are present in the larynx or trachea, as seen in the patient presented here, who has BRBNS involvement in the supraglottic region and at the base of the tongue, posing risks of obstruction or bleeding at these sites. Therefore, it is crucial for the anesthesiologist to conduct a thorough preoperative assessment, ideally with consideration for a videolaryngoscope and, if necessary, a fiber-optic bronchoscope. Additionally, in patients with BRBNS lesions in the spinal canal, epidural anesthesia may lead to bleeding and hematoma formation if not carefully managed⁽⁸⁾.

CONCLUSION

Blue rubber bleb nevus syndrome (BRBNS) is a rare condition characterized by multiple vascular malformations and hemangiomas affecting various organs, primarily the skin and gastrointestinal tract. With only around 200 cases reported worldwide, we consider it highly relevant to contribute this case to the medical literature in Colombia, where we have identified a patient with BRBNS presenting not only cutaneous involvement but also lesions in the colon, supraglottic region, and at the base of the tongue.

BRBNS may be asymptomatic or present with painful cutaneous lesions with hyperhidrosis, bone deformities, hemarthrosis, abdominal pain, melena, hematochezia, rectal bleeding, anemia, hematuria, and other symptoms. Evaluation can be supplemented with endoscopic examination, fecal occult blood testing, urinalysis, complete blood count, and iron kinetics. Imaging studies such as Doppler ultrasound, CT, and MRI are also useful. A multidisciplinary approach is recommended to assess the extent of the disease and establish a therapeutic plan. Currently, there is no curative treatment. For gastrointestinal lesions, management is generally conservative and symptomatic, as in the case of the patient presented here, who is under follow-up by dermatology, gastroenterology, and otolaryngology services. Iron supplementation or blood transfusions may be required if necessary. In some cases, endoscopic or surgical

intervention may be offered, where the potential presence of BRBNS lesions in the larynx or trachea should be considered. In this case, the patient has BRBNS involvement in the supraglottic region and at the base of the tongue, presenting a risk of obstruction or bleeding at these sites, which poses a challenge for the anesthesiologist. Among

pharmacological options, sirolimus has shown the most promising results.

Conflict of Interest

The authors declare no conflicts of interest for this article.

REFERENCES

1. Blanco-Velasco G, Zamarripa-Mottú R, Solórzano-Pineda OM, Murcio-Pérez E, Hernández-Mondragón OV. Blue rubber bleb nevus syndrome in geriatric patients. *Rev Gastroenterol Mex (Engl Ed)*. 2020;85(2):215-216. <https://doi.org/10.1016/j.rgm.2019.03.004>
2. Laube R, Rickard M, Lee AU. Gastrointestinal: Small intestinal blue rubber bleb nevus syndrome. *J Gastroenterol Hepatol*. 2021;36(10):2637. <https://doi.org/10.1111/jgh.15422>
3. Matas JL, Asteiza M, Loscos JM, Fernández S, Ramírez-Armengol JA, Díaz-Rubio M. Síndrome del nevus gomoso azul (blue rubber bleb nevus) diagnosticado por cápsula endoscópica. *Rev Esp Enferm Dig*. 2006;98(7):555-6. <https://doi.org/10.4321/S1130-01082006000700011>
4. Solano-Iturri G, Blanco-Sampascual S, García-Jiménez N, Díaz-Roca AB, Orive-Cura V. Síndrome del nevus azul. Una rara entidad. *Gac Med Bilbao* 2011;108(4):117-119. <https://doi.org/10.1016/j.gmb.2011.06.005>
5. López-Ugalde MV, Cazares-Méndez MJ, Vivar-Aquino LD, Cadena-León JF, Cervantes-Bustamante R, Zárate-Mondragón F, et al. Síndrome de nevos azules ahulados: reporte de un caso. *Rev Gastroenterol Mex*. 2012;77(4):216-9. <https://doi.org/10.1016/j.rgm.2012.05.003>
6. Jaramillo CI, Vélez A, Molina V. Síndrome de los nevos azules cauchosos. *Rev Asoc Colomb Dermatol Cir Dermatol*. 1999;7(3):242-244.
7. Triana GA, Valencia S, Forero PA. Manifestaciones radiológicas del síndrome del nevus azul. Presentación de caso. *Rev Colomb Radiol*. 2021;32(2):5569-5572. <https://doi.org/10.53903/01212095.138>
8. Aizawa M, Ishihara S, Yokoyama T. Anesthetic considerations for blue rubber bleb nevus syndrome: a case report. *JA Clin Rep*. 2019;5(1):83. <https://doi.org/10.1186/s40981-019-0304-4>
9. Tibaduiza MF, Ton CM, Múnera MS, Plaza M. Síndrome de nevos azules cauchosos: reporte de un caso familiar. *Rev Asoc Colomb Dermatol Cir Dermatol*. 2022;30(3):204-208. <https://doi.org/10.29176/2590843X.1649>
10. Ferrés L, Knöpfel N, Salinas JA, Martín A. Rapamycin in the treatment of blue rubber bleb nevus syndrome. *Actas Dermosifiliogr* 2015;106(2):137-152. <https://doi.org/10.1016/j.adengl.2014.12.006>
11. Coral A, Ávalos V, Fragoso R, Cuairán V. Síndrome *blue rubber bleb nevus*. Reporte de un caso: manejo estomatológico. *Oral*. 2015;16(52):1297-1300.
12. Gutiérrez I, León R, López T, Márquez JL. Aportación de las nuevas técnicas endoscópicas al síndrome del nevus azul. *RAPD Online*. 2013;36(3):190-194.
13. Kido M, Nakamura K, Kuwahara T, Yasui Y, Okajima H, Kurose N, et al. Arteriovenous malformation that caused prolapse of the colon and was treated surgically in an infant: a case report. *Surg Case Rep*. 2020;6(1):67. <https://doi.org/10.1186/s40792-020-00824-x>



Available in:

<https://www.redalyc.org/articulo.oa?id=337782279015>

How to cite

Complete issue

More information about this article

Journal's webpage in redalyc.org

Scientific Information System Redalyc
Diamond Open Access scientific journal network
Non-commercial open infrastructure owned by academia

Fabián Eduardo Puentes-Manosalva,
Rubén Darío Londoño-López, Andrés Sánchez-Gil,
Lázaro Antonio Arango-Molano

**Blue Rubber Bleb Nevus Syndrome in the Colon, Tongue,
and Supraglottic Region: Case Report**
**Síndrome de blue rubber bleb nevus en el colon, lengua y
región supraglótica: reporte de caso**

Revista colombiana de Gastroenterología
vol. 39, no. 3, p. 337 - 343, 2024
Asociación Colombiana de Gastroenterología,
ISSN: 0120-9957
ISSN-E: 2500-7440

DOI: <https://doi.org/10.22516/25007440.1113>