



Journal of the Selva Andina Research Society

ISSN: 2072-9294

ISSN: 2072-9308

editor.research-society@sars.org.bo

Selva Andina Research Society

Estado Plurinacional de Bolivia

Calderón León, María Fernanda; Cabrera Moyano, Diego Mauricio; Cárdenas Rodríguez, Jorge Daniel; Saltos Román, Andrea Alexandra; González Sánchez, Maryoli

Giant ovarian cystoadenoma and pregnancy

Journal of the Selva Andina Research Society, vol. 16, núm. 2, 2025, pp. 175-182

Selva Andina Research Society

La Paz, Estado Plurinacional de Bolivia

DOI: <https://doi.org/10.36610/j.jsab.2025.130100034>

Disponible en: <https://www.redalyc.org/articulo.oa?id=361383157017>


- ▶ [Cómo citar el artículo](#)
- ▶ [Número completo](#)
- ▶ [Más información del artículo](#)
- ▶ [Página de la revista en redalyc.org](#)

redalyc.org

Sistema de Información Científica Redalyc

Red de revistas científicas de Acceso Abierto diamante

Infraestructura abierta no comercial propiedad de la academia



Giant ovarian cystadenoma and pregnancy

Cistoadenoma gigante de ovario y embarazo

Calderón León María Fernanda^{1*} , Cabrera Moyano Diego Mauricio² , Cárdenas Rodríguez Jorge Daniel¹ ,
Saltos Román Andrea Alexandra¹ , González Sánchez Maryoli¹ 

Article Data

¹ Ministry of Public Health.
National Government Health System.
Guayaquil University Hospital.
24A Street NW, Perimetral Road.
Guayaquil, Ecuador.

² Ministry of Public Health.
Zonal Coordination 8.
Matilde Hidalgo Hospital in Procel.
P4FF+H3V, Dr. Fernando López Lara.
Guayaquil 090110.
Ecuador.

*Contact Address:

Ministry of Public Health.
National Government Health System.
Guayaquil University Hospital.
24A Street NW, Perimetral Road.
Guayaquil, Ecuador.
Tel: +593 98 236 5566

María Fernanda Calderón León
E-mail address: dracalderonleon@hotmail.es

Keywords:

Pregnancy,
ovary,
pregnancy outcome,
ovarian diseases,
ovarian neoplasms.

J. Selva Andina Res. Soc.
2025; 16(2):175-182.

Article ID: [193/JSARS/2025](https://doi.org/10.15388/JSARS/2025)

Article history

Received February 2025.
Returned May 2025.
Accepted June 2025.
Available online August 2025.

Edited by:
**Selva Andina
Research Society**

Palabras clave:

Embarazo,
ovario,
resultado de embarazo,
enfermedades de los ovarios,
neoplasias de ovario.

Abstract

The presence of a giant ovarian tumor in pregnancy is very rare, these masses are usually asymptomatic and are detected incidentally on the ultrasound examination of the first trimester or until they reach a large size, whose removal can be performed during cesarean section. We present a clinical case of a 34-year-old female patient, 36 weeks pregnant, who presented a giant ovarian tumor evidenced during the emergency cesarean section, a live newborn was obtained and a giant tumor of the left ovary was present that measured 22 x 17 cm in diameter. An elective cesarean section can be chosen along with salpingo oophorectomy in case of a giant ovarian cyst that complicates a full-term pregnancy as in the case presented. Ultrasound continues to be the most important tool in the study of adnexal masses due to its safety, availability and accuracy; however, the definitive diagnosis is granted by histopathology. The use of magnetic resonance imaging can also be used, to help distinguish benign tumors from malignant ones more accurately during pregnancy. It is important to carry out prenatal control and strict monitoring of the tumor, to decide the time of surgical treatment, in order to avoid maternal or fetal complications.

2025. Journal of the Selva Andina Research Society®. Bolivia. All rights reserved.

Resumen

La presencia de un tumor gigante de ovario en el embarazo es algo muy raro, estas masas suelen ser asintomáticas y se detectan incidentalmente en el examen ecográfico del primer trimestre o hasta que alcanzan un gran tamaño, cuya extirpación se puede realizar durante la cesárea. Se presenta un caso clínico de un paciente femenino de 34 años, gestante de 36 semanas que presentó un tumor gigante de ovario evidenciado durante la cesárea de emergencia, se obtuvo recién nacido vivo y presencia tumor gigante de ovario izquierdo que midió 22 x 17 cm de diámetro. Se puede optar por una cesárea electiva junto con salpingo ooforectomía en caso de un quiste ovárico gigante que complica un embarazo a término como en el caso presentado. La ecografía sigue siendo la herramienta más importante en el estudio de masas anexiales debido a su seguridad, disponibilidad y precisión, no obstante, el diagnóstico definitivo lo otorga la histopatología. También se puede recurrir al uso de resonancia magnética, para ayudar a distinguir los tumores benignos de los malignos con mejor precisión durante el embarazo. Es importante realizar control prenatal y seguimiento estricto del tumor, para decidir el momento de tratamiento quirúrgico, con el fin de evitar complicaciones maternas o fetales.

2025. Journal of the Selva Andina Research Society®. Bolivia. Todos los derechos reservados.



Introduction

Adnexal masses are diagnosed in 0.2 to 2 % of pregnancies, most of which are simple, benign cysts with a diameter of less than 5 cm, however, in the case of a malignant tumor, the risks of prematurity, thrombosis, and hysterectomy should be reported¹.

The types of adnexal masses in pregnancy that require surgical management are dermoid cysts (32 %), endometriomas (15 %), functional cysts (12 %), serous cystadenomas (11 %), mucinous cystadenomas (8 %), and approximately 2 % are malignant².

The presence of a giant ovarian tumor in pregnancy is very rare, these masses are usually asymptomatic, they are detected incidentally in the ultrasound examination of the first trimester, or until they reach a large size, whose removal can be performed during the cesarean section in a single step or in two-step surgery. Large ovarian tumors are found in less than 1 % of all ovarian cysts in pregnancy, and are associated with a poor fetal-maternal outcome, due to the multiple complications that can occur, so that, in general, all ovarian cysts during pregnancy should be followed up with routine ultrasounds and regular prenatal check-ups^{3,4}.

When giant ovarian tumor and pregnancy coexist, elective cesarean section can be performed together with salpingo-oophorectomy depending on the case and the level of complication in the pregnancy, the approach can be performed by laparoscopic surgery depending on the weeks of gestation or open in cases of emergency⁵.

Ultrasound is the initial diagnostic method, a mass of variable diameters can be observed, with multiple septa and cystic areas, another diagnostic method is

magnetic resonance imaging, a cystic mass can be seen in the adnexal region, with multiple septa that capture the contrast material with the presence of hemorrhage^{6,7}. The definitive diagnosis is provided by histopathology, a very important examination since there are tumors such as mature teratoma of the ovary that occur during pregnancy that have a rate of 1.1 % of malignant transformation, which can cause chemical peritonitis in cases of tumor rupture⁸. Cases of recurrent mucinous cystadenoma have been reported, or the coexistence of cystadenoma with mature teratoma requiring multiple surgeries⁹⁻¹¹. Cases of ovarian mucinous cystadenoma with functional stroma that produces hormones such as androgens are also described, which can cause virilization of pregnancy, fetal distress and premature birth^{12,13}.

The presence of ovarian masses during pregnancy can lead to complications: torsion of the cyst, cystic rupture, infection or abnormal presentation of the fetus¹⁴.

Surgical treatment is performed when the mass produces acute symptoms such as pain or in cases of a size greater than 5 cm. After surgery, the patient needs to receive follow-up care to monitor postoperative recurrence⁷.

There is a consensus that the best time for surgery is the second trimester, since in the first trimester it can increase the risk of miscarriage and luteal dysfunction and in the third trimester it can cause some important complications such as torsion, rupture, hemorrhage, intrauterine growth restriction or premature birth¹⁵.

The objective was to present a clinical case of giant

ovarian tumor in a 36-week pregnant woman.

Case presentation

A 34-year-old female patient born in Guayaquil, works in a gastronomic center in Samborondón, presents a clinical picture of 72 h of evolution, characterized by abdominal pelvic pain of moderate intensity, does not report transvaginal bleeding, nor loss of fluid, fetal movements perceived by the mother, has an obstetric ultrasound performed 3 days ago, she reported a pregnancy of 36 weeks plus fetus in a transverse situation plus moderate oligohydramnios with an amniotic fluid index of 5.4 mL, with the presence of a left maternal ovarian cyst measuring approximately 10 x 15 cm.

Obstetric and gynecological history. She has 2 previous cesarean sections with an interreproductive period of 13 years, onset of sexual life at 16 years, menarche at 14 years, sexual partners 1, last Pap smear was 2 years ago, does not refer to the date of last menstruation.

Physical exam. Patient oriented in time and space, alogic fascies, symmetrical chest, clear and ventilated lung fields, rhythmic heart sounds. Globular abdomen with pregnant uterus, uterine height 35 cm, transverse product, abdomen painful on palpation mainly at the level of the left hypochondrium.

On vaginal examination, posterior cervix, closed, painful to the touch, there is no evidence of transvaginal leakage. Patient is admitted for emergency and goes to the operating room for emergency cesarean section.

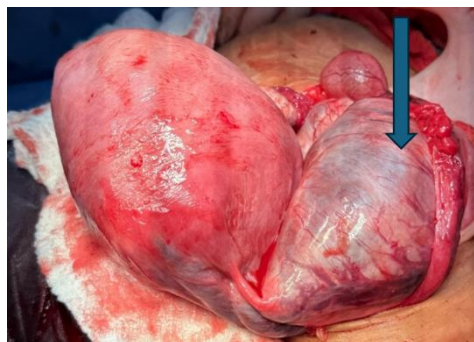Vital signs. Blood pressure 120/80 mmHg, heart rate 97 bpm, respiratory rate 20 rpm, temperature 36.5° C, saturation 99 %.

It is indicated to place a peripheral line with Ringer's Lactate 1000 mL, to pass intravenously to a drip of 30 drops per min and also to pass 2 g of cefazolin as

prophylactic antibiotic therapy 30 min before the surgical procedure.

Surgical procedure. Segmental cesarean section plus unilateral right partial salpingectomy plus left salpingo oophorectomy + excision of giant tumor of the left ovary + adhesiolysis was performed.

Figure 1 Giant tumor of the left ovary partially seen



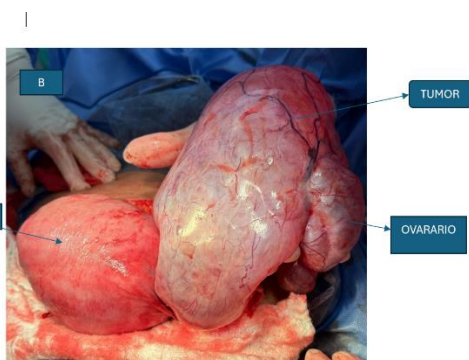
A post-pregnant uterus was visualized in a transsurgical cesarean section with partial exposure of the highly vascularized left ovarian tumor

Surgical findings. Abundant adipose tissue approximately 10 cm, posterior fundic placenta, gestational age pregnant uterus, left ovarian cyst measuring approximately 22 x 17 cm in diameter. Bleeding muscle plane clear amniotic fluid moderate amount, live newborn Apgar 6-7-7 weight 3695 g, head circumference 35 cm, height 47 cm, thoracic circumference 31 cm, abdominal circumference 30 cm, Capurro 36 weeks gestation. Right appendix macroscopically normal, blood loss of about 500 mL, complete materials, trans-surgical diuresis 200 mL.

Surgical technique. Prior to asepsis and antisepsis of the surgical area, sterile drapes were placed, and an infra media umbilical incision was made that allowed a better approach in the abdominal cavity. It was dissected by anatomical planes: subcutaneous cellular tissue, aponeurosis, muscle and peritoneum until reaching surgical field exposure where a pregnant uterus was observed, Kerr-type hysterotomy was performed, showing scarce amniotic fluid light color, extraction of a live male newborn (NB), in breech

presentation, with weak crying, was clamped and cut immediately and NB was delivered to the pediatrician on duty. The placenta was extracted manually with extraction of complete membranes and suturing in 3 planes, with rigorous hemostasis control, a contracted uterus was confirmed. The left annex was identified and evaluated, where the presence of a giant tumor of the left ovary with a size greater than 15 cm in diameter was observed, which completely took over the ovary because it could not be preserved, and left adnexectomy was performed. During the intraoperative period after the removal of the tumor, the patient presented temporary hypotension. Suture of the left pelvic infundibular ligament was performed with vicryl 1, and another reinforcement suture with the same thread 0.5 cm lower with hemostasis control. A unilateral right partial salpingectomy was performed, the abdominal cavity was dried and closed by planes until the skin was reached.

Figure 2 Giant tumor of the left ovary seen in its entirety



A post-pregnant uterus was visualized in a transoperative cesarean section, with total exposure of the highly vascularized left ovarian tumor measuring approximately 22 x 17 cm in diameter

Post-surgical vital signs. Blood pressure 104/70 mmHg, respiratory rate 20 rpm, heart rate 99 bpm, saturation 99 %.

Postoperative medication and indications. Intravenous Ringer's lactate 1000 mL at 30 drops per min, cefazolin 1 g intravenously every 6 h, ketorolac 60 mg intravenously every 8 h, metoclopramide 10 mg

intravenously every 12 h, nothing orally for 6 h, breastfeeding and control of vital signs, surgical dressing control, control of lochia and uterine involution are indicated.

Evolution. The patient spent her first hours in the postoperative ward in stable clinical conditions, reported mild pain at the surgical site, presented a uterus with normal involution located below the umbilical scar, scarce non-fetid blood lochia, normal facies, was maintained with analgesic and antibiotic treatment by schedule.

The patient remained hospitalized for 72 h in a joint accommodation room, with a favorable evolution, in stable clinical conditions, vital signs within normal, for which she was discharged and returned to her normal life with follow-ups by the gynecology and obstetrics outpatient clinic where she went showing calm and with good evolution.

Discussion

The option of surgical intervention versus conservative treatment should be tailored to the patient's physical symptoms, tumor characteristics, and gestational age. An elective cesarean section can be chosen together with salpingo-oophorectomy in case of a giant ovarian cyst that complicates a full-term pregnancy as in the case presented, the patient was 36 weeks pregnant and went to the emergency area for presenting abdominal pain with a large twisted cyst of the left ovary, determined by ultrasound, she underwent emergency cesarean section with left salpingo-oophorectomy + excision of giant tumor of the left ovary, but according to algorithm, in the presence of a tumor in the ovary in a symptomatic woman, regardless of gestational age, surgical treatment should be given (preferably before 12 weeks of gestation), on the other hand, if the patient arrives without symptoms, morphological evaluation should be performed

by ultrasonography and according to the results it is decided whether to maintain ultrasound follow-up or surgical treatment possibly between 12 and 18 weeks¹⁶.

Ovarian cysts that coexist with pregnancy must be adequately controlled, if there is not good prenatal control, the possibility of not knowing the presence of a tumor as large as the one presented by the patient who reported not knowing that she had said tumor from the beginning of her pregnancy may arise¹⁶.

The decision to postpone surgical treatment of a complex mass until the time of delivery must weigh the risks and benefits for the mother and fetus. In the case presented, the product was in a transverse situation, it was extracted in breech presentation, oligohydramnios was evidenced and it was born at 36 weeks, it was received and observed by the neonatology service who decided endotracheal intubation of the newborn due to respiratory distress.

Most adnexal masses are benign during pregnancy, since their differential diagnosis is broad and includes both benign and malignant lesions, which can be physiological cysts such as follicular cysts, corpus luteum cysts and theca luteal cysts or other benign tumors such as mature cystic teratoma, serous and mucinous cystadenoma, The latter tend to be unilateral and multilocular with a smooth surface and contain mucinous fluid. In ultrasound diagnosis, the masses have different characteristics, i.e. the high-risk masses tend to be solid, nodular, with thick septa, the intermediate-risk masses are not anechoic and/or unilocular, but do not have characteristics of malignancy, and the low-risk masses are fluid-filled, unilocular anechoic cysts with thin walls. It should be noted that some lesions that have benign characteristics on ultrasound occasionally turn out to be malignant at the time of surgery¹⁴.

Cancer is a relatively rare finding during pregnancy, occurring in approximately 0.05 to 1 % of all pregnancies. Non-epithelial cancers, including germ cell and stromal cancers, tend to present as bulky masses that reach large dimensions. Patients usually present with symptoms and pain, bloating, or bleeding. Because of the frequency of ultrasound scans during pregnancy, approximately 90 % of pregnant patients with ovarian cancer are diagnosed with stage I disease. Tumor markers present changes during pregnancy, so according to the histological type in the epithelial tumor the CA 125 marker increases in the first trimester and then decreases, CEA is not influenced by pregnancy, HE4 levels lower in pregnant women, values slightly increased in the third trimester, in cases of mucinous tumor CA 19.9 increases slightly with gestational age; it never exceeds the normal range, in mucinous carcinoma, inhibin A presents increased values in the first trimester; abnormally increased in Down syndrome, in the case of granulosa cell tumor, inhibin B, is not influenced by pregnancy, in germ cell tumors, b-HCG, physiologically increased during pregnancy, Alpha fetus protein, physiologically increased in pregnancy; abnormally increased neural tube defects; decreased in Down syndrome, in the case of Dysgerminoma, LDH is measured, which also increases in severe preeclampsia and HELLP syndrome¹⁷.

Conclusion

Ultrasound continues to be the most important tool in the study of adnexal masses due to its safety, availability and accuracy; however, the definitive diagnosis is granted by histopathology. Using ultrasound, it is often difficult to differentiate a borderline ovarian tumor from a benign or invasive ovarian neoplasm, since magnetic resonance imaging can be used to

help distinguish benign tumors from malignant tumors more accurately during pregnancy. It is important to perform prenatal control and if there is the presence of an ovarian tumor, it should be distinguished if it is symptomatic, perform surgical intervention regardless of gestational age, if it is asymptomatic, an ultrasound morphological evaluation should be carried out and according to that determine if the pregnancy is continued with ultrasound follow-up or if surgical intervention is decided to remove the tumor preferably between the 12th and 18th week of pregnancy. Tumor markers are diagnostic aids that, although it is true, during pregnancy tend to rise, but not all of them are influenced by the gestational stage, since in the presence of an ovarian mass during pregnancy it is also advisable to evolve tumor markers.

Source of financing

Without external sources of financing, authors' own funds.

Conflicts of interest

The authors declare that they have no conflict of interest.

Acknowledgments

We thank the University Hospital for allowing us to have access to the medical history and the patient to develop this research.

Ethical considerations

For this publication, authorization was requested from the patient by signing informed consent, in this

case description there is no patient identification or photos of her face.

Limitations in the research

Lack of randomization, we cannot generalize the results on a large scale.

Future prospects

Future research could focus on larger, multicenter studies to evaluate treatment related to the new guidelines.

Permissions for publication

A document signed by the patient authorizing the publication of the clinical case is attached.

Authors' contribution to the article

The authors declare to have contributed to the original idea (*María Calderón*), research design (*Diego Cabrera*), data collection (*Jorge Cárdenas, María Calderón, Andrea Saltos*), data analysis (*María Calderón, Maryoli González*), draft writing and article writing (*María Calderón, Diego Cabrera, Jorge Cárdenas, Andrea Saltos, Maryoli González*).

Use of artificial intelligence

We assume that the entire document was written based on ethical and professional criteria, and AI was not used to make the images or text.

Cited literature

1. Nazer A, Czuzoj-Shulman N, Oddy L, Abenhaim HA. Incidence of maternal and neonatal outcomes in pregnancies complicated by ovarian masses.

- Arch Gynecol Obstet 2015;292(5):1069-74. DOI: <https://doi.org/10.1007/s00404-015-3700-7>. PMID: 25864094.
2. Cathcart AM, Nezhat FR, Emerson J, Pejovic T, Nezhat CH, Nezhat CR. Adnexal masses during pregnancy: diagnosis, treatment, and prognosis. *Am J Obstet Gynecol* 2023;228(6):601-12. DOI: <https://doi.org/10.1016/j.ajog.2022.11.1291>. PMID: 36410423.
 3. Prat J. Ovarian carcinomas: five distinct diseases with different origins, genetic alterations, and clinicopathological features. *Virchows Arch* 2012; 460(3):237-49. DOI: <https://doi.org/10.1007/s00428-012-1203-5>. PMID: 22322322.
 4. Boulay R, Podczaski E. Ovarian cancer complicating pregnancy. *Obstet Gynecol Clin North Am* 1998;25(2):385-99. DOI: [https://doi.org/10.1016/S0889-8545\(05\)70012-7](https://doi.org/10.1016/S0889-8545(05)70012-7)
 5. Abe H, Nakao S, Itagaki H, Hosokawa Y, Shikama A, Tasaka N, et al. Cellular angiofibroma in the retroperitoneal space during pregnancy: A case report. *BMC Womens Health* 2023;23(1):57. DOI: <https://doi.org/10.1186/s12905-023-02182-w>. PMID: 36765343; PMCID: PMC9912601.
 6. Smorgick N, Maymon R. Assessment of adnexal masses using ultrasound: a practical review. *Int J Womens Health* 2014;6:857-63. DOI: <https://doi.org/10.2147/IJWH.S47075>. PMID: 25285023 ; PMCID: PMC4181738.
 7. Wasnik AP, Menias CO, Platt JF, Lalchandani UR, Bedi DG, Elsayes KM. Multimodality imaging of ovarian cystic lesions: Review with an imaging based algorithmic approach. *World J Radiol* 2013;5(3):113-25. DOI: <https://doi.org/10.4329/wjr.v5.i3.113>. PMID: 23671748; PMCID: PMC3650202.
 8. Rathore R, Sharma S, Agarwal S. Malignant transformation in mature cystic teratoma of the ovary: a retrospective study of eight cases and review of literature. *Prz Menopauzalny* 2018;17(2):63-8. DOI: <https://doi.org/10.5114/pm.2018.77304>. PMID: 30150913; PMCID: PMC6107092.
 9. McKenney JK, Soslow RA, Longacre TA. Ovarian mature teratomas with mucinous epithelial neoplasms: morphologic heterogeneity and association with pseudomyxoma peritonei. *Am J Surg Pathol* 2008;32(5):645-55. DOI: <https://doi.org/10.1097/PAS.0b013e31815b486d>. PMID: 18344868.
 10. Chahkandi M, Mozayani F, Fanoodi A, Bina AR, Ebrahimian AR. Mature cystic teratoma with co-existent mucinous cystadenocarcinoma: describing a diagnostic challenge-a case report. *J Med Case Rep* 2024;18(1):232. DOI: <https://doi.org/10.1186/s13256-024-04544-w>. PMID: 38704586; PMCID: PMC11070101.
 11. Usui R, Minakami H, Kosuge S, Iwasaki R, Ohwada M, Sato I. A retrospective survey of clinical, pathologic, and prognostic features of adnexal masses operated on during pregnancy. *J Obstet Gynaecol Res* 2000;26(2):89-93. DOI: <https://doi.org/10.1111/j.1447-0756.2000.tb01289.x>. PMID: 10870299.
 12. Antoniou N, Varras M, Akkrivis Ch, Demou A, Bellou A, Stefanaki S. Mucinous cystadenoma of the ovary with functioning stroma and virilization in pregnancy: a case report and review of the literature. *Clin Exp Obstet Gynecol* 2003;30(4): 248-52. PMID: 14664425.
 13. Kucur SK, Acar C, Temizkan O, Ozagari A, Gozukara I, Akyol A. A huge ovarian mucinous cystadenoma causing virilization, preterm labor, and persistent supine hypotensive syndrome during pregnancy. *Autops Case Rep* 2016;6(2):39-43. DOI: <https://doi.org/10.4322/acr.2016.029>. PMID : 27547742; PMCID: PMC4982783.
 14. Hakoun AM, AbouAl-Shaar I, Zaza KJ, Abou-Al-Shaar H, A Salloum MN. Adnexal masses in pregnancy: An updated review. *Avicenna J Med* 2017; 7(4):153-7. DOI: <https://doi.org/10.4103/ajm.AJ>

- [M_22_17](#). PMID: 29119081; PMCID: PMC5655645.
15. Yu CH, Weng SF, Ho CH, Chen YC, Chen JY, Chang YJ, et al. Pregnancy outcomes following nonobstetric surgery during gestation: a nationwide population-based case-control study in Taiwan. *BMC Pregnancy Childbirth* 2018;18(1):460. DOI: <https://doi.org/10.1186/s12884-018-2079-4>. PMID: 30477448; PMCID: PMC6257961.
16. Testa AC, Mascilini F, Quagliozzi L, Moro F, Bolomini G, Mirandola MT, et al. Management of ovarian masses in pregnancy: patient selection for interventional treatment. *Int J Gynecol Cancer* 2021;31(6): 899-906. DOI: <https://doi.org/10.1136/ijgc-2020-001996>. PMID: 33172924.
17. Michalczyk K, Cymbaluk-Płoska A. Approaches to the diagnosis and management of ovarian cancer in pregnancy. *Cancer Manag Res* 2021;13: 2329-39. DOI: <https://doi.org/10.2147/CMAR.S290592>.

Editor's Note:

The *Journal of the Selva Andina Research Society (JSARS)* remains neutral with regard to jurisdictional claims published in maps and institutional affiliations, and all statements expressed in this article are those of the authors alone and do not necessarily represent those of their affiliated organizations, or those of the publisher, editors, and reviewers. Any product that may be evaluated in this article or any claims made by its manufacturer are neither guaranteed nor endorsed by the publisher.