



Brazilian Journal of Cardiovascular Surgery

ISSN: 0102-7638

ISSN: 1678-9741

Sociedade Brasileira de Cirurgia Cardiovascular

Jonas, Marina Costa; Martins, Cristiane Nunes; Gontijo, Bayard; Ramalho, Clarissa de Paula Freitas Rocha; Vrandecic, Erika Correa; Amaral, Fernando  
Abnormal Origin of the Pulmonary Artery from the Ascending Aorta in the Neonate  
Brazilian Journal of Cardiovascular Surgery, vol. 37, no. 6, 2022, pp. 937-941  
Sociedade Brasileira de Cirurgia Cardiovascular

DOI: <https://doi.org/10.21470/1678-9741-2021-0359>

Available in: <https://www.redalyc.org/articulo.oa?id=398973636021>

- ▶ [How to cite](#)
- ▶ [Complete issue](#)
- ▶ [More information about this article](#)
- ▶ [Journal's webpage in redalyc.org](#)

The logo for Redalyc.org, featuring the text 'redalyc.org' in a stylized font with a red heart icon to its left.

Scientific Information System Redalyc

Network of Scientific Journals from Latin America and the Caribbean, Spain and Portugal

Project academic non-profit, developed under the open access initiative

# Abnormal Origin of the Pulmonary Artery from the Ascending Aorta in the Neonate

Marina Costa Jonas<sup>1</sup>, MD; Cristiane Nunes Martins<sup>1</sup>, MD; Bayard Gontijo Filho<sup>1</sup>, MD; Clarissa de Paula Freitas Rocha Ramalho<sup>1</sup>, MD; Erika Correa Vrandecic<sup>1</sup>, MD; Fernando Amaral<sup>2</sup>, MD

DOI: 10.21470/1678-9741-2021-0359

## ABSTRACT

The anomalous origin of one pulmonary artery from the ascending aorta is a rare congenital heart disease, generally diagnosed based on the clinical information and on echocardiographic and computed tomography angiography findings. Here we report two neonates successfully treated with surgery early in life.

**Keywords:** Aorta. Computed Tomography Angiography. General Surgery. Heart Defects, Congenital. Infant, Newborn. Information. Pulmonary Artery. Research Report

Abbreviations, Acronyms & Symbols	
Ao	= Aorta
AOPA	= Anomalous origin of pulmonary arteries from the ascending aorta
AP	= Anteroposterior
BCT	= Brachiocephalic trunk
BTT	= Blalock-Taussig-Thomas
CN	= Case number
CPAP	= Continuous positive airway pressure
CT	= Computed tomography
IVC	= Inferior vena cava
LPA	= Left pulmonary artery
LV	= Left ventricle
PA	= Main pulmonary artery
PDA	= Patent ductus arteriosus
PT	= Pulmonary trunk
RA	= Right atrium
RPA	= Right pulmonary artery
RV	= Right ventricle
SVC	= Superior vena cava

## INTRODUCTION

The anomalous origin of pulmonary arteries from the ascending aorta (AOPA) is a rare congenital heart disease (*hemitruncus arteriosus*), usually involving the right branch (right pulmonary artery [RPA])<sup>(1,2)</sup>. Here we report two neonates successfully treated early in life.

**Case number CN 1:** A 3.2 kg female neonate with no chromosomal anomalies, absent prenatal issues, Apgar 8/10, and O<sub>2</sub> saturation 70% required ventilatory assistance in the first hours of life. A systolic murmur was heard, and the chest radiography disclosed an enlarged heart (Figure 1A). Stabilization was possible with O<sub>2</sub> plus intravenous furosemide and prostaglandin. A transthoracic echocardiogram revealed concordant connections, a patent 3-mm ductus (patent ductus arteriosus [PDA]), and RPA connected to the ascending aorta (Figure 1B, arrow), which was confirmed by computed tomography (CT) angiography (Figure 1C, arrow). On the 5<sup>th</sup> day of life, the child underwent surgical approach with cardiopulmonary bypass, a 2.5 endotracheal tube, and myocardial protection with Custodiol® infusion. Cerebral protection was achieved by inducing moderate hypothermia (28°C), normal arterial flow, and avoiding air embolism. The PDA was ligated, the normal size RPA (4 mm of diameter) was disconnected from the ascending

<sup>1</sup>Biocor Institute, Nova Lima, Minas Gerais, Brazil.

<sup>2</sup>Department of Cardiology, Faculdade de Medicina de Ribeirão Preto, Universidade de São Paulo, Ribeirão Preto, São Paulo, Brazil.

This study was carried out at the Biocor Institute, Nova Lima, Minas Gerais, Brazil.

Correspondence Address:

**Marina Costa Jonas**

 <https://orcid.org/0000-0003-2419-3508>

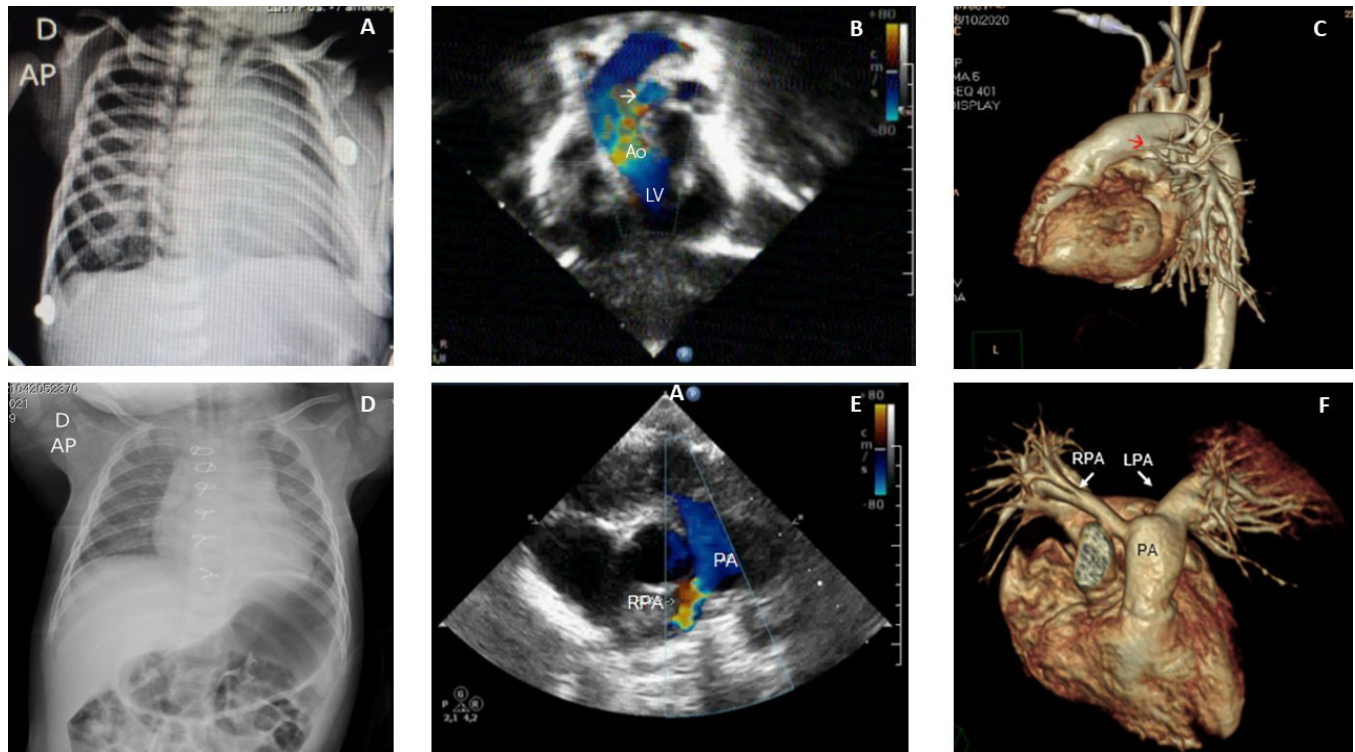
Biocor Institute

Alameda Oscar Niemeyer, 217, Vila da Serra, Nova Lima, MG, Brazil.

Zip Code: 34006-056

E-mail: marina\_jonas@hotmail.com

Article received on June 18<sup>th</sup>, 2021.  
Article accepted on February 19<sup>th</sup>, 2022.

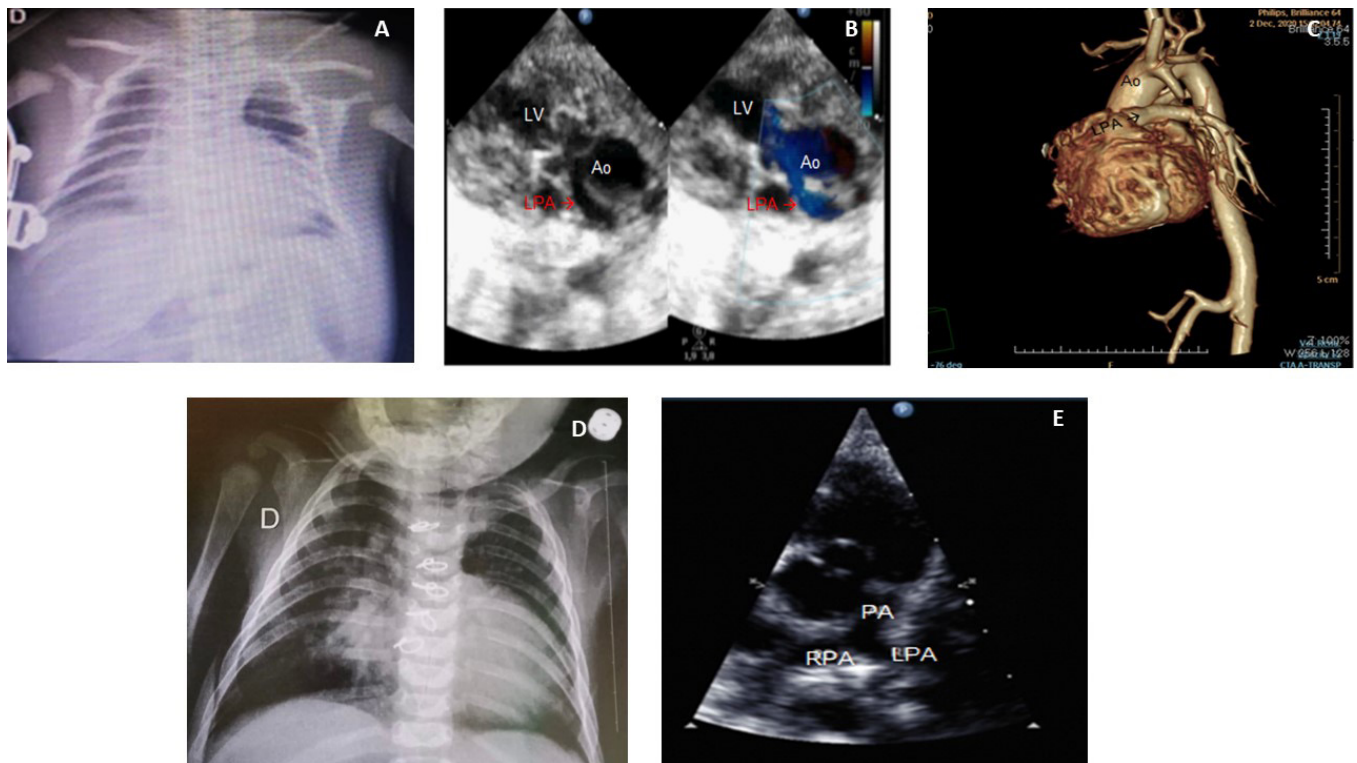


**Fig. 1** - Preoperative (A, B, C) and postoperative (D, E, F) anteroposterior (AP) chest radiography, echocardiogram, and computed tomography angiography in case number 1. Ao=aorta; LPA=left pulmonary artery; LV=left ventricle; PA=main pulmonary artery; RPA=right pulmonary artery.

aorta, and an autologous pericardial patch was used to close its aortic orifice. Ascending aorta retraction was achieved with sutures in the aortic wall, avoiding aorta transection. The RPA was anastomosed to the lateral side of pulmonary artery trunk with an oblique anastomosis in a retroaortic position without a patch. The procedure was completed without transection of the ascending aorta. Ventilation was done in an assist-control mode with progressive regression of parameters until extubation, followed by a 24-hour continuous positive airway pressure (CPAP). Tracheoesophageal fistulation was not noted. Postoperative pulmonary hypertension crises were successfully treated with inhaled nitric oxide, and the patient was discharged 10 days after surgery. At eight months of age, she is asymptomatic on no medication, cardiovascular examination is normal, and neurological status is satisfactory. A recent investigation revealed a normal size heart on the chest radiography with a large stomach air bubble (Figure 1D), a mild stenosis at the anastomotic site in the echocardiogram (Figure 1E, arrow), and the RPA connected to the pulmonary trunk on the CT angiography (Figure 1F).

**CN2:** A 2.5 kg male neonate with no chromosomal anomalies and absent prenatal issues was born with pulmonary valve atresia plus a ventricular septal defect detected on a fetal echocardiogram. Apgar was 7/8 and O<sub>2</sub> saturation was 78%. A systolic murmur was heard in a eupneic child under intravenous prostaglandin. A chest radiography disclosed an enlarged heart

with decreased lung flow (Figure 2A). The echocardiogram showed pulmonary atresia with trunk hypoplasia, a 5-mm ventricular septal defect, PDA, and the left pulmonary artery (LPA) coming off the ascending aorta (Figure 2B, arrow), which was confirmed by CT angiography (Figure 2C, arrow). Operation occurred on the 6<sup>th</sup> day of life under cardiopulmonary bypass with aortic and caval cannulation, myocardial protection with Custodiol®, and a 2.5 endotracheal tube. Cerebral protection was achieved by inducing moderate hypothermia (28°C), normal arterial flow, and avoiding air embolism. A previously planned modified right Blalock-Taussig anastomosis using a 4-mm polytetrafluoroethylene tube between the brachiocephalic trunk and the RPA was made with low risk of vocal cord and hemidiaphragm damage. The normal size LPA was occluded at the beginning of bypass, disconnected from the aortic wall, and reimplanted in the pulmonary trunk by means of an oblique sweep anastomosis without a patch. An autologous pericardial patch was used to close the aortic orifice. Ventilation was in an assist-control mode with progressive regression of parameters until extubation, followed by a 24-hour CPAP. Tracheoesophageal fistulation was not noted. The postoperative period was uneventful, discharge occurred 15 days after surgery due to suction disorder (breathing-swallowing incoordination), and birth weight was recovered at 25 days of life. At six months of age, on low aspirin dose and O<sub>2</sub> saturation of 75%, the neurological status is satisfactory, and a continuous murmur



**Fig. 2** - Chest radiography (A), echocardiogram (B), computed tomography angiography (C), and postoperative chest radiography (D) and echocardiogram (E) in case number 2. Ao=aorta; LPA=left pulmonary artery; LV=left ventricle; PA=main pulmonary artery; RPA=right pulmonary artery.

is heard. Recently, the heart was still enlarged on the chest radiography (Figure 2D), and the LPA was connected to the pulmonary trunk on the echocardiogram (Figure 2E).

## QUESTIONS

- A) Is it possible to suspect of AOPA based on clinical information?  
 B) Are the imaging techniques here employed usually enough for diagnosis?  
 C) Was the surgical treatment offered in agreement with current practice?

## Discussion of Questions

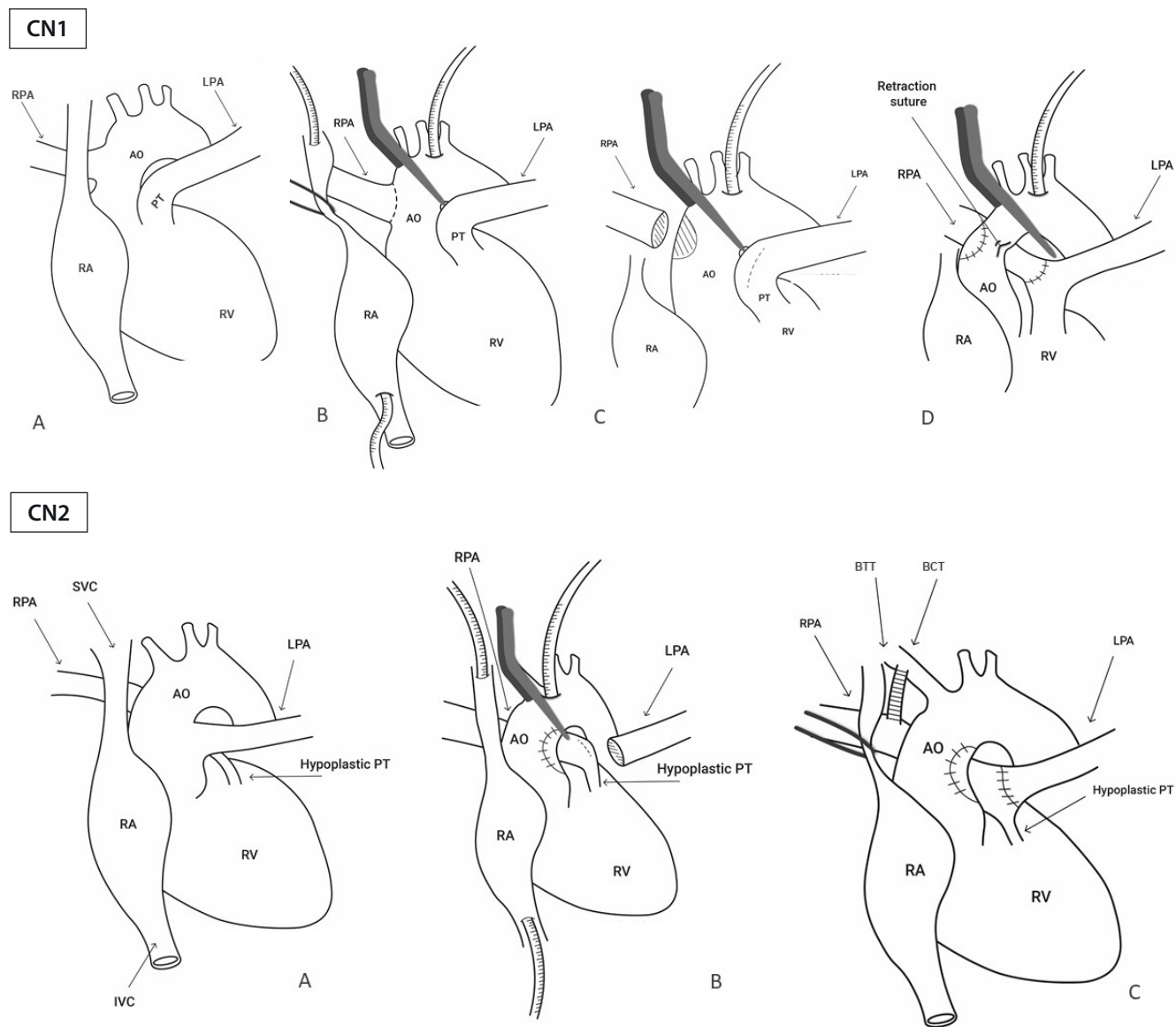
**Question A:** The clinical picture depends on associated anomalies, but patients often present early with progressive respiratory distress and congestive heart failure, resulting in high mortality rate in the first year<sup>[3]</sup>, as it happens in other defects. Secondary pulmonary hypertension due to unrestricted aortic flow may lead to cyanosis due to right-to-left shunting through a PDA or a patent foramen ovale<sup>[4]</sup>. When lung flow obstruction is present, respiratory distress will depend on ductus patency, and in CN2, the patient was in a balanced situation. Although a murmur is frequently heard, physical examination is not specific. Unilaterally increased lung flow on the chest radiography may arise diagnostic suspicion.

**Question B:** The transthoracic doppler echocardiogram is useful for diagnosis<sup>[5-10]</sup>, and some patients might be operated on based solely on its information<sup>[5,11]</sup>. The subcostal short axis view at the level of the great arteries<sup>[5]</sup>, as well as the suprasternal and short axis longitudinal view, can usually establish the diagnosis. Recently, CT angiography has been employed<sup>[2,4,12]</sup>, and its three-dimensional reconstruction can be used for operative planning, avoiding cardiac catheterization.

**Question C:** Under cardiopulmonary bypass with moderate hypothermia, both patients had their anomalous pulmonary artery directly implanted in the pulmonary trunk by means of an oblique sweep anastomosis (Figure 3). The procedure is technically demanding, and this operation is recommended to be done early in life. The surgical findings may eventually require an autologous pericardial patch for completing the anastomosis, which can also be accomplished by a synthetic graft or an aortic flap. Associated procedures might also be necessary<sup>[2,4,5,9,11-13]</sup>, like in both cases reported, and current surgical mortality is reported to be very low<sup>[2,4,12,14]</sup>.

## BRIEF CONSIDERATIONS OF THE CASES REPORTED

These cases reflect the current recommendations regarding AOPA management in newborns. A high degree of suspicion is necessary to prevent serious consequences, like early pulmonary hypertension and death. Careful echocardiographic examination



**Fig. 3** - Case number (CN) 1 – A) Right pulmonary artery (RPA) originated from ascending aorta (Ao). B) Aortic and caval cannulation; incision in proximal RPA. C) Disconnection of RPA from aortic wall; closure of aortic orifice with autologous pericardial patch. D) RPA reimplanted in the pulmonary trunk (PT); retraction suture in aortic wall. CN2 – A) Left pulmonary artery (LPA) originated from ascending Ao and hypoplastic PT in pulmonary atresia. B) Aortic and caval cannulation; disconnection of LPA from aortic wall; closure of aortic orifice with autologous pericardial patch. C) Blalock-Taussig-Thomass (BTT) modified shunt; LPA reimplanted in the PT. BCT=brachiocephalic trunk; IVC=inferior vena cava; RA=right atrium; RV=right ventricle; SVC=superior vena cava.

frequently identifies the anomalous artery, and contemporary investigation by CT angiography is usually enough for surgical planning. Good surgical results are expected but close follow-up is mandatory to detect eventually occurring residual stenosis at the anastomotic site as well as for treatment of associated lesions not yet addressed. As experience increases, very long-term results will appear.

#### ACKNOWLEDGMENTS

The authors thank Fernanda Lübe for her kind help drawing the surgery techniques.

**No financial support.  
No conflict of interest.**

**Authors' Roles & Responsibilities**

<b>MCJ</b>	<b>Substantial contributions to the conception or design of the work; or the acquisition, analysis, or interpretation of data for the work; drafting the work or revising it critically for important intellectual content; agreement to be accountable for all aspects of the work in ensuring that questions related to the accuracy or integrity of any part of the work are appropriately investigated and resolved; final approval of the version to be published</b>
<b>CNM</b>	<b>Substantial contributions to the conception or design of the work; or the acquisition, analysis, or interpretation of data for the work; drafting the work or revising it critically for important intellectual content; agreement to be accountable for all aspects of the work in ensuring that questions related to the accuracy or integrity of any part of the work are appropriately investigated and resolved; final approval of the version to be published</b>
<b>BGF</b>	<b>Substantial contributions to the conception or design of the work; or the acquisition, analysis, or interpretation of data for the work; drafting the work or revising it critically for important intellectual content; agreement to be accountable for all aspects of the work in ensuring that questions related to the accuracy or integrity of any part of the work are appropriately investigated and resolved; final approval of the version to be published</b>
<b>CPFR</b>	<b>Substantial contributions to the conception or design of the work; or the acquisition, analysis, or interpretation of data for the work; drafting the work or revising it critically for important intellectual content; agreement to be accountable for all aspects of the work in ensuring that questions related to the accuracy or integrity of any part of the work are appropriately investigated and resolved; final approval of the version to be published</b>
<b>ECV</b>	<b>Substantial contributions to the conception or design of the work; or the acquisition, analysis, or interpretation of data for the work; drafting the work or revising it critically for important intellectual content; agreement to be accountable for all aspects of the work in ensuring that questions related to the accuracy or integrity of any part of the work are appropriately investigated and resolved; final approval of the version to be published</b>
<b>FA</b>	<b>Substantial contributions to the conception or design of the work; or the acquisition, analysis, or interpretation of data for the work; drafting the work or revising it critically for important intellectual content; agreement to be accountable for all aspects of the work in ensuring that questions related to the accuracy or integrity of any part of the work are appropriately investigated and resolved; final approval of the version to be published</b>

**REFERENCES**

1. Kutsche LM, Van Mierop LH. Anomalous origin of a pulmonary artery from the ascending aorta: associated anomalies and pathogenesis. *Am J Cardiol.* 1988;61(10):850-6. doi:10.1016/0002-9149(88)91078-8.

2. Dong S, Yan J, Xu H, Duan Y, Liu C. The surgical treatment of anomalous origin of one pulmonary artery from the ascending aorta. *J Cardiothorac Surg.* 2019;14(1):82. doi:10.1186/s13019-019-0904-0.

3. Abu-Sulaiman RM, Hashmi A, McCrindle BW, Williams WG, Freedom RM. Anomalous origin of one pulmonary artery from the ascending aorta: 36 years' experience from one centre. *Cardiol Young.* 1998;8(4):449-54. doi:10.1017/s1047951100007101.

4. Cho S, Kim WH, Choi ES, Lee JR, Kim YJ. Surgical results of anomalous origin of one pulmonary artery branch from the ascending aorta. *Pediatr Cardiol.* 2015;36(7):1532-8. doi:10.1007/s00246-015-1197-2.

5. de Albuquerque AM, Ebaid M, Barbero-Marcial M. Aortic origin of right pulmonary artery: early detection by cross-sectional and color-Doppler-echocardiography in two infants submitted to successful surgical repair. *Int J Cardiol.* 1989;24(2):225-7. doi:10.1016/0167-5273(89)90308-2.

6. Fong LV, Anderson RH, Siewers RD, Trento A, Park SC. Anomalous origin of one pulmonary artery from the ascending aorta: a review of echocardiographic, catheter, and morphological features. *Br Heart J.* 1989;62(5):389-95. doi:10.1136/hrt.62.5.389.

7. Wang J, Song Y, Cheng TO, Xie M, Wang X, Yuan L, et al. The value of transthoracic echocardiography in the diagnosis of anomalous origin of the right pulmonary artery from the ascending aorta: a single center experience from China. *Int J Cardiol.* 2015;184:750-4. doi:10.1016/j.ijcard.2015.02.085.

8. Rivera IR, Moisés VA, Silva CC, Leal SB, Maluf MA, Andrade JL, et al. Origem Anômala da artéria pulmonar direita em aorta ascendente (Hemitruncus). *Arq Bras Cardiol.* 1998;70(5):341-4. doi:10.1590/s0066-782x1998000500007.

9. Amaral F, Teixeira MAC, Granzotti JA, Manso PH, Vicente WVA. Origem anômala da artéria pulmonar esquerda da aorta. Correção cirúrgica bem sucedida em lactente com Tetralogia de Fallot. *Arq Bras Cardiol.* 2002;79(5):538-43.

10. Santos MA, Azevedo VM. Anomalous origin of a pulmonary artery from the ascending aorta: surgical repair resolving pulmonary arterial hypertension. *Arq Bras Cardiol.* 2004;83(6):503-7; 498-502. doi:10.1590/s0066-782x2004001800008.

11. Amir G, Frenkel G, Bruckheimer E, Dagan T, Katz J, Berant M, et al. Anomalous origin of the pulmonary artery from the aorta: early diagnosis and repair leading to immediate physiological correction. *Cardiol Young.* 2010;20(6):654-9. doi:10.1017/S1047951110000892.

12. Xie L, Gao L, Wu Q, Huang C, Yang JF, Zhao TL, et al. Anomalous origin of the right pulmonary artery from the ascending aorta: results of direct implantation surgical repair in 6 infants. *J Cardiothorac Surg.* 2015;10:97. doi:10.1186/s13019-015-0307-9.

13. Prifti E, Bonacchi M, Murzi B, Crucean A, Leacche M, Bernabei M, et al. Anomalous origin of the right pulmonary artery from the ascending aorta. *J Card Surg.* 2004;19(2):103-12. doi:10.1111/j.0886-0440.2004.04023.x.

14. Peng EW, Shanmugam G, Macarthur KJ, Pollock JC. Ascending aortic origin of a branch pulmonary artery--surgical management and long-term outcome. *Eur J Cardiothorac Surg.* 2004;26(4):762-6. Erratum in: *Eur J Cardiothorac Surg.* 2007;32(5):826. doi:10.1016/j.ejcts.2004.07.007.



This is an open-access article distributed under the terms of the Creative Commons Attribution License.