



Revista Estomatológica Herediana

ISSN: 1019-4355

ISSN: 2225-7616

faest.revista@oficinas-upch.pe

Universidad Peruana Cayetano Heredia

Perú

Valverde Haro, Henry Paul; Erazo Conde, Adriana Denisse
Endodontic management of a mandibular incisor with severe canal obliteration: a case report
Revista Estomatológica Herediana, vol. 35, no. 1, 2025, January-March, pp. 59-64
Universidad Peruana Cayetano Heredia
Lima, Perú

DOI: <https://doi.org/10.20453/reh.v35i1.5389>

Available in: <https://www.redalyc.org/articulo.oa?id=421582744007>

- ▶ [How to cite](#)
- ▶ [Complete issue](#)
- ▶ [More information about this article](#)
- ▶ [Journal's webpage in redalyc.org](#)

redalyc.org

Scientific Information System Redalyc

Diamond Open Access scientific journal network

Non-commercial open infrastructure owned by academia

Endodontic management of a mandibular incisor with severe canal obliteration: a case report

 Henry Paul Valverde Haro^{1,2,a},

 Adriana Denisse

Erazo Conde^{2,b}

¹ Universidad Hemisferios.
Quito, Ecuador.

² ENDOsolutions Research
Group. Riobamba, Ecuador.

^a Master's Degree in Endodontics.

^b Second professional specialty
in Dental Prosthetics.

ABSTRACT

One of the physiological procedures associated with injuries to the dental pulp is root canal obliteration, characterized by partial or total narrowing of the canal, making its access or localization challenging. With today's technology, digital planning of the access cavity, using minimally invasive techniques through CBCT and intraoral scanning of the patient's mouth, improves this complex clinical situation. This case involves a 66-year-old patient with dyschromia of the lower central incisor, a history of dental trauma, and a positive response to percussion testing, with pulp necrosis and symptomatic apical periodontitis. A three-dimensional impression of an endodontic access guide was made. The root canal was then permeabilized in a controlled manner and the canal was located using a minimally invasive approach. The root canal was treated conventionally. Clinical and radiographic follow-up after one year demonstrated the effectiveness of using a static guide for endodontic treatment in cases of severe obliteration.

Keywords: dental calcification; access cavity preparation; cone beam computed tomography; three-dimensional impression; dental trauma.

Received: May 02, 2024

Accepted: December 17, 2024

Online: March 31, 2025



Open access article

© The authors

© Revista Estomatológica Herediana

Cite as:

Valverde HP, Erazo AD. Endodontic management of a mandibular incisor with severe canal obliteration: a case report. Rev Estomatol Herediana. 2025; 35(1): 51-55. DOI: 10.20453/reh.v35i1.5389

INTRODUCTION

One of the physiological processes associated with damage to the dental pulp is root canal obliteration, where partial or total narrowing of the canal is observed, making it difficult to access or locate (1, 2). Many of these cases are asymptomatic and are detected by routine auxiliary imaging, such as periapical radiographs, panoramic radiographs, and cone beam computed tomography (CBCT) (3).

When pulp or periapical pathology is present in teeth with root canal obliteration, the degree of complexity increases to the point of becoming a challenge for the clinician. Therefore, there is a high risk of procedural error in the effort to locate the root canal (4). With current technology, the ideal approach is to perform digital planning using an intraoral scan of the patient's mouth and CBCT, in order to achieve conservative access, locating the root canal in a minimally invasive manner (5). This procedure is called guided endodontics and is presented as a treatment alternative for obliterated teeth, reducing treatment time and significantly decreasing procedural errors (6, 7).

Today, 3D printing in dentistry is widely used in endodontics for the production of static guides, surgical guides, and three-dimensional replication of teeth for dental autotransplantation procedures, providing a fast, accurate, safe, and increasingly inexpensive alternative in the manufacturing process (8).

This case report presents a guided endodontic treatment of a severely obliterated lower central incisor with periapical pathology.

CASE PRESENTATION

A 66-year-old male patient attended an endodontic consultation due to constant pain during chewing and palpation in a lower central incisor with dental disco-

location. The patient's medical history included controlled hypertension, and his dental history included dental trauma more than three years prior.

The mandibular central incisor showed a positive response to both vertical and horizontal percussion tests and no response to the thermal pulp vitality test. The initial periapical radiograph (Figure 1A) showed severe obliteration of the root canal at the level of the pulp chamber and root, compared to the adjacent central and lateral incisors. Tooth #41 showed radiographic evidence of apical periodontitis. A maxillary CBCT scan with a 16×18 cm FOV was performed using a tomograph (GIANO HR, NewTom®, Imola, Italy). The tomographic images confirmed the presence of severe canal calcification and periapical pathology (Figure 2).

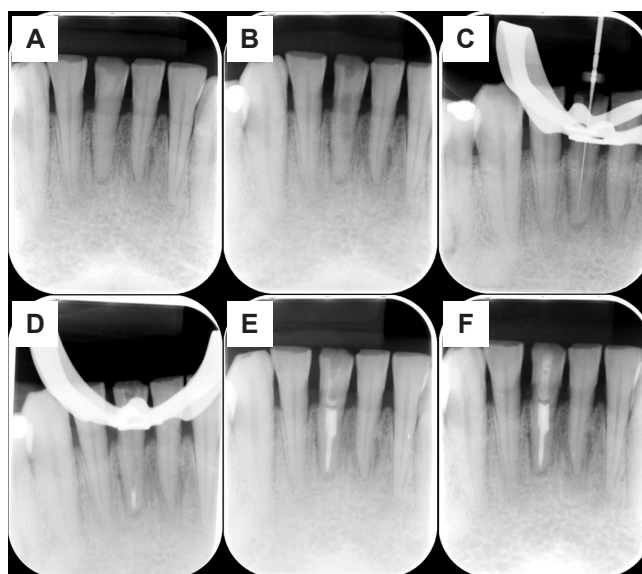


Figure 1. Radiographic control: A) Initial periapical radiograph showing complete obliteration of the canal; B) Control radiograph of endodontic access with ATEC bur to the middle third; C) Control radiograph of conductometry with K10 file; D) Control radiograph of continuous wave heat technique conometry; E) Control radiograph of root canal filling; F) Control periapical radiograph one year after treatment.

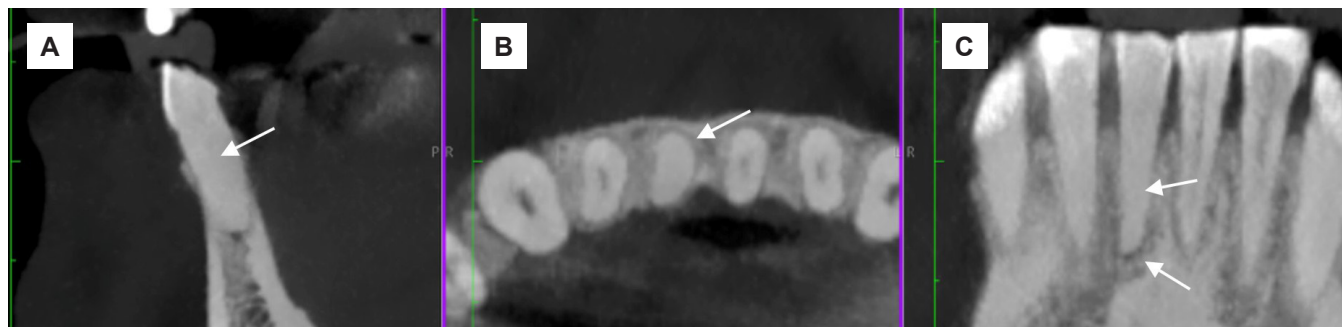

Figure 2. Observation of severe obliteration and periapical pathology in CBCT: A) Observation of severe obliteration in the sagittal section; B) Observation of severe obliteration in the axial section; C) Observation of severe obliteration in the transaxial section and presence of periapical pathology.

The definitive pulp diagnosis was pulp necrosis and the periapical diagnosis was symptomatic apical periodontitis. Root canal treatment was proposed using a static endodontic guide to reduce the risk of procedural error. As an alternative contingency treatment, the patient was informed of the possibility of tooth extraction. The patient opted for the first proposal to preserve his permanent tooth.

Using an intraoral scanner (Helios 600, Eighteeth®, Changzhou, China), a digital model of the patient's dental arch was created and exported as an STL file. The two files (CBCT and STL) were processed with software (Romexis® 3D implantology, Planmeca, Helsinki, Finland), then aligned and the access planned with a 1.0 mm diameter and 21 mm long ATEC bur (Endoseal®, Steco, Hamburg, Germany). The bur was superimposed on the middle third of the root. The guide was designed with a hole for inserting a 5 mm titanium sleeve and a 1 mm entry hole diameter (Endo Sleeve, Steco®, Hamburg, Germany) and exported as an STL file for reproduction on a 3D printer (Figure 3A).

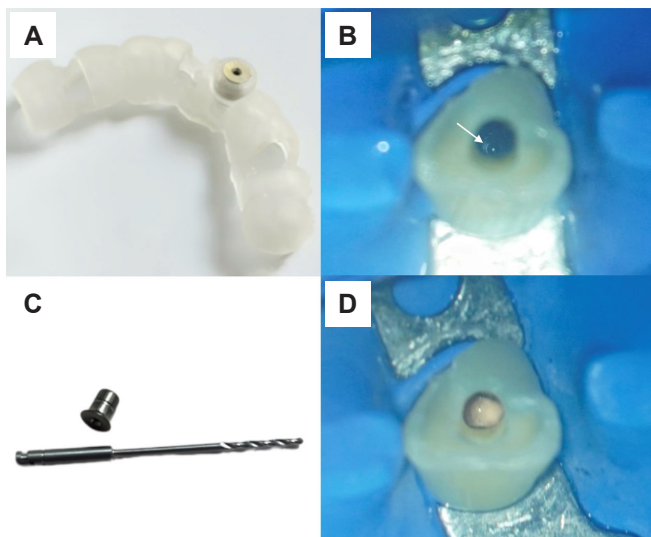


Figure 3. Clinical images of the procedure and endodontic guide: A) Static endodontic guide with titanium cap installed; B) Location of the root canal; C) ATEC 28 mm bur and 5 mm titanium cap; D) Three-dimensional filling of the root canal.

Informed consent was obtained from the patient, and the guide was tested to verify its correct fit on the incisal surfaces of the mandibular anterior teeth. Local infiltrative anesthesia with a vasoconstrictor was administered, and a mark was made through the guide to identify the access point with a pencil lead. The enamel was removed in a minimally invasive manner until the dentin was exposed, using a round diamond bur (1014, Microdont®, Sao Paulo, Brazil). Next, the ATEC bur (Figure 3C) was fitted to an endodontic motor with a rotation speed of 1000 rpm and 2.5 Ncm of torque; and access was gained to the middle third of the root, with abundant irrigation

and inward and outward movements, until the reference point marked on the ATEC bur was reached. A control radiograph of the access was taken (Figure 1B).

Preparation of the access took approximately 10 minutes. The tooth was then completely isolated for conventional endodontic treatment (Figure 3B). Using 1.6x magnification with a surgical microscope (RM-2000 Plus, Rogin Dental®, Shenzhen, China), the canal was located using a DG16 endodontic explorer and 25 mm preserie files (K08 and K10, Maillefer®, Ballaigues, Switzerland). A periapical conductometry radiograph was taken to verify access to the root canal (Figure 1C). Subsequently, it was irrigated with 5.25% sodium hypochlorite and instrumented with a reciprocating system up to an R40 (Reciproc, VDW®, Munich, Germany). A final sonic activation was performed with the tip (Eddy, VDW, Munich, Germany) with 5 one-minute intervals of 5.25% sodium hypochlorite, irrigation with 5 mL of saline solution, and a one-minute interval of ethylenediaminetetraacetic acid solution (EDTA 18%, Ultradent®, South Jordan, USA).

Next, a final irrigation with 5 mL of saline solution was performed. The procedure was completed using sterile cones (Reciproc, VDW®, Munich, Germany) for drying. The filling was performed with a 40/04 master cone (gutta-percha points; Coltene®, Langenau, Germany) using epoxy amino resin-based root canal sealing cement (AH Plus, Dentsply®, Erlangen, Germany). A control radiograph of the filling was taken at the apical third (Figure 1D) and, using the continuous wave heat technique (Beefill 2 in 1; VDW®, Munich, Germany), the filling was completed up to the chamber third of the root canal. The access cavity was cleaned with cotton moistened with ethanol, and the endodontic filling was sealed with flowable resin (Figure 3D).

Radiographic checks were performed during all phases of treatment, carried out in a single session, observing adequate three-dimensional filling up to the working length (Figure 1E). Follow-up was performed one year after endodontic treatment, with the result being the absence of symptoms and periapical bone neoformation (Figure 1F).

DISCUSSION

The diagnosis and individualization of endodontic treatments are essential for the healing and prevention of pulp and periapical pathologies (9). Although most mandibular incisors tend to have internal morphological symmetries and few anatomical variations, they continue to pose a challenge for root canal treatment (10).

In the case of a tooth with an obliterated canal, its longitudinal axis serves as a reference for accessing the

root canal (6). Attempts have been made to perform this type of procedure conventionally using ultrasound and a dental surgical microscope (11). In this type of therapeutic approach, due to the high risk of procedural errors and the internal anatomical complexity of obliterated canals, the use of CBCT during endodontic treatment planning is justified, providing more benefits than risks in terms of increased patient exposure to radiation, compared to periapical radiographs (12-15).

Guided endodontics minimizes dentin wear and reduces the potential risk of procedural errors, while preserving as much healthy dental tissue as possible (16). In the present case report, there were limitations due to severe canal obliteration; therefore, wear was performed on the mesial wall of the root canal during the procedure due to the lack of a precise reference to determine where the canal could be located at the apical third of the root during digital planning of the static guide. However, this limitation was overcome with the help of magnification achieved with the microscope, which allowed observation of the canal entrance prior to the removal of dentin debris with irrigating solutions. The apical third of the root canal was accessed using pre-series files. Therefore,

it is recommended to use guided endodontic burs and a titanium cap inserted into the three-dimensional impression of the guide to avoid unwanted movements during treatment (17).

When the tooth to be treated has no adjacent teeth, it is recommended to stabilize the guide with bone anchors (15, 17, 18); however, in this case, it was not necessary because good stability was observed at the level of the adjacent teeth, which reduced the likelihood of unwanted movements during the procedure. Therefore, guided endodontics is a novel procedure for the treatment of obliterated teeth. Further research and innovation are needed in access burs, reducing their diameters and resistance during preparation, as limitations can cause alterations in the original shape of the root canal (19).

CONCLUSION

This case report demonstrated the effectiveness of using a static guide for endodontic treatment of a canal with severe obliteration.

Conflict of interest:

The authors declare no conflict of interest.

Funding:

Self-funded.

Ethics approval:

Informed consent was obtained from the patient.

Author contributions:

HPVH: conceptualization, methodology, original draft writing.

ADEC: research, software, visualization, writing (review and editing).

Corresponding author:

Henry Paul Valverde Haro

✉ Henry.valverde@upch.pe

REFERENCES

1. Yang X, Zhang Y, Chen X, Huang L, Qiu X. Limitations and management of dynamic navigation system for locating calcified canals failure. *J Endod* [Internet]. 2024; 50(1): 96-105. Available from: <https://doi.org/10.1016/j.joen.2023.10.010>
2. Jiandong B, Yunxiao Z, Zuhua W, Yan H, Shuangshuang G, Junke L, et al. Generalized pulp canal obliteration in a patient on long-term glucocorticoids: a case report and literature review. *BMC Oral Health* [Internet]. 2022; 22: 352. Available from: <https://doi.org/10.1186/s12903-022-02387-9>
3. Chan F, Brown LF, Parashos P. CBCT in contemporary endodontics. *Aust Dent J* [Internet]. 2023; 68(S1): S39-S55. Available from: <https://doi.org/10.1111/adj.12995>
4. Connert T, Weiger R, Krastl G. Present status and future directions - Guided endodontics. *Int Endod J* [Internet]. 2022; 55(S4): 995-1002. Available from: <https://doi.org/10.1111/iej.13687>
5. Tavares WL, Pedrosa NO, Moreira RA, Braga T, Machado VC, Sobrinho AP, et al. Limitations and management of static-guided endodontics failure. *J*

- Endod [Internet]. 2022; 48(2): 273-279. Available from: <https://doi.org/10.1016/j.joen.2021.11.004>
6. Krastl G, Zehnder MS, Connert T, Weiger R, Kühl S. Guided endodontics: a novel treatment approach for teeth with pulp canal calcification and apical pathology. *Dent Traumatol* [Internet]. 2016; 32(3): 240-246. Available from: <https://doi.org/10.1111/edt.12235>
 7. Pujol ML, Vidal C, Mercadé M, Muñoz M, Ortolani-Seltenerich S. Guided endodontics for managing severely calcified canals. *J Endod* [Internet]. 2021; 47(2): 315-321. Available from: <https://doi.org/10.1016/j.joen.2020.11.026>
 8. Strbac GD, Schnappauf A, Giannis K, Bertl MH, Moritz A, Ulm C. Guided autotransplantation of teeth: a novel method using virtually planned 3-dimensional templates. *J Endod* [Internet]. 2016; 42(12): 1844-1850. Available from: <https://doi.org/10.1016/j.joen.2016.08.021>
 9. Wolf TG, Stiebritz M, Boemke N, Elsayed I, Paqué F, Wierichs RJ, et al. 3-dimensional analysis and literature review of the root canal morphology and physiological foramen geometry of 125 mandibular incisors by means of micro-computed tomography in a German population. *J Endod* [Internet]. 2020; 46(2): 184-191. Available from: <https://doi.org/10.1016/j.joen.2019.11.006>
 10. Sevgi U, Johnsen GF, Hussain B, Piasecki L, Nogueira LP, Haugen HJ. Morphometric micro-CT study of contralateral mandibular incisors. *Clin Oral Investig* [Internet]. 2024; 28: 20. Available from: <https://doi.org/10.1007/s00784-023-05419-y>
 11. Karobari MI, Iqbal A, Syed J, Batul R, Adil AH, Khawaji SA, et al. Evaluation of root and canal morphology of mandibular premolar amongst Saudi subpopulation using the new system of classification: a CBCT study. *BMC Oral Health* [Internet]. 2023; 23: 291. Available from: <https://doi.org/10.1186/s12903-023-03002-1>
 12. Alamoudi RA, Alzayer FM, Alotaibi RA, Alghamdi F, Zahran S. Assessment of the correlation between systemic conditions and pulp canal calcification: a case-control study. *Cureus* [Internet]. 2023; 15(9): e45484. Available from: <https://doi.org/10.7759/cureus.45484>
 13. Shaban A, Elsewify TM, Hassanein EE. Multiple endodontic guides for root canal localization and preparation in furcation perforations: a report of two cases. *Iran Endod J* [Internet]. 2023; 18(1): 65-70. Available from: <https://doi.org/10.22037/iej.v18i1.39498>
 14. Kolarkodi SH. The importance of cone-beam computed tomography in endodontic therapy: a review. *Saudi Dent J* [Internet]. 2023; 35(7): 780-784. Available from: <https://doi.org/10.1016/j.sdentj.2023.07.005>
 15. Casadei BA, Lara-Mendes ST, Barbosa CF, Araújo CV, Freitas CA, Machado VC, et al. Access to original canal trajectory after deviation and perforation with guided endodontic assistance. *Aust Endod J* [Internet]. 2019; 46(1): 101-106. Available from: <https://doi.org/10.1111/aej.12360>
 16. Hegde SG, Tawani G, Warhadpande M, Raut A, Dakshindas D, Wankhade S. Guided endodontic therapy: management of pulp canal obliteration in the maxillary central incisor. *J Conserv Dent* [Internet]. 2019; 22(6): 607-611. Available from: https://journals.lww.com/jcde/fulltext/2019/22060/guided_endodontic_therapy__management_of_pulp.21.aspx
 17. Lara-Mendes ST, Barbosa CF, Machado VC, Santa-Rosa CC. A new approach for minimally invasive access to severely calcified anterior teeth using the guided endodontics technique. *J Endod* [Internet]. 2018; 44(10): 1578-1582. Available from: <https://doi.org/10.1016/j.joen.2018.07.006>
 18. Lara-Mendes ST, Barbosa CF, Santa-Rosa CC, Machado VC. Guided endodontic access in maxillary molars using cone-beam computed tomography and computer-aided design/computer-aided manufacturing system: a case report. *J Endod* [Internet]. 2018; 44(5): 875-879. Available from: <https://doi.org/10.1016/j.joen.2018.02.009>
 19. Nayak A, Jain PK, Kankar PK, Jain N. Computer-aided design-based guided endodontic: a novel approach for root canal access cavity preparation. *Proc Inst Mech Eng H* [Internet]. 2018; 232(8): 787-795. Available from: <https://doi.org/10.1177/0954411918788104>