



Revista Estomatológica Herediana

ISSN: 1019-4355

ISSN: 2225-7616

faest.revista@oficinas-upch.pe

Universidad Peruana Cayetano Heredia

Perú

Ramírez Suarez, Reynier; Morales Paz, Yanara R.; Morales Basulto, René  
Traumatic oral fibroma of unusual size: a case report  
Revista Estomatológica Herediana, vol. 35, no. 1, 2025, January-March, pp. 65-70  
Universidad Peruana Cayetano Heredia  
Lima, Perú

DOI: <https://doi.org/10.20453/reh.v35i1.6378>

Available in: <https://www.redalyc.org/articulo.oa?id=421582744009>

- ▶ [How to cite](#)
- ▶ [Complete issue](#)
- ▶ [More information about this article](#)
- ▶ [Journal's webpage in redalyc.org](#)


redalyc.org

Scientific Information System Redalyc

Diamond Open Access scientific journal network

Non-commercial open infrastructure owned by academia

## Traumatic oral fibroma of unusual size: a case report

 Reynier Ramírez Suarez<sup>1,2, a, b</sup>,

 Yanara R. Morales Paz<sup>3,4, c</sup>,

 René Morales Basulto<sup>1,5, a, b</sup>

<sup>1</sup> Universidad de Ciencias Médicas de Camagüey, Faculty of Stomatology. Camagüey, Cuba.

<sup>2</sup> Hospital Universitario Manuel Ascunce Domenech de Camagüey, Department of Maxillofacial Surgery. Camagüey, Cuba.

<sup>3</sup> Universidad de Ciencias Médicas de Camagüey, Faculty of Medicine. Camagüey, Cuba.

<sup>4</sup> Hospital Universitario Manuel Ascunce Domenech de Camagüey, Department of Anesthesiology and Resuscitation. Camagüey, Cuba.

<sup>5</sup> Hospital Clínico Quirúrgico Docente Martín Chang Puga, Department of Maxillofacial Surgery. Camagüey, Cuba.

<sup>a</sup> Dentist.

<sup>b</sup> Maxillofacial surgeon.

<sup>c</sup> Physician.

### ABSTRACT

Traumatic fibromas are frequently found in the oral cavity. They are characterized by a localized proliferation of dense collagen fibers resulting from regional trauma, rather than representing a true neoplasm. This case report describes a patient with a clinical and histopathological diagnosis of traumatic fibroma, in which the lesion presented a considerable and unusual growth, leading to facial asymmetry. The lesion, with several months of evolution, showed a significant size, for which the therapeutic approach consisted of total excision. After one year of follow-up, there was no recurrence of the lesion. Surgical excision was considered for the treatment of traumatic oral fibroma. It is concluded that it is important to identify the etiologic factor and proceed with its elimination to avoid recurrence.

**Keywords:** benign neoplasm; fibroma; oral cavity.

**Received:** May 02, 2024

**Accepted:** December 10, 2024

**Online:** March 31, 2025



Open access article

© The authors

© Revista Estomatológica Herediana

### Cite as:

Ramírez R, Morales YR, Morales R. Traumatic oral fibroma of unusual size: a case report. Rev Estomatol Herediana. 2025; 35(1): 57-61. DOI: 10.20453/reh.v35i1.6378

## INTRODUCTION

Fibroma is defined as the most common benign neoplasm of the oral cavity. Although there is still some uncertainty about its neoplastic origin, it is generally accepted that it represents a reactive hyperplasia of fibrous connective tissue in response to local or traumatic irritation (1). Traumatic fibroma is also known as focal fibrous hyperplasia, irritative fibroma, fibroepithelial nodule, oral fibroma, fibrous nodule, or oral polyp, and it is considered a non-cancerous active injury that develops secondary to regional damage (2).

The main irritants that give rise to traumatic fibroma include occlusal trauma, misaligned teeth, sharp edges, defective restorations, dental calculus, or habits such as lip biting (2). It is more common in women between the fourth and sixth decades of life (1). The differential diagnoses of traumatic fibroma include fibroma, myxoma, lipoma, and pleomorphic adenoma (3).

The therapeutic approach should correspond to the severity of the lesion and the amount of affected tissue. For small lesions, conservative treatment with removal of the causative agent may be applied (4). The objective of this report is to present a clinical case of a patient with a clinical and histopathological diagnosis of traumatic fibroma, in which the lesion exhibited considerable and unusual growth, resulting in facial asymmetry.

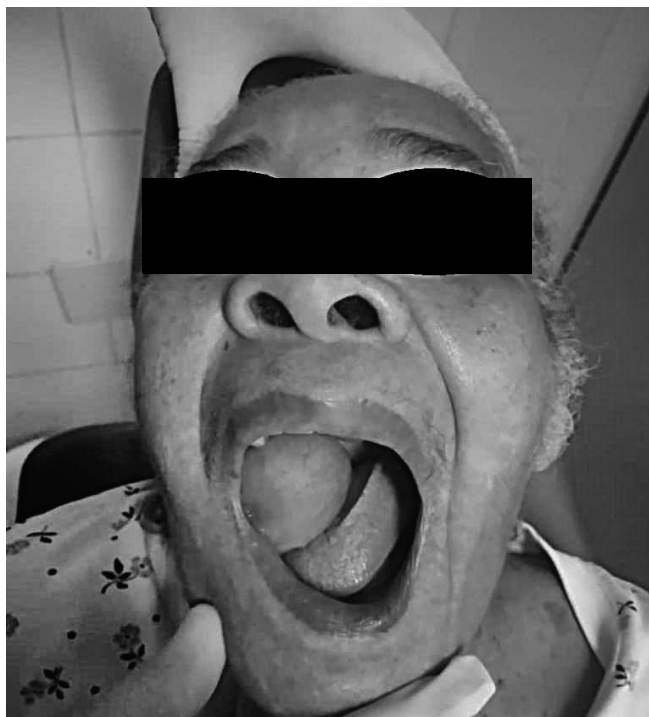## CASE PRESENTATION

An 86-year-old female patient of African descent from a rural area presented to the Department of Maxillo-facial Surgery, Hospital Universitario Manuel Ascunce Domenech de Camagüey, due to an intraoral lesion of approximately two years of evolution, with progressive growth in recent months that caused masticatory difficulty and prevented proper mouth closure. During anamnesis, the patient denied any history of systemic diseases or drug allergies.

On physical examination, facial asymmetry was observed due to a volume increase in the right buccal region. Oral examination revealed a tumor-like lesion measuring 5 × 5 × 6 cm, with a pedunculated base and firm-elastic consistency. The pedicle's base corresponded to an area of trauma on the right buccal mucosa caused by occlusal contact at the level of the premolars, which showed defective restorations and grade III mobility. The lesion caused flattening of the half of the tongue corresponding to the site where the lesion was located (Figure 1).

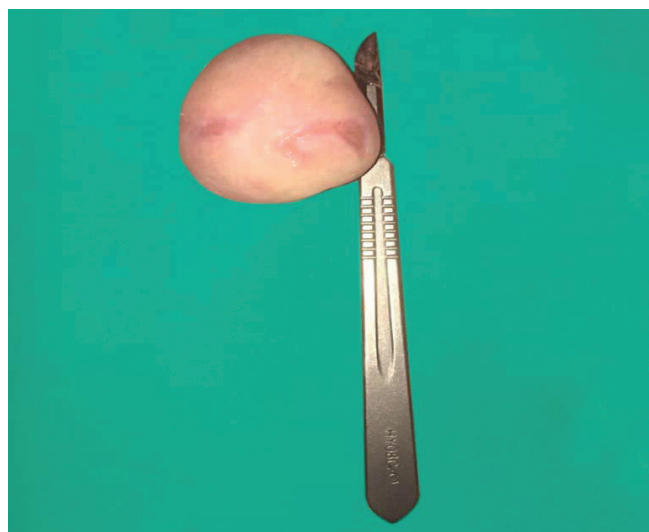
After the differential diagnosis was performed, a presumptive diagnosis of traumatic fibroma was established for the lesion that prompted the consultation, along with periodontitis affecting the premolars. Basic preoperative

studies were requested, including complete blood count and bleeding and coagulation times, all within normal parameters. Informed consent was obtained from the patient, and surgical excision of the lesion along with the affected premolars was scheduled.



**Figure 1.** Tumor-like lesion with a pedunculated base and firm-elastic consistency was observed on the right buccal mucosa, showing flattening of the ipsilateral half of the tongue.

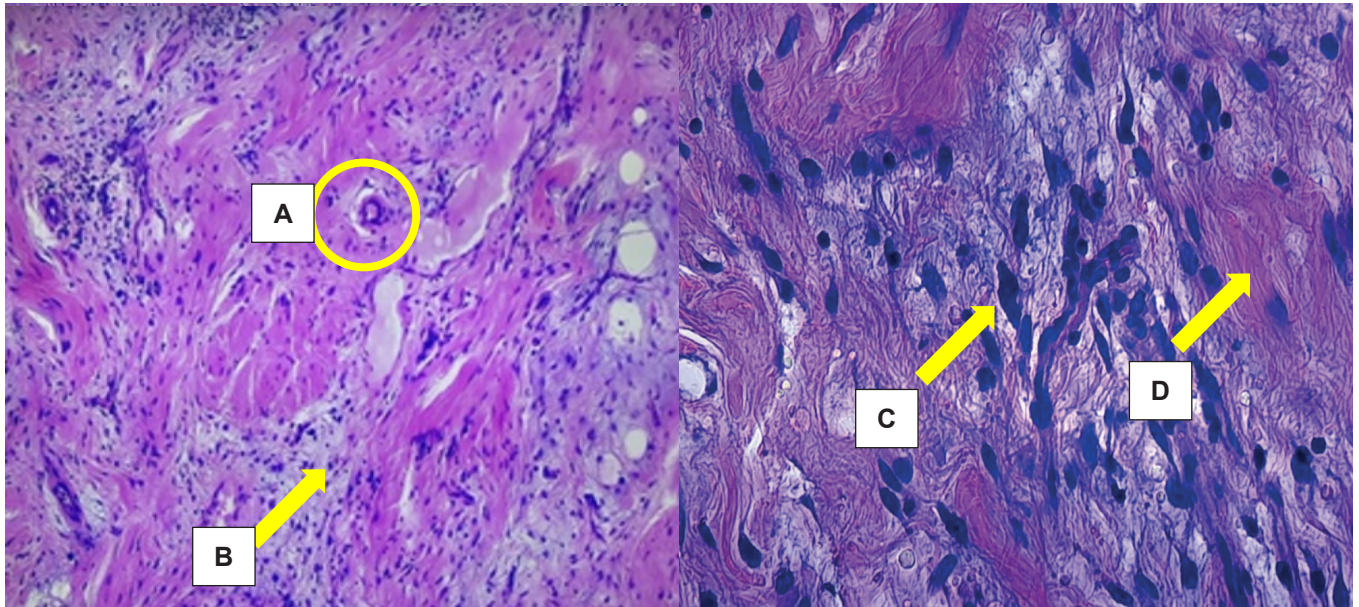
The surgery was performed under local anesthesia using the infiltration technique with 2% lidocaine with epinephrine. An elliptical incision was made at the base of the lesion, followed by its excision and suturing with 3-0 silk (Figure 2).



**Figure 2.** Macroscopic appearance of the 5.5 cm lesion showing well-defined borders and large size.

Subsequently, exodontia of the premolars was performed. Paracetamol was prescribed, one 500 mg tablet every eight hours in the immediate postoperative period, along with general dietary and oral hygiene

recommendations. The specimen was sent to the Department of Pathological Anatomy for analysis, whose report confirmed the diagnosis of traumatic oral fibroma (Figure 3).



**Figure 3.** Histopathological appearance of the lesion under optical microscopy showing: blood vessels representing vascular congestion (A); inflammatory infiltrate with the presence of lymphocytes (B); and dense fibrous connective tissue with abundant mature collagen interspersed with fibroblasts (C, D). Staining used: hematoxylin/eosin (H&E), at 20× and 40× magnification.

The patient was followed up in consultation for two years, during which no recurrence of the lesion was observed, and the surgical site showed favorable healing.

## DISCUSSION

Traumatic fibromas are growths frequently found in the oral cavity, accounting for 4.5% of all oral mucosal lesions (4). It is a localized proliferation of dense collagen fibers resulting from trauma (2).

The etiopathogenesis of traumatic fibroma is associated with local injuries (2, 3). Initially, when the lesion becomes chronic, it induces reparative inflammatory processes; if it persists, the causative agent accumulates collagen produced by fibroblasts. This leads to the formation of an acellular scar-like tissue with greater firmness and paleness compared to the adjacent mucosa (2, 4).

It is more frequent in areas vulnerable to chronic trauma caused by chewing or toothbrushing, or the use of orthodontic appliances or complete prostheses (5). In the reported case, the lesion was caused by direct trauma from teeth in poor condition. López-Labady et al. (5) reported a patient with a lesion diagnosed as a traumatic oral fibroma triggered by a bite injury.

The most affected sites are the buccal mucosa, tongue, lip, hard palate, and gingiva (5). Typically, these lesions present as solitary nodules, though multiple lesions may occur (6, 7). Clinically, they most frequently appear as a well-defined tissue growth with a smooth surface, generally covered by mucosa of normal color, with a sessile or pedunculated base, firm consistency, and measuring less than 1.5 cm in its greatest diameter (8). These lesions are usually characterized by slow and painless growth that develops over a period of months or years (6).

In this report, the patient's lesion exceeded the usual size reported in the literature, even surpassing the 4.5 cm traumatic fibroma reported by Chacón-Uscamaita et al. (4), as well as the giant oral fibromas of the buccal mucosa presented by Labrada & Montaña (9), which measured 3 × 1 cm and 2.5 × 1 cm.

The histopathological characteristic of irritation fibroma is presented as a nodular mass composed of collagenized fibrous connective tissue. The epidermis usually shows hyperplasia and hyperkeratosis due to chronic irritation. In the connective tissue, dense collagen fibers can be found (10-12). It should be differentiated from other entities that present as growths in the oral cavity, such as papilloma, mucocele, lipoma, various types of granulomas, neurofibroma, neurilemmoma, rhabdom-

yoma, leiomyoma, the peripheral variant of odontogenic tumors, and the different hyperplastic processes that affect the oral mucosa (inflammatory fibrous hyperplasia, drug-induced hyperplasia, inflammatory papillary hyperplasia), as well as squamous cell carcinoma (4).

Complete surgical excision has been considered, due to its relevance, as the preferred treatment for fibromas (6). The most common approach is surgical enucleation with a scalpel to ensure total excision of the lesion with safety margins; however, it has disadvantages, including intraoperative bleeding, the need for suturing, and the possibility of edema (2). Farheen et al. (1) reported the treatment of lingual traumatic fibroma using a diode laser. Electrosurgery and cryosurgery are also considered therapeutic modalities (2). Recurrence of traumatic fibromas is rare, but it cannot be ruled out if the irritating factor or etiologic agent has not been eliminated (5,

13). In the present case, complete excision of the lesion was performed, and there was no recurrence during the two-year follow-up period. A limitation of this study is the absence of postoperative images.

## CONCLUSIONS

Traumatic fibroma is a common lesion in the oral cavity. A clinical case was reported regarding the diagnosis and management of a patient with this lesion, which was associated with local injury and reached an unusual size, affecting the patient's function and aesthetics. The lesion and the causative agent were eliminated, in this case, the exodontia of the teeth responsible for the trauma. Surgical excision is the ideal treatment for traumatic oral fibroma. It is important to identify and eliminate the etiologic factor to prevent recurrence.

### Conflict of interest:

The authors declare no conflict of interest.

### Funding:

Self-funded.

### Ethics approval:

This article was approved by the Ethics Committee of the Department of Maxillofacial Surgery, Hospital Universitario Manuel Ascunce Domenech de Camagüey, on March 5, 2024. The patient also provided informed consent for the publication of this case.

### Author contributions:

**RRS:** conceptualization, data curation, formal analysis, research, methodology, project administration, resources, software, supervision, validation, visualization, writing – original draft, writing – review & editing.

**YRMP:** conceptualization, data curation, research, methodology, resources, validation, writing – original draft, writing – review & editing.

**RMB:** conceptualization, data curation, formal analysis, research, software, validation, visualization, writing – review & editing.

### Corresponding author:

Reynier Ramírez Suarez

✉ [reynieramirez93@gmail.com](mailto:reynieramirez93@gmail.com)

## REFERENCES

- Farheen, Madan E, Pati RC, Kumar V. Management of lingual traumatic fibroma in an epileptic patient using diode laser. *University J Dent Scie* [Internet]. 2023; 9(1): 64-67. Available from: <https://doi.org/10.21276//ujds.2023.9.1.13>
- Asundaria RR, Tavargeri A. Excision of traumatic fibroma of the tongue in a pediatric patient: a case report. *Int J Clin Pediatr Dent* [Internet]. 2023; 16(1): 166-169. Available from: <https://doi.org/10.5005/jp-journals-10005-2492>
- Diwan B, Shirbhate U, Bajaj P, Reche A, Pahade A. Conventional scalpel and diode laser approach for the management of traumatic fibroma. *Cureus* [Internet]. 2023; 15(10): e47810. Available from: <https://doi.org/10.7759/cureus.47810>
- Chacón-Uscamaita PR, Chávez-Rimache L, Mallma-Medina AS. [Traumatic Fibroid in Upper Lip Mucosa: Case Report]. *CES Odontol* [Internet]. 2021; 34(1): 136-144. Available from: <https://doi.org/10.21615/cesodon.34.1.13> Spanish.

5. López-Labady J, Villarroel M, Lazarde J, Rivera H. Fibroma traumático: revisión de la literatura y reporte de dos casos. *Acta Odontol Venez* [Internet]. 2000; 38(1): 47-49. Available from: [https://ve.scielo.org/scielo.php?script=sci\\_arttext&pid=S0001-63652000000100008](https://ve.scielo.org/scielo.php?script=sci_arttext&pid=S0001-63652000000100008)
6. Lalchandani CM, Tandon S, Rai TS, Mathur R, Kajal A. Recurrent irritation fibroma- "What lies beneath": a multidisciplinary treatment approach. *Int J Clin Pediatr Dent* [Internet]. 2020; 13(3): 306-309. Available from: <https://doi.org/10.5005/jp-journals-10005-1769>
7. Rivera C, Jones-Herrera C, Vargas P, Venegas B, Droguett D. Oral diseases: a 14-year experience of a Chilean institution with a systematic review from eight countries. *Med Oral Patol Oral Cir Bucal* [Internet]. 2017; 22(3): e297-e306. Available from: <https://doi.org/10.4317/medoral.21665>
8. Jiang M, Bu W, Chen X, Gu H. A case of irritation fibroma. *Adv Dermatol Allergol* [Internet]. 2019; 36(1): 125-126. Available from: <https://doi.org/10.5114/ada.2019.82834>
9. Labrada O, Montaña SM. [Giant fibroma of buccal mucosa. Presentation of two cases]. *Rev Cient Hallazgos21* [Internet]. 2019; 4(2): 215-220. Available from: <https://doi.org/10.69890/hallazgos21.v4i2.350> Spanish.
10. Silva-Mancera IC, Triana-Escobar FE, Soto-Llanos L. Excision of a traumatic fibroma with diode laser in a pediatric patient: case report. *Rev Fac Odontol Univ Antioq* [Internet]. 2019; 31(1-2): 162-170. Available from: <https://doi.org/10.17533/udea.rfo.v31n1-2a14>
11. Kumar A, Nagpal A, Nagpal B. Irritational fibroma – A case report. *Heal Talk* [Internet]. 2018; 11(4): 33. Available from: [https://www.researchgate.net/publication/332859825\\_Irritational\\_Fibroma\\_-\\_A\\_Case\\_Report](https://www.researchgate.net/publication/332859825_Irritational_Fibroma_-_A_Case_Report)
12. Prasanna S, Nandhini G, Rajkumar K. Traumatic fibroma in buccal mucosa: a case report and literature review. *MJDS* [Internet]. 2018; 3(2): 44-46. Available from: [https://www.researchgate.net/publication/339136534\\_Prasanna\\_S\\_et\\_al\\_Traumatic\\_fibroma\\_in\\_buccal\\_mucosa\\_A\\_case\\_report\\_and\\_literature\\_review\\_Traumatic\\_fibroma\\_in\\_buccal\\_mucosa\\_A\\_case\\_report\\_and\\_literature\\_review\\_S\\_Prasanna\\_G\\_Nandhini\\_K\\_Rajkumar](https://www.researchgate.net/publication/339136534_Prasanna_S_et_al_Traumatic_fibroma_in_buccal_mucosa_A_case_report_and_literature_review_Traumatic_fibroma_in_buccal_mucosa_A_case_report_and_literature_review_S_Prasanna_G_Nandhini_K_Rajkumar)
13. Jain G, Arora R, Sharma A, Singh R, Agarwal M. Irritation fibroma. Report of a case. *J Curr Res Sci Med* [Internet]. 2017; 3(2): 118-121. Available from: [https://journals.lww.com/jcsm/fulltext/2017/03020/irritation\\_fibroma\\_report\\_of\\_a\\_case.11.aspx](https://journals.lww.com/jcsm/fulltext/2017/03020/irritation_fibroma_report_of_a_case.11.aspx)