








DOI: <https://doi.org/10.20453/reh.v34i3.5837>

Photobiomodulation as adjuvant therapy for Bell's palsy: a case series

Fotobiomodulación como terapia coadyuvante para la parálisis de Bell: una serie de casos

Fotobiomodulação como terapia adjuvante para paralisia de Bell: uma série de casos

Fernanda Leme Silva¹ , Brenna Rodrigues Manzano¹ , Mailon Cury Carneiro¹ , Ludimila Lemes Moura¹ , Dayanne Simões Ferreira Santos² , Cássia Maria Fischer Rubira¹ , Paulo Sérgio da Silva Santos¹ 

ABSTRACT

This study evaluated the efficacy of low-level light therapy (LLLT) in the treatment of three patients with Bell's palsy (BP) and reviewed relevant literature. The first case involved a 52-year-old woman with grade V BP, who, after receiving pharmacological treatment and undergoing seven sessions of LLLT (780 nm; 70 mW; E = 9 J), improved to grade II within 21 days. The second case was a 37-year-old man who, having previously shown no response to treatment, received 24 sessions of LLLT and progressed from grade V to grade II over the course of 4 months. The third case involved a 40-year-old man who, following medication and eight sessions of LLLT, improved from grade V to grade I in 1.5 months. Overall, LLLT was found to significantly enhance facial function, aesthetics, and overall well-being in these patients within a relatively short period.

Keywords: adjuvant drug therapy; Bell's palsy; low level light therapy.

RESUMEN

Este estudio evaluó la eficacia de la terapia por luz de baja intensidad (LLLT, por sus siglas en inglés) en el tratamiento de tres pacientes con parálisis de Bell (BP) y revisó la literatura relacionada. Un caso involucró a una mujer de 52 años con BP grado V, quien, después de recibir terapia con medicamentos y siete sesiones de LLLT (780 nm; 70 mW; E = 9 J), mejoró al grado II en 21 días. Otro caso, un hombre de 37 años, previamente no receptivo a tratamientos, se sometió a 24 sesiones de LLLT, pasando del grado V al II en 4 meses. Finalmente, un hombre de 40 años tratado con medicamentos y 8 sesiones de LLLT mejoró del grado V al I en 1,5 meses. En esencia, la LLLT mejoró significativamente las funciones faciales, la estética y el bienestar general de los pacientes en un corto período de tiempo.

Palabras clave: terapia por drogas adjuvante; parálisis de Bell; terapia por luz de baja intensidad.

Cite as:

Silva F, Manzano B, Carneiro M, Moura L, Santos DS, Rubira CM, et al. Photobiomodulation as adjuvant therapy for Bell's palsy: a case series. *Rev Estomatol Herediana*. 2024; 34(3): 263-276. DOI: 10.20453/reh.v34i3.5837

Received: 26-09-2023

Accepted: 14-05-2024

Online: 30-09-2024

Conflicts of interest: The authors declare that they have no conflict of interest.

Funding: This study was financed in part by the Coordenação de Aperfeiçoamento de Pessoal de Nível Superior - Brasil (CAPES) - Finance Code 001.

Ethical approval: This study was approved by the Human Research Ethics Committee of the Bauru School of Dentistry, University of São Paulo (CAAE: 42278621.6.0000.5417) and all procedures adhered to the tenets of the Declaration of Helsinki.

Consent to participate: Informed consent to participate in the study was obtained from all participants.

Consent to publication: Informed consent to publication was obtained from relevant participants.

Authorship contribution:

FLS: conceptualization, data curation, formal analysis, investigation, methodology, validation, visualization, writing – original draft, writing – review & editing.

BRM and MCC: conceptualization, data curation, formal analysis, funding acquisition, investigation, methodology, resources, validation, visualization, writing – original draft, writing – review & editing.

LLM: data curation, funding acquisition, resources, validation, visualization, writing – original draft, writing – review & editing.

DSFS: data curation, formal analysis, methodology, writing – original draft, writing – review & editing.

CMFR: conceptualization, methodology, resources, supervision, writing – original draft, writing – review & editing.

PSSS: conceptualization, project administration, validation, visualization, writing – original draft, writing – review & editing.

Corresponding author:

Mailon Cury Carneiro
Address: Department of Surgery, Stomatology, Pathology, and Radiology, Bauru School of Dentistry, University of São Paulo. Alameda Octávio Pinheiro Brisolla, 9-75, Bauru, SP, 17012-901, Brazil
E-mail: mailoncury@usp.br



Artículo de acceso abierto, distribuido bajo los términos de la Licencia Creative Commons Atribución 4.0 Internacional.

© Los autores

© *Revista Estomatológica Herediana*

¹ University of São Paulo, Bauru School of Dentistry. São Paulo, Brazil.

² University of Cuiabá. Rondonópolis, Brazil.

RESUMO

Este estudo avaliou a eficácia da terapia com luz de baixo nível (LLLT) no tratamento de três pacientes com paralisia de Bell (PB) e revisou a literatura relevante. O primeiro caso envolveu uma mulher de 52 anos com PB grau V, que, após receber tratamento farmacológico e realizar sete sessões de LLLT (780 nm; 70 mW; E = 9 J), melhorou para grau II em 21 dias. O segundo caso foi de um homem de 37 anos que, após não ter apresentado resposta ao tratamento anteriormente, recebeu 24 sessões de LLLT e progrediu de grau V para grau II ao longo de 4 meses. O terceiro caso envolveu um homem de 40 anos que, após medicação e oito sessões de LLLT, melhorou de grau V para grau I em 1,5 meses. No geral, a LLLT demonstrou melhorar significativamente a função facial, a estética e o bem-estar geral desses pacientes em um período relativamente curto.

Palavras-chave: terapia medicamentosa adjuvante; paralisia de Bell; terapia com luz de baixa intensidade.

INTRODUCTION

Bell's palsy (BP) is a disorder affecting the lower motor neuron associated with the facial nerve. Individuals afflicted with this condition experience unilateral facial paralysis and a reduced ability to taste on the anterior part of the tongue. The incidence of BP is estimated at between 15 and 30 new cases per year per 100,000 individuals, predominantly affecting young and middle-aged adults aged 15 to 40 years (1).

BP is diagnosed clinically and assessed using the House-Brackmann (HB) scale, a standardized tool that measures the extent of nerve damage in facial palsy from I, indicating normal function, to VI, which represents total paralysis (2). Corticosteroid therapy, possibly combined with antiviral medications, along with physical therapy, acupuncture, massage, and neuromuscular facilitation are commonly employed treatments for BP (3). Low-level light therapy (LLLT) is also mentioned in the literature as a treatment method (4). The effectiveness of LLLT, and with or without alternative therapies has been discussed in the literature due to its modulating action, non-invasiveness, painlessness, and lack of adverse effects (5). However, there is little relevant evidence to consider LLLT effective in improving BP, requiring further study.

This study aimed to report three clinical cases where LLLT was used as an adjuvant treatment for BP. Concurrently, a literature review was conducted that included published cases of BP treated with LLLT to analyze the laser-based protocols and their respective efficacies.

CASES PRESENTATION

This study and the following case reports were conducted at the Stomatology Clinic of the Bauru School of Dentistry, University of São Paulo.

Case 1

A 52-year-old Brazilian Caucasian woman, exhibiting right-sided facial paralysis, was diagnosed with BP one week prior to her evaluation and is currently under the care of a neurologist. Her medical history includes gastritis and stress, and she has used acyclovir for 7 days and Alendronato® for 1 year due to pain upon manipulation of the sternocleidomastoid muscle, ipsilateral to the BP. She reported using prednisone 20 mg, Velija®, lubricating eye drops, omeprazole 20 mg, and Nevrix®. On an extraoral physical examination, she presented with facial paralysis on the right side (figure 1A), with the paralysis ipsilateral to the labial protrusion (figure 1B), elevation of the eyebrows (figure 1C), and incomplete closure of the right eye (figure 1D). This presentation was compatible with the diagnosis of BP, which was classified as grade V (severe dysfunction) according to the HB scale. The intraoral physical examination showed no changes.

In view of the diagnosis of BP, the adjuvant therapeutic approach to medical treatment consisted of LLLT (780 nm; 70 mW; 157.5 J/cm²; E = 9 J; t = 1 minute and 30 seconds), using the Twin Laser device (MM Optics, São Carlos, SP, Brazil), applied along the path of the facial nerve on the right side of the face. The next day, the patient returned for the second LLLT session with no complaints and no clinical signs of improvement in facial asymmetry. However, from the third session onwards, signs of muscle movement recovery appeared, such as a reduction in the inclination of the lips to the left upon labial protrusion (figure 1F), more symmetrical eyebrow elevation (figure 1G), and complete eyelid occlusion (figure 1H).

A total of seven LLLT sessions were carried out over 21 days, with intervals between sessions ranging from 1 to 7 days. Initially, the patient reported sensations of tingling, jerking, and shock during LLLT application. During the fifth session, she experienced needling sensations in the pre-auricular region. In the sixth session, she reported pain upon palpation of the temporalis, masseter, and sternocleidomastoid muscles, accompanied by a severe headache on the right side; Alginic® was administered by the neurologist.

In the last consultation, the patient was no longer using prednisone, had no complaints, and was satisfied

with the results, as seen in figure 1 (Q, R, S, and T). Consequently, this led to significant improvements in her facial function and aesthetics. Therefore, after

treatment, BP was reclassified as grade II, indicating mild dysfunction according to the HB scale.

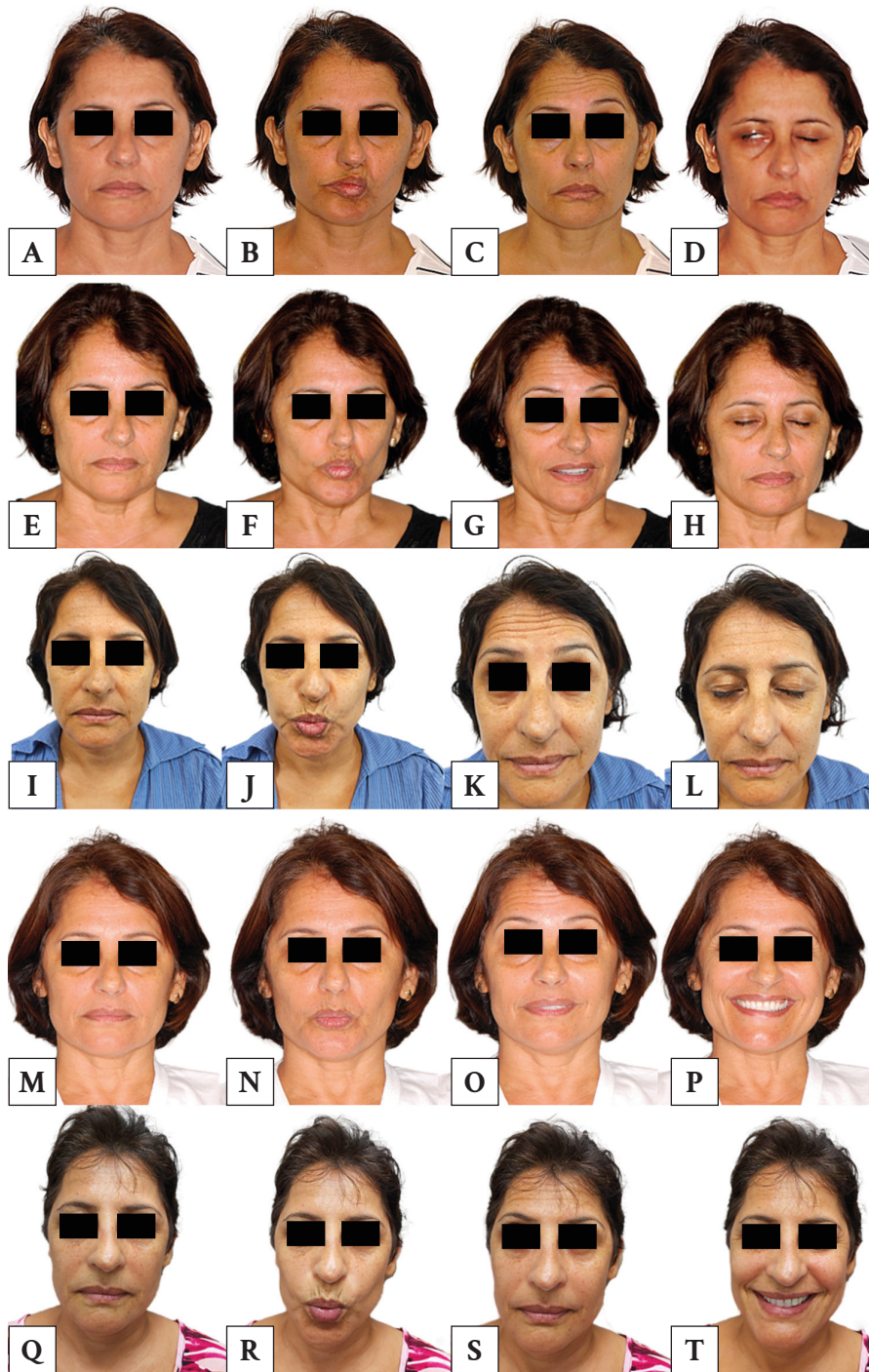


Figure 1. Clinical evolution of Bell's palsy treated with low-level light therapy. First session: facial asymmetry at rest (A), labial protrusion (B), eyebrow elevation (C), and partial occlusion of the right eyelid (D). Third session: partial improvement of right lip paralysis due to labial protrusion (F), improvement in eyebrow elevation (G), and complete eyelid occlusion (H). Fourth session: significant improvement in facial asymmetry at rest (I), lip protrusion (J), and eyebrow asymmetry (simultaneous elevation) (K). Sixth session: more symmetrical profile and improvement in the disproportionate lip protrusion (N). Seventh session (last): significant improvement in all facial expressions, greater symmetry at rest (Q), and improvement in lip protrusion (R), eyebrow elevation (S), and smile (T).

Case 2

A 37-year-old Brazilian Caucasian man, an artisan with a previous diagnosis of BP, reported visiting the emergency room three months prior to the study due to tingling in his tongue, pain in the occipito-parietal region, and a headache. He was later diagnosed with BP on the right side, possibly related to stress and heat shock. He reported having the first episode 10 years earlier, achieving complete remission after the treatment was completed.

His medical history revealed a mercury allergy and a testicular tumor resection 10 years earlier, which was why he was continuously treated with 1 g of finasteride, topical minoxidil, and Silimalon®. For the treatment of BP, he received acyclovir 400 mg, prednisone 20 mg, and three intramuscular doses of vitamin B12. He was also undergoing physical therapy, acupuncture, and electrical stimulation therapy, without any significant recovery in facial expressions.

During the extraoral physical examination, facial paralysis was observed on the right side, showing facial asymmetry at rest (figure 2A), immobility of the lips and eyelid when smiling (figure 2B), and incomplete occlusion of the eyelids (figure 2C). This presentation was consistent with a diagnosis of BP grade V, according to the HB scale. The intraoral

physical examination revealed a traumatic ulcer of approximately 2 mm on the lower lip.

The treatment consisted of 24 LLLT sessions (780 nm; 70 mW; 105 J/cm²; E = 9 J; t = 1 minute - Twin Laser device, MM Optics, São Carlos, SP, Brazil) along the path of the facial nerve as an adjuvant treatment for BP. These sessions were conducted over a period of 4 months with intervals of 2 to 3 days between sessions in the first month, ranging between 2, 4, and 5 days in the second month, and between 4, 5, 7, 8, 14, and 29 days in the last 2 months.

In light of the progress of BP by the seventh session, Etna® was prescribed for 30 days as an adjuvant to LLLT. During the 19th session, the patient returned, complaining of xerophthalmia, and was referred for evaluation and ophthalmological management. Upon returning for the 20th session of LLLT, the patient no longer complained of xerophthalmia but reported sensations of jerking, tingling, and itching during the laser applications, which persisted until the final session.

In his final consultation, the patient reported satisfaction with the treatment, which significantly improved his facial function and aesthetics, as observed in figure 2 (J, K and L). He progressed from BP grade V to grade II, characterized as mild dysfunction, according to the HB scale.




Figure 2. Clinical evolution of Bell's palsy treated with low-level light therapy. First session: facial asymmetry at rest, as seen by the depression of the labial commissure on the right side when compared to the left (A), labial and right eyelid immobility when smiling (B), and incomplete occlusion of the right eyelid (C). Seventh session: partial improvement at rest (D) and complete occlusion of the right eyelid (F). Nineteenth session: improvement in labial and eyelid asymmetry on the right side when smiling (H), as compared with the left side and previous sessions. Twenty-fourth session (last): significant improvement in all facial expressions at rest (J), smiling (K), and occlusion of the eyelid (L).

Case 3

A 40-year-old Brazilian Caucasian man sought medical attention for right-sided facial paralysis. He visited the emergency room and later saw an otolaryngologist five days prior. Audiometry was performed, confirming the diagnosis of BP, likely triggered by an intense period of stress. His medical history included the use of Benerva®, Prednisone, Acyclovir, Lacrima® Plus, and Elitezan®, as recommended by the otolaryngologist.

During the extraoral physical examination, he exhibited hemifacial paralysis, immobility of the nose and lips, and difficulty closing the right eye, with noticeable asymmetry even at rest. He reported a lack of sensitivity on the right side, as seen in figure 3 (A, B, C, and D). This presentation was consistent with a diagnosis of BP grade V, according to the HB scale. The intraoral physical examination showed no changes.

The adjuvant therapy consisted of LLLT (780 nm; 70 mW; 157.5 J/cm²; E = 9 J; t = 1 minute and 30 seconds - Twin Laser device, MM Optics, São Carlos, SP, Brazil) along the path of the facial nerve on the right side of the face. This protocol was administered twice a week for 1.5 months. In the second session, the patient reported experiencing a severe headache over the past 2 days, which improved with the use of Neosaldina®.

After the 6th session of LLLT, the patient reported significant improvements in taste, swallowing capacity, speech, and eye closure (figure 3 I, J, K, and L), with no further headaches reported and continued improvement in facial movements. By the end of 8 sessions of LLLT, all symptoms had completely disappeared, and there was full regression of BP signs (figure 3 M, N, O, and P). The patient progressed from BP grade V to grade I, indicating normal facial nerve function, according to the HB scale.




Figure 3. Clinical evolution of Bell's palsy treated with low-level light therapy. First session: facial asymmetry at rest (A), labial protrusion (B), smiling (C), and difficult occlusion of the right eyelid (D). Fourth session: slight improvement of right lip paralysis due to labial protrusion (F), slight improvement in smiling (G), and complete eyelid occlusion (H). Sixth session: significant improvement in facial asymmetry at rest (I), lip protrusion (J), smiling (K), and complete eyelid occlusion (L). Eighth session (last): Complete improvement in all facial expressions like symmetry at rest (M), in lip protrusion (N), smile (O), and eyelid occlusion (P).

COMPARATIVE ANALYSIS OF PUBLISHED CASES OF BP TREATED WITH LLLT

After conducting the case reports, a literature review was undertaken to correlate published clinical cases of individuals with BP treated with LLLT with those treated by our group. The review encompassed

studies without restrictions on year and language and was conducted across multiple databases, including PubMed/Medline, Embase (via Elsevier), Virtual Health Library (BVS, by its Spanish acronym), Scopus, and Web of Science. Each database was searched using a specific strategy outlined in the table 1.

Table 1. Database Search.

Database	Search
PubMed (19 results)	<p>#1 "Bell Palsy"[Mesh] OR (Bell Palsies) OR (Palsies, Bell) OR (Palsy, Bell) OR (Bell's Palsy) OR (Bell's Palsies) OR (Bells Palsy) OR (Palsies, Bell's) OR (Palsy, Bell's) OR (Facial Neuropathy, Inflammatory, Acute) OR (Facial Paralysis, Idiopathic) OR (Facial Paralysis, Idiopathic) OR (Idiopathic Facial Paralysis) OR (Idiopathic Facial Paralysis) OR (Paralysis, Idiopathic Facial) OR (Paralysis, Idiopathic Facial) OR (Inflammatory Facial Neuropathy, Acute) OR (Acute Inflammatory Facial Neuropathy) OR (Facial Neuropathy, Idiopathic Acute) OR (Idiopathic Acute Facial Neuropathy) OR (Acute Idiopathic Facial Neuropathy) OR (Herpetic Facial Paralysis) OR (Facial Paralysis, Herpetic) OR (Facial Paralysis, Herpetic) OR (Herpetic Facial Paralysis) OR (Paralysis, Herpetic Facial) OR (Paralysis, Herpetic Facial)</p> <p>#2 "Low-Level Light Therapy"[Mesh] OR (Light Therapies, Low-Level) OR (Light Therapy, Low-Level) OR (Low Level Light Therapy) OR (Low-Level Light Therapies) OR (Therapies, Low-Level Light) OR (Therapy, Low-Level Light) OR (Photobiomodulation Therapy) OR (Photobiomodulation Therapies) OR (Therapies, Photobiomodulation) OR (Therapy, Photobiomodulation) OR (LLLT) OR (Laser Therapy, Low-Level) OR (Laser Therapies, Low-Level) OR (Laser Therapy, Low Level) OR (Low-Level Laser Therapies) OR (Laser Irradiation, Low-Power) OR (Irradiation, Low-Power Laser) OR (Laser Irradiation, Low Power) OR (Low-Power Laser Therapy) OR (Low Power Laser Therapy) OR (Laser Therapy, Low-Power) OR (Laser Therapies, Low-Power) OR (Laser Therapy, Low Power) OR (Low-Power Laser Therapies) OR (Low-Level Laser Therapy) OR (Low Level Laser Therapy) OR (Low-Power Laser Irradiation) OR (Low Power Laser Irradiation) OR (Laser Biostimulation) OR (Biostimulation, Laser) OR (Laser Phototherapy) OR (Phototherapy, Laser)</p>
Embase (30 results)	<p>('Bell palsy'/exp OR 'Bell palsy' OR 'Bell's palsy' OR 'acute idiopathic facial neuropathy' OR 'acute inflammatory facial neuropathy' OR 'facial paralysis, idiopathic' OR 'herpetic facial paralysis' OR 'idiopathic acute facial neuropathy' OR 'idiopathic facial paralysis') AND ('low level laser therapy'/exp OR 'endoscopic laser therapy' OR 'laser biostimulation' OR 'laser therapy' OR 'laser therapy, low-level' OR 'laser treatment' OR 'low energy laser therapy' OR 'low energy laser treatment' OR 'low intensity laser therapy' OR 'low intensity laser treatment' OR 'low level laser therapy' OR 'low level laser treatment' OR 'low level light therapy' OR 'low power laser therapy' OR 'low power laser treatment' OR 'low-level laser therapy' OR 'low-level light therapy')</p>
BVS (17 results)	<p>#1 mh:"Paralísia de Bell" OR "Neuropatia Facial Aguda Inflamatória" OR "Paralísia Facial Idiopática" OR "Paralísia Facial Herpética" OR "Bell Palsy" OR "Bell's Palsy" OR "Facial Neuropathy, Inflammatory, Acute" OR "Facial Paralysis, Idiopathic" OR "Herpetic Facial Paralysis" OR "Parálisis de Bell" OR "Neuropatía Facial Inflamatoria Aguda" OR "Parálisis Facial Idiopática" OR "Parálisis Facial Herpética" OR mh:C02.256.466.087\$ OR mh:C07.465.094\$ OR mh:C07.465.299.250\$ OR mh:C10.292.319.250\$</p> <p>#2 mh:"Low-Level Light Therapy" OR "Laser Therapy, Low-Level" OR "Laser Biostimulation" OR "Laser Irradiation, Low-Power" OR "LLLT" OR "Terapia com Luz de Baixa Intensidade" OR "Terapia a Laser de Baixa Intensidade" OR "Irradiação a Laser de Baixa Intensidade" OR "Terapia a Laser de Baixa Potência" OR "Bioestimulação a Laser" OR "Irradiação a Laser de Baixa Potência" OR "LLLT" OR "Terapia por Luz de Baja Intensidad" OR "Terapia por Láser de Baja Intensidad" OR "Irradiación por Láser de Bajo Poder" OR "Terapia por Láser de Bajo Nivel" OR "Terapia por Láser de Baja Potencia" OR "Bioestimulación por Láser" OR "Irradiación por Láser de Baja Potencia" OR "LLLT" OR mh:E02.594.540\$ or mh:E02.774.500\$</p>

Table 1. (Continuation)

Database	Search
Scopus (40 results)	(TITLE-ABS-KEY (“Bell Palsy” OR “Bell Palsies” OR “Palsies, Bell” OR “Palsy, Bell” OR “Bell’s Palsy” OR “Bell’s Palsies” OR “Bells Palsy” OR “Palsies, Bell’s” OR “Palsy, Bell’s” OR “Facial Neuropathy, Inflammatory, Acute” OR “Facial Paralysis, Idiopathic” OR “Facial Paralysis, Idiopathic” OR “Idiopathic Facial Paralysis” OR “Idiopathic Facial Paralysis” OR “Paralyses, Idiopathic Facial” OR “Paralysis, Idiopathic Facial” OR “Inflammatory Facial Neuropathy, Acute” OR “Acute Inflammatory Facial Neuropathy” OR “Facial Neuropathy, Idiopathic Acute” OR “Idiopathic Acute Facial Neuropathy” OR “Acute Idiopathic Facial Neuropathy” OR “Herpetic Facial Paralysis” OR “Facial Paralysis, Herpetic” OR “Facial Paralysis, Herpetic” OR “Herpetic Facial Paralysis” OR “Facial Paralysis, Herpetic” OR “Facial Paralysis, Herpetic” OR “Herpetic Facial Paralysis” OR “Paralyses, Herpetic Facial” OR “Paralysis, Herpetic Facial”)) AND TITLE-ABS-KEY (“Low-Level Light Therapy” OR “Light Therapies, Low-Level” OR “Light Therapy, Low-Level” OR “Low Level Light Therapy” OR “Low-Level Light Therapies” OR “Therapies, Low-Level Light” OR “Therapy, Low-Level Light” OR “photocoagulation therapy” OR “photocoagulation therapies” OR “therapies, photocoagulation” OR “therapy, photocoagulation” OR “LLLT” OR “Laser Therapy, Low-Level” OR “Laser Therapies, Low-Level” OR “Laser Therapy, Low Level” OR “Low-Level Laser Therapies” OR “Laser Irradiation, Low-Power” OR “Irradiation, Low-Power Laser” OR “Laser Irradiation, Low Power” OR “Low-Power Laser Therapy” OR “Low Power Laser Therapy” OR “Laser Therapy, Low-Power” OR “Laser Therapies, Low-Power” OR “Laser Therapy, Low Power” OR “Low-Power Laser Therapies” OR “Low-Level Laser Therapy” OR “Low Level Laser Therapy” OR “Low-Power Laser Irradiation” OR “Low Power Laser Irradiation” OR “Laser Biostimulation” OR “Biostimulation, Laser” OR “Laser Phototherapy” OR “Phototherapy, Laser”)
Web of Science (18 results)	#1 TS=(“Bell Palsy” OR “Bell Palsies” OR “Palsies, Bell” OR “Palsy, Bell” OR “Bell’s Palsy” OR “Bell’s Palsies” OR “Bells Palsy” OR “Palsies, Bell’s” OR “Palsy, Bell’s” OR “Facial Neuropathy, Inflammatory, Acute” OR “Facial Paralysis, Idiopathic” OR “Facial Paralysis, Idiopathic” OR “Idiopathic Facial Paralysis” OR “Idiopathic Facial Paralysis” OR “Paralyses, Idiopathic Facial” OR “Paralysis, Idiopathic Facial” OR “Inflammatory Facial Neuropathy, Acute” OR “Acute Inflammatory Facial Neuropathy” OR “Facial Neuropathy, Idiopathic Acute” OR “Idiopathic Acute Facial Neuropathy” OR “Acute Idiopathic Facial Neuropathy” OR “Herpetic Facial Paralysis” OR “Facial Paralysis, Herpetic” OR “Facial Paralysis, Herpetic” OR “Herpetic Facial Paralysis” OR “Paralyses, Herpetic Facial” OR “Paralysis, Herpetic Facial”) Índices=SCI-EXPANDED, SSCI, A&HCI, CPCI-S, CPCI-SSH, ESCI Tempo estipulado=Todos os anos #2 TS=(“Low-Level Light Therapy” OR “Light Therapies, Low-Level” OR “Light Therapy, Low-Level” OR “Low Level Light Therapy” OR “Low-Level Light Therapies” OR “Therapies, Low-Level Light” OR “Therapy, Low-Level Light” OR “photocoagulation therapy” OR “photocoagulation therapies” OR “therapies, photocoagulation” OR “therapy, photocoagulation” OR “LLLT” OR “Laser Therapy, Low-Level” OR “Laser Therapies, Low-Level” OR “Laser Therapy, Low Level” OR “Low-Level Laser Therapies” OR “Laser Irradiation, Low-Power” OR “Irradiation, Low-Power Laser” OR “Laser Irradiation, Low Power” OR “Low-Power Laser Therapy” OR “Low Power Laser Therapy” OR “Laser Therapy, Low-Power” OR “Laser Therapies, Low-Power” OR “Laser Therapy, Low Power” OR “Low-Power Laser Therapies” OR “Low-Level Laser Therapy” OR “Low Level Laser Therapy” OR “Low-Power Laser Irradiation” OR “Low Power Laser Irradiation” OR “Laser Biostimulation” OR “Biostimulation, Laser” OR “Laser Phototherapy” OR “Phototherapy, Laser”) Índices=SCI-EXPANDED, SSCI, A&HCI, CPCI-S, CPCI-SSH, ESCI Tempo estipulado=Todos os anos

The inclusion criteria for selecting studies comprised case reports and case series of individuals with BP treated with LLLT, either alone or in combination with other treatments. Studies were included if they diagnosed patients with BP and reported outcomes in terms of facial nerve functional recovery. Exclusion criteria consisted of studies without full-text access

and those lacking clear outcome measures related to facial nerve function. Using the EndNote Web® tool (Clarivate, London, UK), duplicate studies were removed, resulting in the selection of 44 studies for full reading. Of these, 8 articles met the inclusion criteria (4, 6-12) (figure 4).

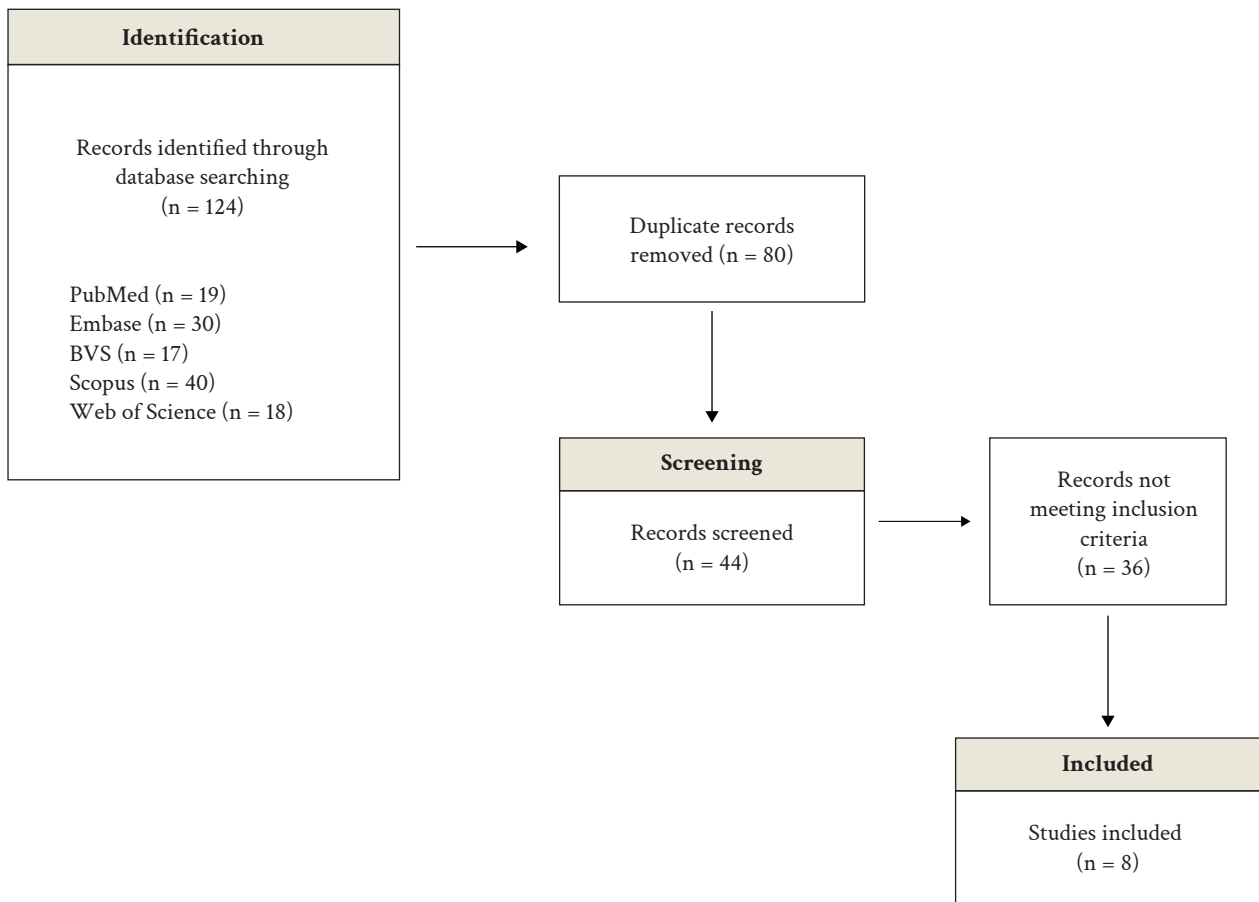


Figure 4. Selection of published case reports of Bell's Palsy treated with low-level light therapy (updated on 04/24/2024).

The data from these studies, along with the current report, are presented in table 2. An update to the search was conducted on April 24, 2024.

Table 2. Previously reported cases of patients with Bell's Palsy treated with low-level light therapy.

Case	Study	Year	Sex	Age (y)	Side	Main complaint	Exposure	Primary or recurring/First signs (d)	Type	Wavelength (nm)	Energy density (J/cm ²) or energy total (J)	Frequency and range, Total ss/ power (mW)	Other treatments	Evolution
1	Ladalaro et al. (6)	2001	M	32	L	Retroangular and ipsilateral pain	NR	Primary/730	DiGaAlAs	780	66,7	2 x/wk for 12 wk, 24 wk/50	NR	Grade V to II (esc HB)
2	Ladalaro et al. (6)	2001	F	45	R	Retroangular and ipsilateral pain	NR	Primary/9855	DiGaAlAs	780	66,7	2 x/wk for 12 wk, 24 wk/50	NR	Grade III to II (esc HB)
3	Ladalaro et al. (6)	2001	M	22	R	Retroangular and ipsilateral pain	NR	Primary/56	DiGaAlAs	780	66,7	2 x/wk for 12 wk, 24 wk/50	NR	Grade IV to II (esc HB)
4	Ladalaro et al. (6)	2001	M	28	R	Retroangular and ipsilateral pain	NR	Primary/23	DiGaAlAs	780	66,7	2 x/wk for 12 wk, 24 wk/50	NR	Grade III to I (esc HB)
5	Marques et al. (7)	2011	M	52	R	HF paralysis	NR	Primary/1	Di	790	26-29	Diary - 1 st week; 3 x/wk - Monday to 7 th wk, 21 ss/40	Electro and Physical	Recovery rapid sensory and QoL improvement
6	Marques et al. (7)	2011	F	24	R	HF paralysis	NR	Primary/NR	Di	790	25	Diary - 1 st week; 3 x/wk - Monday to 7 th wk, 21 ss/40	Electro and Physical	Recovery rapid sensory and QoL improvement
7	Fontana & Bagnato (8)	2013	M	3	R	Difficulty in occluding eye D	10"/15"/30"	Primary/NR	DiGaAlAs	660/780	17,5; 15; 12,5; 10	4 x/wk - 1 st and 2nd wk; 3x/wk - 3rd wk. Being, 1 st to 5 th - 70 mW, 6 th - 60 mW, 7 th -50 mW, and 8 th to 11 th - 40 mW, 11 ss/70,60,50,40	Med ^t	Grade V to I (esc HB)
8	Rubis (9)	2013	M	40	L	Sialorrhea, occlude and C1 sensitivity	90"	Primary/10	DiGaAs	910	47,6 x 10 J	2 x/wk - 1st wk, 2 ss/100,000	Med ^t and chi	Recovery □ 70-80% facial expressions, tension and headache
9	Poloni et al. (4)	2018	F	13	R	Pain; difficulty chewing, speaking, and drooling	28"	Primary/NR	DiGaAlAs	830	100	1 x/wk - 1st wk; 2x/week - 2nd week, 3 ss/100	NR	Complete regression, improved speech and chewing

Table 2. (Continuation)

Case	Study	Year	Sex	Age (y)	Side	Main complaint	Exposure	Primary or recurring/First signs (d)	Type	Wavelength (nm)	Energy density (J/cm ²) or energy total (J)	Frequency and range, Total ss/ power (mW)	Other treatments	Evolution
10	Tanganelli et al. (10)	2020	F	71	L	HF paralysis and masseter and temporal pain	10"	Primary/1	Di	808	120	Every 48 hours, first 5 ss, 2 x / without last 5 ss, 10 ss / 100	NR	Grade V to I (esc HB)
11	Panhóca et al. (11)	2022	M	50	R	HF paralysis	60"	Primary/NR	Di	808	105	2x/ wk - 2 mo/ 100	NR	Restoration of the face symmetry and facial expression
12	Panhóca et al. (11)	2022	F	22	L	Unilateral deafness and herpes at 3 days before	180"	Primary/3	Di	808	≤108	3 mo/ 600	vacuumtherapy	Restoration of the face symmetry and facial expression
13	Gjurin et al. (12)	2023	M	30	L	Weakness in all the muscles of his left facial expression	60"	Primary/365	DiYAG	1064	32	3x/wk- 3wk/ 2x/ wk- 3wk/ 1x/ wk- 3mo/ Total number: 27 during 6 months / 3200	NR	Grade V to III
14	Present case 1	2024	F	52	R	HF paralysis	90"	Primary/7	DiGaAlAs	780	157,5	3x / wk - 1st wk; 2x / wk - 2nd wk; 1x / wk - 3rd and 4th wk, 7 ss / 70	Med [§]	Grade V to II
15	Present case 2	2024	M	37	R	HF paralysis	60"	Appellant, 1st 2009/90	DiGaAlAs	780	105	1x / wk - 6 wk; 2x / wk - 7th to 13th and 15th wk, 24 ss / 70	Med [‡] , Fisi, acup, and electro	Grade V to II
16	Present case 3	2024	M	40	R	HF paralysis and taste alteration	90"	Primary/5	DiGaAlAs	780	157,5	2x/ wk - 2 mo//70	Med [‡]	Grade V to I

NR: not reported; SS: sessions; x/wk: per week; electro: electrotherapy; physio: physiotherapy; med: medication; acup: acupuncture; chiro: chiropractic; esc HB: House and Brackmann scale; QoL: quality of life; HF: hemifacial. **Medicines:** † Refresh Advanced® (carmellose sodium 5 mg, glycerol 10 mg, polysorbate 80.5 mg). ‡ Oral steroids. § Acyclovir 200 mg, Alendronate® (risedronate sodium 35 mg), prednisone 20 mg, Nevrix® (tiamena 100 mg, pyridoxine 100 mg, cyanocobalamin 500 mg), vitamin B, Velija® (duloxetine hydrochloride 30 mg), omeprazole 20 mg, Alginate Retard® 1000 mg (cyanocobalamin 1000 mg, pyridoxine 100 mg, thiamine nitrate 100 mg, diclofenac sodium 100 mg), and lubricating eye drops. ¶ Acyclovir 400 mg, prednisone 20 mg, Etna® (cytidine phosphate monophosphate 2.5 mg, uridine triphosphate 1.5 mg, hydroxocobalamin acetate 1.0 mg), vitamin B12 (cyanocobalamin), Silimalon® (silymarin 70 mg, methionine 100 mg), finasteride 1 g, and topical minoxidil. YAcyclovir 200 mg, Benerva® (thiamine hydrochloride 300mg), prednisone 20 mg, Lacrima® Plus (dextran 70-hypromellose), and Elitezan® (retinol acetate + amino acids + methionine + chloramphenicol).

DISCUSSION

LLLT is a non-invasive, non-thermal phototherapy method that employs laser light to treat specific body tissues, preventing cell death, reducing inflammation, and promoting cellular regeneration. Operating at the cellular level, LLLT induces significant biochemical changes, activates angiogenesis, stimulates tissue proliferation, and accelerates wound healing (5). Additionally, LLLT provides analgesic benefits triggered by the release of endorphins, and it exhibits a potent anti-inflammatory effect through the reduction of cytokines such as interleukin-1 and tumor necrosis factor, thereby aiding neural repair (13). Furthermore, as a painless, well-tolerated procedure without associated side effects, LLLT is considered an effective therapeutic option, particularly in the treatment of conditions like BP (3).

Studies have shown positive results using LLLT as a treatment for BP, either exclusively or combined with other forms of treatment, such as chiropractic care, electrotherapy, physiotherapy, and drug treatment with corticosteroids, antivirals, vitamin B, and other medications (4, 14, 15). This was observed in the three cases treated by our group, where there was a significant recovery of facial expressions with LLLT in addition to acyclovir, prednisone, Nevrix®, vitamin B12, Etna®, physiotherapy, acupuncture, and electrical stimulation therapy.

When reviewing the literature in search of cases of BP treated with LLLT with or without other therapies, 13 were found and added to the three treated by our group, totaling 16 cases (table 2). It was observed that BP affected individuals aged between 3 and 71 years, as corroborated by other studies (1, 14). However, other studies have shown a higher incidence of BP among adults between 40 and 50 years of age. In this study, most of the patients were under 40 years of age, aligning with the findings of Magazi et al. (16), which noted a higher incidence of BP in individuals under 30 years of age.

Some studies have reported a higher prevalence of BP in men, while others found no distinction between sexes (1, 17). In our review, most of the cases (10 out of 16) were male. Regarding the signs, hemifacial palsy on the right side was the most common, corresponding with what has been reported in other studies. The main complaints, paralysis and/or pain, manifested in most cases. The incapacity of eyelid occlusion was present in six individuals, including the cases treated by our group. Symptoms also included difficulty in chewing

and drooling, which are complaints commonly found in individuals with BP (2).

The etiology of BP is primarily idiopathic but may include factors such as acute exposure to cold weather, herpetic viral infection, nerve ischemia, and inflammation (18). In some clinical cases identified by our group, a possible viral etiology was noted, along with a relationship with heat shock and an association with stress.

The diagnosis of BP is primarily made through a comprehensive clinical evaluation, which may include the use of supplementary imaging to rule out other causes of facial paralysis, as assessed by the HB scale. In all the cases reviewed, the diagnosis was obtained by clinical examination, but only ten were rated by the HB score. Of these, seven exhibited severe dysfunction (Grade V) (70%), two displayed moderate dysfunction (Grade III) (20%), and one showed moderately severe dysfunction (Grade IV) (10%). This contrasts with findings from another study, where the distribution was 27% at Grade IV, 18% at Grade III, and 17% at Grade V (1).

A study indicates that corticosteroid injections in acute idiopathic inflammatory facial paralysis achieve only partial motor recovery after six months, demonstrating minimal to moderate clinical effectiveness (19). In addition, prolonged corticosteroid use in these patients can cause systemic adverse effects, such as hyperglycemia and changes in adrenal gland function, among other effects that may limit their use in patients with decompensated diabetes, for example (19).

The literature review observed a reduction in the duration of BP treatment when using LLLT as an adjuvant to medication, as the primary BP cases required fewer sessions (between two and seven sessions) compared to most cases treated with LLLT alone. Additionally, even in the case of recurrent BP where medications were combined with LLLT, the same number of sessions (24 sessions) was necessary, similar to cases treated solely with LLLT (table 2).

At the end of treatment, five individuals still had mild dysfunction, including two from the cases treated by our group. Among the other cases in this review, seven had complete regression of paralysis, while the remaining cases achieved rapid sensory recovery and notable improvements in facial function and aesthetics. This reinforces that LLLT, as an adjunct to other therapies for BP, leads to significant recovery of facial expressions in a short period of time (15, 19).

Although there is no specific protocol for LLLT in BP, the use of diode lasers, specifically Gallium-Aluminum-Arsenide (GaAlAs) and Gallium-Arsenide (GaAs) diodes, has proven effective. These lasers operate within a wavelength range of 660 to 910 nm, with a power ranging from 40 to 100 mW, and an energy density of 10 to 157.5 J/cm². Treatments, varying from 2 to 24 sessions, were effective in treating BP in all the cases described in this review (table 2).

Regaining facial expressions is crucial for improving well-being, achieving satisfactory aesthetics, and enhancing social interactions. Additionally, neural recovery in cases of BP leads to the restoration of vital facial functions such as speaking, swallowing, sucking, and chewing. In our cases, we observed that LLLT effectively restored facial expressions and functions, enhanced aesthetics, and facilitated the individuals' quick return to social interactions.

This study has several inherent limitations typical of case reports, including the small sample size, the absence of a control group, and the variability in individual responses to photobiomodulation treatment. Additionally, the lack of a standardized protocol for LLLT application in patients with BP complicates direct comparisons with other studies. However, this study also has significant strengths. The inclusion of cases with varying degrees of severity and treatment responses provides a comprehensive view of potential clinical variations. Furthermore, the detailed follow-up of patients and rigorous documentation of procedures and outcomes offer a robust foundation for future research.

We decided to complement our case report with a literature review to provide a broader context and validate our findings. The review allowed us to compare our results with those obtained by other researchers, highlighting the consistency and effectiveness of photobiomodulation as an adjuvant therapy for BP. This combined approach strengthens the credibility of our results and contributes to the body of evidence on the use of LLLT in the treatment of BP.

CONCLUSIONS

In conclusion, this case series highlights the promising role of LLLT as a supportive treatment for BP. We observed significant improvements in facial function, aesthetics, and overall well-being in our patients, suggesting that LLLT can effectively promote nerve recovery and enhance quality of life. More extensive,

randomized controlled trials are needed to establish standardized treatment protocols and further validate our findings. Nonetheless, our results add to the growing evidence that LLLT is a valuable adjunctive therapy for BP and merits further exploration.

REFERENCES

1. Zhao H, Zhang X, Tang Y, Jin Z, Wang X, Li S. Bell's palsy: clinical analysis of 372 cases and review of related literature. *Eur Neurol* [Internet]. 2017; 77(3-4): 168-172. Available from: <https://doi.org/10.1159/000455073>
2. House JW, Brackmann DE. Facial nerve grading system. *Otolaryngol Head Neck Surg* [Internet]. 1985; 93(2): 146-147. Available from: <https://doi.org/10.1177/019459988509300202>
3. Kandakurti PK, Shanmugam S, Basha SA, Amaravadi SK, Suganthirababu P, Gopal K, et al. The effectiveness of low-level laser therapy combined with facial expression exercises in patients with moderate-to-severe Bell's palsy: a study protocol for a randomised controlled trial. *Int J Surg Protoc* [Internet]. 2020; 24: 39-44. Available from: <https://doi.org/10.1016/j.isjp.2020.11.001>
4. Poloni MM, Marques NP, Ribeiro Junior NV, Sperandio FF, Hanemann JA, De Carli ML. Bell's palsy treated with photobiomodulation in an adolescent: rare case report and review of the published literature. *Int J Paediatr Dent* [Internet]. 2018; 28(6): 658-662. Available from: <https://doi.org/10.1111/ipd.12424>
5. Javaherian M, Attarbashi Moghaddam B, Bashardoust Tajali S, Dabbaghpour N. Efficacy of low-level laser therapy on management of Bell's palsy: a systematic review. *Lasers Med Sci* [Internet]. 2020; 35(6): 1245-1252. Available from: <https://doi.org/10.1007/s10103-020-02996-2>
6. Ladalardo TC, Brugnera A Jr, Takamoto M, Pinheiro AL, Campos RA, Garrini AE, et al. Functional and electrophysiological evaluation of the effect of laser therapy in the treatment of peripheral facial paralysis. *Lasers Dent VII* [Internet]. 2001; 4249: 134-138. Available from: <https://doi.org/10.1117/12.424489>
7. Marques AM, Soares LG, Marques RC, Pinheiro AL, Dent M. Laser phototherapy as modality of clinical treatment in Bell's palsy. *Am Inst Phys* [Internet]. 2011; 1364(1): 66-69. Available from: <https://doi.org/10.1063/1.3626914>
8. Fontana CR, Bagnato VS. Low-level laser therapy in pediatric bell's palsy: case report in a 3-year

- old child. *J Altern Complement Med* [Internet]. 2013; 19(4): 376-382. Available from: <https://doi.org/10.1089/acm.2011.0531>
9. Rubis LM. Chiropractic management of Bell palsy with low level laser and manipulation: a case report. *J Chiropr Med* [Internet]. 2013; 12(4): 288-291. Available from: <https://doi.org/10.1016/j.jcm.2013.10.001>
 10. Tanganeli JP, De Oliveira SS, Da Silva T, Fernandes KP, Motta LJ, Bussadori SK. Complete and fast recovery from idiopathic facial paralysis using laser-photobiomodulation. *Case Rep Dent* [Internet]. 2020; 2020(1): 9867693. Available from: <https://doi.org/10.1155/2020/9867693>
 11. Panhóca VH, Nogueira MS, Bagnato VS. Laser and vacuum therapy for treatment of facial nerve palsies [Internet]. In: Wong BJ, Ilgner JF, editors. *Imaging, Therapeutics, and Advanced Technology in Head and Neck Surgery and Otolaryngology*. SPIE Digital Library; 2022. pp. 39-48. Available from: <https://doi.org/10.1117/12.2610150>
 12. Gjurin SZ, Pang J, Vrčkovnik M, Hanna R. Efficacy of 1064 nm photobiomodulation dosimetry delivered with a collimated flat-top handpiece in the management of peripheral facial paralysis in patients unresponsive to standard treatment care: a case series. *J Clin Med* [Internet]. 2023; 12(19): 6294. Available from: <https://doi.org/10.3390/jcm12196294>
 13. Nadhreen AA, Alamoudi NM, Elkhodary HM. Low-level laser therapy in dentistry: extra-oral applications. *Niger J Clin Pract* [Internet]. 2019; 22(10): 1313-1318. Available from: https://doi.org/10.4103/njcp.njcp_53_19
 14. Gazoni FM, Malezan WR, Santos FC. B complex vitamins for analgesic therapy. *Rev Dor* [Internet]. 2016; 17(1): 52-56. Available from: <https://doi.org/10.5935/1806-0013.20160013>
 15. Ordahan B, Karahan AY. Role of low-level laser therapy added to facial expression exercises in patients with idiopathic facial (Bell's) palsy. *Lasers Med Sci* [Internet]. 2017; 32(4): 931-936. Available from: <https://doi.org/10.1007/s10103-017-2195-9>
 16. Magazi D, Longombenza B, Mda S, Van der Meyden K, Motshwane M, Nanjoh M, et al. HIV infection, seasonality and younger age predicting incident Bell's palsy among black South Africans. *BMC Neurol* [Internet]. 2020; 20: 381. Available from: <https://doi.org/10.1186/s12883-020-01965-0>
 17. Monini S, Lazzarino AI, Iacolucci C, Buffoni A, Barbara M. Epidemiology of Bell's palsy in an Italian health district: incidence and case-control study. *Acta Otorhinolaryngol Ital* [Internet]. 2010; 30(4): 198. Available from: <https://www.ncbi.nlm.nih.gov/pmc/articles/PMC3008145/>
 18. Zhang W, Xu L, Luo T, Wu F, Zhao B, Li X. The etiology of Bell's palsy: a review. *J Neurol* [Internet]. 2019; 267(7): 1896-1905. Available from: <https://doi.org/10.1007/s00415-019-09282-4>
 19. Mancini P, Bottaro V, Capitani F, De Soccio G, Prosperini L, Restaino P, et al. Recurrent Bell's palsy: outcomes and correlation with clinical comorbidities. *Acta Otorhinolaryngol Ital* [Internet]. 2019; 39(5): 316-321. Available from: <https://doi.org/10.14639/0392-100x-2415>



Available in:

<https://www.redalyc.org/articulo.oa?id=421582849008>

How to cite

Complete issue

More information about this article

Journal's webpage in redalyc.org

Scientific Information System Redalyc
Diamond Open Access scientific journal network
Non-commercial open infrastructure owned by academia

Fernanda Leme Silva, Brena Rodrigues Manzano,
Mailon Cury Carneiro, Ludimila Lemes Moura,
Dayanne Simões Ferreira Santos,
Cássia Maria Fischer Rubira, Paulo Sérgio da Silva Santos
**Photobiomodulation as adjuvant therapy for Bell's palsy:
a case series**
**Fotobiomodulación como terapia coadyuvante para la
parálisis de Bell: una serie de casos**
**Fotobiomodulação como terapia adjuvante para paralisia
de Bell: uma série de casos**

Revista Estomatológica Herediana
vol. 34, no. 3, p. 263 - 276, 2024
Universidad Peruana Cayetano Heredia. Facultad de
Estomatología,
ISSN: 1019-4355
ISSN-E: 2225-7616

DOI: <https://doi.org/10.20453/reh.v34i3.5837>