



Revista Estomatológica Herediana

ISSN: 1019-4355

ISSN: 2225-7616

faest.revista@oficinas-upch.pe

Universidad Peruana Cayetano Heredia

Perú

Alfaro Pacheco, Carlos; López-Torres, Ana Cristina  
Oral surgery in patients with classic and direct oral anticoagulants: a literature review  
Revista Estomatológica Herediana, vol. 35, no. 2, 2025, April-June, pp. 139-149  
Universidad Peruana Cayetano Heredia  
Lima, Perú

DOI: <https://doi.org/10.20453/reh.v35i2.6464>

Available in: <https://www.redalyc.org/articulo.oa?id=421582899008>

- ▶ [How to cite](#)
- ▶ [Complete issue](#)
- ▶ [More information about this article](#)
- ▶ [Journal's webpage in redalyc.org](#)

redalyc.org

Scientific Information System Redalyc

Diamond Open Access scientific journal network

Non-commercial open infrastructure owned by academia

## Oral surgery in patients with classic and direct oral anticoagulants: a literature review

 Carlos Alfaro Pacheco<sup>1, a, b, c, d,</sup>

 Ana Cristina López-Torres<sup>2, a, d, e, f</sup>

<sup>1</sup> Universidad Peruana Cayetano Heredia, Faculty of Stomatology. Lima, Peru.

<sup>2</sup> Universidad Latina de Costa Rica. San José, Costa Rica.

<sup>a</sup> Specialist in Stomatology for Special Patients.

<sup>b</sup> Specialist in Public Stomatological Health.

<sup>c</sup> Master's Degree in Geriatrics and Gerontology.

<sup>d</sup> University professor.

<sup>e</sup> Master's Degree in Education with an emphasis on Teaching and Research in Higher Education.

<sup>f</sup> Resident in Geriatric Dentistry.

### ABSTRACT

For decades, vitamin K antagonists such as warfarin have been the standard anticoagulant treatment, despite the clinical management challenges they present. In contrast, direct oral anticoagulants (DOACs) offer fewer complications and therapeutic advantages. These are classified into thrombin inhibitors (dabigatran) and factor Xa inhibitors (rivaroxaban, apixaban, edoxaban). Approximately 10% of anticoagulated patients will require some form of surgery, including oral surgery. In this context, the objective of this review was to update oral surgical management in anticoagulated patients and to familiarize dentists with protocols for warfarin and DOAC users. Discontinuing anticoagulant therapy carries significant and even fatal risks, which in many cases outweigh the benefits of reducing bleeding during oral surgery. It is concluded that anticoagulant therapy should only be suspended for procedures with a high risk of bleeding, and it is essential to evaluate the bleeding risk of the procedure beforehand and apply hemostatic measures when necessary.

**Keywords:** anticoagulants; oral surgery; blood coagulation; dentistry.

**Received:** March 27, 2024

**Accepted:** April 15, 2025

**Online:** June 30, 2025



Open access article

© The authors

© Revista Estomatológica Herediana

### Cite as:

Alfaro C, López-Torres AC. Oral surgery in patients with classic and direct oral anticoagulants: a literature review. Rev Estomatol Herediana. 2025; 35(2): 119-128. DOI: 10.20453/reh.v35i2.6464

## INTRODUCTION

Over the past 60 years, vitamin K antagonists (VKAs), such as warfarin, have been the main preventive anticoagulant therapy for patients with conditions such as atrial fibrillation, history or risk of cerebrovascular accidents, coronary heart disease, deep vein thrombosis, previous myocardial infarction, and cardiac valve prostheses, among others (1-3). However, VKAs are challenging to manage due to their multiple drug interactions, unpredictable pharmacodynamics, high interindividual variability, and narrow therapeutic window. In addition, they require continuous monitoring through the International Normalized Ratio (INR) test to adjust the dosage on an individual basis (1, 2).

These limitations prompted the development of direct oral anticoagulants (DOACs), which offer fixed dosing, do not require routine laboratory monitoring, and have fewer drug–drug and food interactions, with a rapid onset of action and short half-lives (2-4). These anticoagulants are divided into two subgroups: direct thrombin inhibitors, such as dabigatran (Pradaxa®), and direct factor Xa inhibitors, such as rivaroxaban (Xarelto®), apixaban (Eliquis®), and edoxaban (Lixiana®). Moreover, their prescription is increasing, supported by studies confirming their therapeutic efficacy and effectiveness (1, 4).

Approximately 10% of anticoagulated patients will require an invasive procedure, including oral and dental surgery (2, 3, 5). Therefore, the management of patients taking DOACs poses a challenge for dentists due to their recent introduction and different management compared with warfarin, the most common VKA. With warfarin, INR assessment guides whether therapy should be continued or temporarily interrupted. By contrast, DOACs—relatively recent in clinical practice and less familiar to dental practitioners—have shorter half-lives, facilitating brief perioperative interruption and resumption when necessary, potentially reducing thrombotic risk (1, 4-6).

This review aims to summarize current evidence on oral surgical management of patients taking oral anticoagulants, as well as to familiarize dentists with the surgical protocol for dental procedures for patients treated with warfarin and DOACs.

## METHODS

The literature selection proceeded in five stages. First, the subtopics to be addressed were defined: hemostasis, anticoagulants, and tooth extraction in patients taking anticoagulants. In the second stage, scientific articles and textbooks were searched in the Scientific Electronic Library Online (SciELO), PubMed, and Google Scholar databases, using search descriptors from the Medical

Subject Headings (MeSH) and the *Descriptores en Ciencias de la Salud (DeCS)*: “anticoagulantes,” “cirugía bucal,” and “tooth extraction,” in Spanish, English, and Portuguese. The third stage involved applying inclusion and exclusion criteria. Full-text articles available online in English, Spanish, or Portuguese were included, whereas those addressing hemostatic disorders caused by systemic, hereditary, or acquired diseases were excluded. In the fourth stage, texts were organized by section, and in the fifth, irrelevant, contradictory or scientifically unsound studies were eliminated. Finally, 18 relevant sources were selected for the review.

## HEMOSTASIS

Hemostasis is a complex system that stops bleeding through physiological responses following injury to a blood vessel. Its objective is to prevent and control blood loss, maintain blood in a fluid state within the vasculature, and ultimately restore the integrity of the affected vessel. A fibrin polymer network, together with platelet, forms the hemostatic plug; once vascular repair is complete, the fibrinolytic system dissolves the fibrin scaffold (7, 8).

### Physiology of hemostasis: classical model

Damage to the wall of a blood vessel exposes collagen and releases adhesive and activating proteins that trigger primary hemostasis through its vascular and platelet phases. During the vascular phase, vasoconstriction and retraction of the injured vessels are the main physiological responses. The platelet phase begins when von Willebrand factor (vWF), acting as a bridge, facilitates platelet adhesion to the exposed collagen. Following adhesion, platelet activation and aggregation occur, forming an unstable platelet plug, which marks the completion of primary hemostasis.

Stabilization of this plug is achieved through secondary hemostasis, also known as blood coagulation. In this process, two separate pathways (intrinsic and extrinsic) converge to activate the common coagulation pathway. The extrinsic pathway, faster and shorter, begins with the release of tissue thromboplastin, which activates factor VII and subsequently factor X in the common pathway. The intrinsic pathway, slower, is initiated by the activation of factor XII at the site of injury, followed by factors XI, IX, and VIII, which also activate factor X. In the common pathway, factor Xa, together with factors IV and V and platelet phospholipids, converts prothrombin into thrombin, which in turn transforms fibrinogen into fibrin. Fibrin forms a mesh that stabilizes the platelet plug. Once the vessel is repaired, the fibrinolytic system dissolves the fibrin mesh, removing the plug (3, 7-9).

**Table 1.** Hemostasis evaluation tests, their interpretation, and precautions in oral surgery.

Test	Definition	Normal range	Interpretation	Precaution
Platelet count	Number of platelets per microliter of blood.	150-350×10 <sup>3</sup> platelets/mL	Decreased count (thrombocytopenia): risk of bleeding; petechiae or ecchymoses are common findings.  Increased count (thrombocytosis): may increase the risk of thrombus formation in some cases.	Counts between 50-100×10 <sup>3</sup> require skill in hemorrhage control and use of local hemostatic techniques.  Below 50×10 <sup>3</sup> : hospital management is required.
Bleeding time	Evaluates primary hemostasis (vascular and platelet phases).	2-8 min	Prolonged time: may indicate platelet dysfunction or the effect of certain medications.	Interpret the result in conjunction with other laboratory test results.
Clotting time	Evaluates secondary hemostasis or blood coagulation.	5-10 min	Prolonged time: risk of bleeding. May indicate severe deficiency of coagulation factors from one or more pathways (extrinsic, intrinsic, or common).	Interpret the result in conjunction with other laboratory test results.
Activated partial thromboplastin time (aPTT)	Evaluates the intrinsic and common pathways.	30-45 s	Prolonged time: may indicate deficiencies in coagulation factors VIII, IX, XI, or XII, or hereditary/acquired disorders.	Abnormal results should be complemented with tests for detection of hereditary or acquired conditions.
Prothrombin time (PT)	Evaluates the extrinsic and common pathways.	11-13.5 s	Prolonged time: may indicate deficiencies in coagulation factors V, VII, X, prothrombin, or fibrinogen, leading to risk of bleeding.	Abnormal results should be complemented with tests for detection of hereditary or acquired conditions.
International Normalized Ratio (INR)	Calculated from PT.	0.8-1.2 de INR	Elevated INR: indicates risk of bleeding, especially relevant in patients using anticoagulants such as warfarin. The therapeutic INR range is defined by the physician according to the patient's medical condition.	Values above 3.0: management by a professional trained in bleeding control and local hemostatic techniques is recommended.
Thrombin time (TT)	Evaluates the conversion of fibrinogen to fibrin.	9-13 s	Prolonged time: indicates risk of bleeding. It may occur in patients with fibrinogen deficiency or systemic diseases.	Abnormal results should be complemented with additional tests to rule out hereditary or acquired conditions.
Plasma fibrinogen	Measures the amount of fibrinogen present in blood plasma.	200-400 mg/dL	Elevated values: as an acute-phase protein, fibrinogen levels may increase in cases of inflammation, infection, or acute trauma. Indicates a higher risk of thrombosis.	Elevated concentrations may result from smoking or genetic factors. It is considered a risk factor for acute myocardial infarction. During pregnancy, fibrinogen levels tend to increase, which should be taken into account for interpretation.

Under normal conditions, there is a balance between coagulation and its inhibitory factors; however, disruption of this complex system may result in thrombotic or hemorrhagic events (7, 8).

### Hemostasis evaluation

The coagulation profile, or coagulogram, allows for a qualitative and quantitative evaluation of the hemostasis process according to the classical model. This profile

includes platelet count, bleeding time, clotting time, activated partial thromboplastin time, prothrombin time, and INR (3). Each of these parametric tests is used to evaluate specific stages of hemostasis. Bleeding time (BT) is used to assess primary hemostasis. Secondary hemostasis is globally evaluated through clotting time (CT), whereas individual pathways are assessed with prothrombin time (PT)—also expressed as INR for the extrinsic pathway—and activated partial thromboplastin time (aPTT) for the intrinsic pathway (2) (Table 1).

## WARFARIN, A CONVENTIONAL ORAL ANTICOAGULANT

Anticoagulants were first developed in 1916, when J. McLean succeeded in isolating liver extracts from dogs with anticoagulant properties, later named heparin. In the 1940s, the well-known vitamin K antagonists (VKAs) such as dicoumarol, hydroxycoumarin, and warfarin appeared. However, it was not until 1954 that clinical use in humans was approved (9).

Warfarin action—the most widely used VKA in public health systems—consists of blocking the conversion of inactive vitamin K (epoxide) into its active form (hydroquinone) in the liver. The lack of active vitamin K prevents factors II, VII, IX, and X, as well as proteins C and S (natural anticoagulants), from becoming active, since they are unable to bind calcium (9, 10).

Warfarin is well absorbed, and its overdose can be reversed with prothrombin complex concentrates. It is affordable and accessible but has several disadvantages that complicate its management (11). It has a narrow therapeutic range (INR between 2 and 4), which can lead to either insufficient anticoagulation or a significant risk of bleeding. An INR below 2 reduces protection against thromboembolic events, while values above 4 increase the risk of hemorrhage. Moreover, it presents numerous interactions with food and other drugs, and patients remain within the therapeutic range only 60-70% of the time. Warfarin also requires individualized dosing, has unpredictable pharmacodynamics, demands strict medical monitoring, and is associated with teratogenicity and miscarriage risk (4, 6, 9).

## NEW DIRECT ORAL ANTICOAGULANTS

In the last decade, DOACs have transformed anticoagulant therapy, becoming an alternative to VKAs and gaining importance in clinical practice (7). They offer a more predictable pharmacokinetic profile, a wider therapeutic range, a rapid onset of action (within 2-4 hours after administration), a shorter half-life, fixed dosing, no requirement for routine INR monitoring, and minimal drug and food interactions. However, their high cost

and limitations in patients with renal impairment have prevented their widespread adoption. These anticoagulants are classified as: direct thrombin inhibitors (FIIa) and direct activated factor X inhibitors (Xa), which are key enzymes in the final phase of coagulation, achieving a rapid onset of action similar to that of subcutaneous heparins (3, 11, 12).

### Direct thrombin inhibitors

Dabigatran, the first DOAC approved by the U.S. Food and Drug Administration (FDA), is a direct and specific thrombin inhibitor administered orally. It has a rapid onset of action (0.5-2 hours) and a half-life of 12-17 hours. Its bioavailability is low (6-7%), and it is mainly excreted by the kidneys; therefore, it is contraindicated in patients with a creatinine clearance below 30 mL/min. It does not require monitoring, is administered at a fixed dose twice daily (11, 12). Dabigatran is contraindicated during pregnancy and lactation, and has an available specific antidote (idarucizumab). The recommended dose is 150 mg every 12 hours, although a reduced dose is indicated for patients over 80 years of age or with severe renal impairment (8, 11, 12).

### Direct factor Xa inhibitors

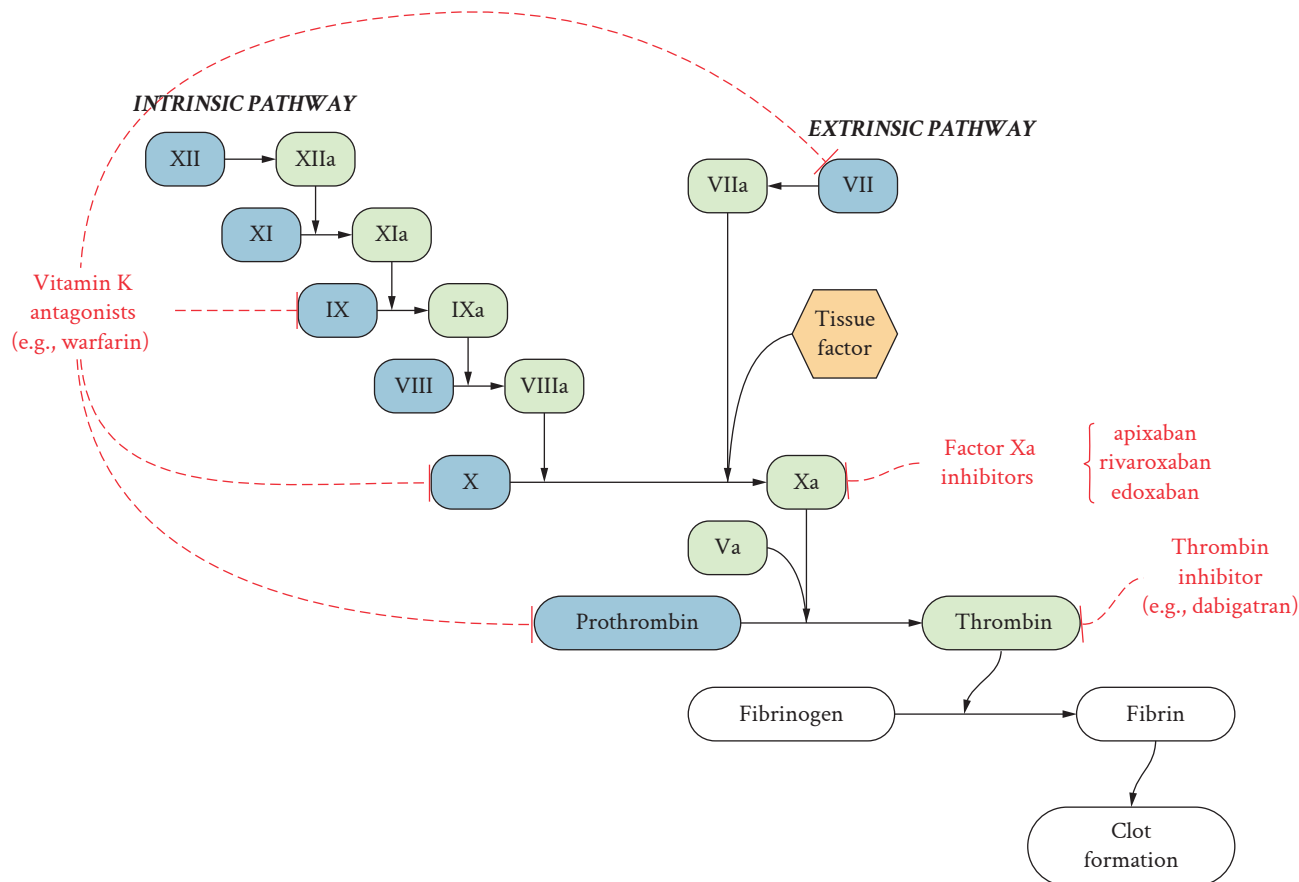
Factor Xa inhibitors, such as rivaroxaban, apixaban, and edoxaban, provide anticoagulation with fixed dosing and no need for routine monitoring. Rivaroxaban is rapidly absorbed, reaches its peak plasma concentration within 2-4 hours, and is partially excreted through the kidneys; therefore, it is not recommended in patients with severe renal impairment. Moreover, its dose is 20 mg once daily (11, 12, 13). Apixaban, used to prevent cerebrovascular events, has a bioavailability below 50% and a half-life of 3-12 hours, with a standard dose of 5 mg twice daily, adjustable in patients with severe renal disease (11, 13-15). Edoxaban, which is rapidly absorbed and has a half-life of 10-14 hours, is administered at a dose of 60 mg once daily, reduced by half in patients with moderate to severe renal impairment. All these inhibitors show few drug interactions, although certain medications can alter their plasma levels (11, 12, 14, 16). Meanwhile, andexanet alfa is the current antidote for reversing the anticoagulant effect of factor Xa inhibitors, thus achieving effective hemostasis (11).

## SITES OF ACTION OF ANTICOAGULANTS

The classical cascade model of coagulation factor activation provides a clear explanation of the sites of action of warfarin and the locations where DOACs act. Warfarin acts by blocking the vitamin K-dependent coagulation factors II, VII, IX, and X. Direct factor Xa inhibitors, such as apixaban, rivaroxaban, and edoxaban, inhibit

this factor, preventing the conversion of prothrombin to thrombin, a key step in the coagulation process. Dabigatran, on the other hand, is a direct thrombin inhibitor that blocks its activity, thereby preventing the conver-

sion of fibrinogen into fibrin. These medications reduce the body's ability to form a fibrin network, but they do so through different mechanisms (10, 12) (Figure 1).



**Figure 1.** Sites of action of oral anticoagulants in the coagulation cascade (10, 12, 17).

## ORAL SURGERY IN PATIENTS TAKING ORAL ANTICOAGULANTS

The management of anticoagulated patients requiring surgery aims primarily to prevent severe or potentially life-threatening bleeding while minimizing the risk of thromboembolism. Major procedures, such as intra-abdominal or intrathoracic surgery for cancer, head and neck tumor resection, and reduction of facial fractures, carry a high risk of bleeding, whereas simple or multiple dental extractions and alveolectomies generally pose a lower risk (3, 18).

Low-bleeding-risk oral procedures can generally be performed without interrupting anticoagulation. These include dental fillings, scaling and root planing, tooth polishing, small soft tissue biopsies, prosthodontic procedures, endodontic treatments, implant placement, and extractions involving fewer than three teeth at a time. Moderate- to high-risk procedures, which have a greater likelihood of bleeding, include multiple extractions involving five or more teeth, extensive subgingival de-

bridement, periodontal surgery, extractions with mucoperiosteal flap elevation, bone extractions, soft tissue biopsies larger than 2.5 cm, bone biopsies, placement of multiple implants, cyst removal, and head and neck tumor resection. In these cases, the need to continue or temporarily discontinue anticoagulant therapy should be carefully evaluated, considering the patient's comorbidities (4, 5, 18-20).

Preoperative management should begin with a thorough clinical assessment to identify bleeding risk factors. Signs such as previous hemorrhages, hematomas, and ecchymoses may indicate an underlying hemostatic disorder (18). It has been reported that up to 25% of anticoagulated patients experience oral bleeding after tooth extraction, and the risk of bleeding may be up to three times higher than in patients not taking anticoagulants (19, 21). In cases of intra- or postoperative bleeding, hemostasis can be achieved with local hemostatic measures such as mechanical pressure, hemostatic agents (e.g., collagen sponges), sutures, and tranexamic acid in paste or mouthwash formulations (18, 21) (Table 2).

**Table 2.** Oral surgery in anticoagulated patients: perioperative recommendations by bleeding risk.

	Type of surgery			
	Low-bleeding-risk oral surgery		High-bleeding-risk oral surgery	
	Drugs used		Drugs used	
	Warfarin	DOACs	Warfarin	DOACs
Initial evaluation	INR < 4.0  INR > 4.0: referral to the treating physician is required	Evaluate the dosage and timing of medication intake.	INR lower or higher than 4.0: hospital management or treatment suspension as indicated by the treating physician.	Evaluate the dosage and timing of medication intake.
Discontinuation decision	Not required	Not required	Assessment by the treating physician: discontinuation for 5 days may be recommended, with or without bridging therapy (heparin).	Assessment by the treating physician: perioperative dose suspension may be recommended, and the medication can be resumed normally once the procedure is completed.
Preoperative recommendations	Inform the patient that bruising may occur in areas where pressure is applied by the clinician and in perioperative areas.  INR testing should be performed on the day of the procedure should be below 4.0.	Inform the patient that bruising may occur in areas where pressure is applied by the clinician and in perioperative areas.	Inform the patient that bruising may occur in areas where pressure is applied by the clinician and in perioperative areas.  INR test on the day of the procedure within ranges below 1.7.	Inform the patient that bruising may occur in areas where pressure is applied by the clinician and in perioperative areas.
Intraoperative recommendations	Use local anesthesia with intraligamentary, intraseptal, or infiltrative techniques.  Perform procedures as atraumatically as possible and keep operative time short.  Primary intention closure: use of sutures.  Use of local hemostatic techniques such as collagen sponges, gauze compression, or local tranexamic acid.	Use local anesthesia with intraligamentary, intraseptal, or infiltrative techniques.  Perform procedures as atraumatically as possible and keep operative time short  Primary intention closure: use of sutures.  Use of local hemostatic techniques such as collagen sponges, gauze compression, or local tranexamic acid.	Use local anesthesia with intraligamentary, intraseptal, or infiltrative techniques.  Nerve block techniques should only be used if warfarin therapy has been discontinued; otherwise, this technique is contraindicated.  Perform procedures as atraumatically as possible and keep operative time short  Primary intention closure: use of sutures.  Use of local hemostatic techniques such as collagen sponges, gauze compression, or local tranexamic acid.	Use local anesthesia with intraligamentary, intraseptal, or infiltrative techniques.  Perform procedures as atraumatically as possible and keep operative time short  Primary intention closure: use of sutures.  Use of local hemostatic techniques such as collagen sponges, gauze compression, or local tranexamic acid.
Postoperative recommendations	Avoid the use of NSAIDs or aspirin.	Avoid the use of NSAIDs or aspirin.  In patients taking rivaroxaban, avoid opioids and macrolide antibiotics.	Avoid the use of NSAIDs or aspirin.	Avoid the use of NSAIDs or aspirin.  In patients taking rivaroxaban, avoid opioids and macrolide antibiotics.

DOACs: direct oral anticoagulants; INR: International Normalized Ratio; NSAIDs: nonsteroidal anti-inflammatory drugs.

**Table 2.** (Continuation).

	Type of surgery			
	Low-bleeding-risk oral surgery		High-bleeding-risk oral surgery	
	Drugs used		Drugs used	
	Warfarin	DOACs	Warfarin	DOACs
Management of bleeding cases	<p>Check for suture disruption or loose tissue.</p> <p>Use of local hemostatic techniques such as collagen sponges, gauze compression, or local tranexamic acid.</p>	<p>Check for suture disruption or loose tissue.</p> <p>Use of local hemostatic techniques such as collagen sponges, gauze compression, or local tranexamic acid.</p> <p>Review medication intake and possible drug interactions.</p>	<p>Check for suture disruption or loose tissue.</p> <p>Use of local hemostatic techniques such as collagen sponges, gauze compression, or local tranexamic acid.</p> <p>Review medication intake and possible drug interactions.</p>	<p>Check for suture disruption or loose tissue.</p> <p>Use of local hemostatic techniques such as collagen sponges, gauze compression, or local tranexamic acid.</p> <p>Review medication intake and possible drug interactions.</p> <p>Cases of persistent or excessive bleeding require hospital management.</p>

DOACs: direct oral anticoagulants; INR: International Normalized Ratio; NSAIDs: nonsteroidal anti-inflammatory drugs.

## ORAL SURGERY IN PATIENTS TAKING WARFARIN

For warfarin-treated patients, guidelines indicate that low-risk dental procedures are generally safe if INR remains between 2.0 and 4.0 and local hemostatic measures are applied. If the INR is greater than 4.0, procedures should be performed in a hospital setting (3, 6, 12). In cases of surgeries with a high risk of hemorrhage, only a medical specialist (cardiologist, hematologist, or other) can suspend the warfarin. Generally, it is stopped five days before surgery, with INR monitoring (values below 1.5 allow procedures to be performed with minimum risk of bleeding). For patients with a high thrombotic risk, a “bridge” with low-molecular-weight heparin (LMWH) is usually administered, which is discontinued between 12 and 24 hours before surgery, and warfarin or LMWH is resumed 24 hours afterward, according to the specialist physician’s indication (18–20). It is recommended to avoid nerve blocks (or “major nerve blocks”) in anticoagulated patients, except if the INR is below 3.0 in warfarin patients. Local infiltrative, intraligamentary, and intraseptal anesthesia techniques are preferable due to their lower risk of bleeding (2, 12, 20).

## ORAL SURGERY IN PATIENTS TAKING DIRECT ORAL ANTICOAGULANTS

The available information on the risk of bleeding during and after surgical procedures in patients using DOACs is limited. Furthermore, unlike warfarin, there is no reliable laboratory analysis like the INR that can predict the risk of hemorrhage in these patients (16, 20). Therefore, the approach to oral surgical management in these patients must focus on evaluating both the bleeding risk associated with the dental procedure and the danger of a thrombotic event if the anticoagulant treatment is modified or interrupted. This decision must be made in collaboration with the treating physician (16, 19).

Low-bleeding risk dental procedures do not require interruption of DOAC use. In the case of patients taking a single daily dose of a DOAC, it is recommended to schedule the dental intervention between 18 and 24 hours after the last dose, and to restart the treatment 6 hours after the procedure. For patients on twice-daily

regimens, omitting a single dose before the intervention will suffice. For high-bleeding-risk surgical procedures, a preoperative multidisciplinary approach is necessary, which generally involves the suspension of DOACs. Given that these drugs have a short half-life, the interruption can be done close to the day of surgery, which reduces the patient's exposure time to thrombotic risks and eliminates the need for bridging therapy (18, 20).

Certain medications used by the dentist for pain control can interact with anticoagulants. Nonsteroidal anti-inflammatory drugs (NSAIDs), including aspirin, should not be used in these cases, as they increase the risk of bleeding in patients treated with warfarin or DOACs. Moreover, rivaroxaban, when combined with opioid analgesics or macrolide antibiotics such as erythromycin and clarithromycin, may increase its anticoagulant effect and therefore the risk of bleeding (19, 20).

DOACs have specific antidotes, although in most cases their short half-life allows control of bleeding simply by discontinuing the drug. In severe situations, additional treatments such as fluid replacement, transfusions, or administration of prothrombin complex concentrates can be considered for factor Xa antagonists. For dabigatran, hemodialysis is an option, and recently agents such as idarucizumab for dabigatran and andexanet alfa for factor Xa inhibitors have been approved (11, 18). However, due to the short duration of DOAC effects, it is usually not necessary to use these antidotes to achieve hemostasis (20).

## DISCUSSION

The oral surgical management of patients under oral anticoagulant therapy is controversial, as there is no clear consensus on the course of action. Some professionals prefer to discontinue the anticoagulant to reduce the risk of hemorrhage, even in low-risk procedures, which is a common practice. Others prefer to maintain this therapy to avoid the risk of thromboembolic events (4, 5, 18, 19). Controversy lies in the ability to control hemorrhage during oral surgery. Although anticoagulated patients have reduced hemostatic function, discontinuing treatment may entail significant morbidity risks and can even be fatal. In general, the risks associated with discontinuing anticoagulant therapy outweigh the potential benefits of reducing postoperative bleeding; therefore, suspension should only be considered for procedures with a high risk of hemorrhage, and only if deemed necessary by the treating physician.

Discontinuation of warfarin therapy is generally not recommended if the dental surgical procedure carries a low risk of bleeding, the INR values are below 4.0, and local hemostatic measures are available (5, 18, 19). Another point of controversy in the management of this antico-

agulant is whether or not to implement bridging therapy with unfractionated heparin ("heparin windows"). In this protocol, warfarin is discontinued and temporarily replaced by multiple doses of low-molecular-weight heparin (19). In high-bleeding risk procedures, the dentist must consult the specialty physician (cardiologist or hematologist), as the decision to discontinue anticoagulants or to implement bridging therapy is the sole responsibility of the specialty physician, not the dentist.

Warfarin typically reaches its therapeutic range (INR 3.0-4.0) about 72 hours after initiation. If it is withheld prior to oral surgery, the INR commonly decreases to ~1.5 over four days; the actual value should be confirmed by same-day PT/INR testing (4, 19, 21). After surgery, warfarin should be resumed immediately, or, if bridging therapy was used, heparin administration should be discontinued, always following the treating physician's instructions (19, 20).

The risk of bleeding after tooth extraction is 1% in individuals who do not take anticoagulants. However, in patients who use them, this risk increases and is considered significant if the bleeding lasts more than 12 hours, if the patient needs to return to the dental office or emergency department, or if large hematomas or ecchymoses develop in the oral area (12, 18, 19). If any of these situations occur, possible drug interactions and factors contributing to the bleeding (such as trauma, suture disruption, or other causes) should be investigated. Treatment should then be based on the use of local hemostatic measures (mechanical pressure with gauze, hemostatic agents such as collagen sponges, sutures, and tranexamic acid), antidotes, and discontinuation of the medication in the case of DOACs. These measures should be sufficient to correct most bleeding issues. In more severe cases of hemorrhage, the need for blood transfusion under hospital management should be evaluated.

DOACs are relatively new medications in the medical field, and there is still no complete standardization for their management in oral surgery. Nevertheless, most authors agree that stomatological procedures with a low risk of bleeding do not require discontinuation of these drugs. For procedures with a high risk of bleeding, it is recommended to discontinue DOACs between 12 and 24 hours before surgery and to resume them 24 hours afterward (20, 21). It is important to emphasize that, as with warfarin, only the treating specialist physician is authorized to decide on the temporary discontinuation of the medication.

It has been observed that the incidence of hemorrhagic events after tooth extraction in patients taking DOACs does not differ from that in those taking warfarin. Therefore, precautions such as the use of local hemostatic measures are recommended. If bleeding persists

and does not respond to these measures, or occurs spontaneously, medical attention should be sought urgently (19). However, due to the short half-life of DOACs, temporary discontinuation of the drug, combined with local hemostatic measures, is usually sufficient to manage most hemorrhagic complications (20).

Among the limitations of this review, the lack of information regarding oral surgical procedures in anticoagulated patients within the Latin American population stands out. Having such data would allow for a better understanding of how dentists in the region manage these patients in clinical practice. Furthermore, evidence on intraoperative and postoperative bleeding during surgical procedures in patients taking DOACs remains limited, highlighting the need for further studies in this field.

## CONCLUSIONS

DOACs, being relatively new and managed differently from warfarin, remain little known in dentistry. For this reason, it is essential that dentists understand these drugs and their mechanisms of action, as this knowledge will allow them to make more accurate clinical decisions and better manage potential hemorrhagic complications during oral surgical procedures. Discontinuation of anticoagulant therapy carries significant morbidity risks and can even be fatal; therefore, in most cases, the risks of interrupting anticoagulation outweigh the benefits of reducing postoperative bleeding. Suspension should only be considered for procedures with a high risk of bleeding and always under the supervision of the treating physician. In dental surgeries, assessing bleeding risk, knowing the INR value (in the case of warfarin), and applying local hemostatic measures are key to preventing complications in patients taking anticoagulants.

### Conflict of interest:

The authors declare no conflict of interest.

### Funding:

Self-funded.

### Author contributions:

**CAP:** conceptualization, research, methodology, project administration, resources, supervision, visualization, writing – original draft, writing – review & editing.

**ACL:** conceptualization, research, resources, visualization, writing – review & editing.

### Corresponding author:

Carlos Alfaro Pacheco

✉ [Carlos.alfaro.p@upch.pe](mailto:Carlos.alfaro.p@upch.pe)

## REFERENCES

- Hiroshi I, Natsuko SY, Yutaka I, Masayori S, Hiroyuki N, Hirohisa I. Frequency of hemorrhage after tooth extraction in patients treated with a direct oral anticoagulant: a multicenter cross-sectional study. *PLoS ONE* [Internet]. 2022; 17(4): e0266011. Available from: <https://doi.org/10.1371/journal.pone.0266011>
- Barros BL, Vasconcelos AF, Barros GL, Medeiros MD. [Antiagregant platelet and anticoagulant drugs in patients who will submit oral surgery: conduct]. *Rev Cir Traumatol Buco-Maxilo-Fac* [Internet]. 2022; 22(3): 58-63. Available from: <https://www.revistacirurgiabmf.com/2022/03/Artigos/10AC-Drogasantiagregantesplaquetarias.pdf> Portuguese.
- Da Silva TE, De Araújo EC, Rocha MP, De Oliveira LM. [Surgical management of patients undergoing oral anticoagulant therapy]. *Rev Pró-Uni* [Internet]. 2019; 10(1): 145-149. Available from: <https://doi.org/10.21727/rpu.v10i1.1751> Portuguese.
- González F, Álvarez A, Torres J, Fernández-Tresguerres I. [Novel oral anticoagulants: dental impact]. *Cient Dent* [Internet]. 2016; 13(2): 139-148. Available from: <https://coem.org.es/pdf/publicaciones/cientifica/vol13num2/9.NuevosAnticoagulantes.pdf> Spanish.
- Moreno-Drada JA, Abreu LG, Lino PA, Martins MA, Pordeus IA, Abreu MH. Effectiveness of local hemostatic to prevent bleeding in dental patients on anticoagulation: a systematic review and network meta-analysis. *J Craniomaxillofac Surg* [Internet]. 2021; 49(7): 570-583. Available from: <https://doi.org/10.1016/j.jcms.2021.04.014>
- Steed MB, Swanson MT. Warfarin and newer agents: what the oral surgeon needs to know. *Oral Maxil-*

- lofac Surg Clin North Am [Internet]. 2016; 28(4): 515-521. Available from: <https://doi.org/10.1016/j.coms.2016.06.011>
7. Hall JE. Guyton y Hall. Tratado de fisiología médica. 13th ed. Barcelona: Elsevier; 2017.
  8. Silverthorn DU. Fisiología humana: una abordagem integrada. 7th ed. Porto Alegre: Artmed; 2017.
  9. Elango K, Javaid A, Khetarpal BK, Ramalingam S, Kolandaivel KP, Gunasekaran K, et al. The effects of warfarin and direct oral anticoagulants on systemic vascular calcification: a review. Cells [Internet]. 2021; 10(4): 773. Available from: <https://doi.org/10.3390/cells10040773>
  10. Wan H, Yang Y, Zhu J, Wu S, Zhou Z, Huang B, et al. An in-vitro evaluation of direct thrombin inhibitor and factor Xa inhibitor on tissue factor-induced thrombin generation and platelet aggregation: a comparison of dabigatran and rivaroxaban. Blood Coagul Fibrinolysis [Internet]. 2016; 27(8): 882-885. Available from: <https://doi.org/10.1097/mbc.0000000000000509>
  11. Berkovits A, Mezzano D. [New oral anticoagulants: a review]. Rev Chil Cardiol [Internet]. 2017; 36(3): 254-263. Available from: <http://dx.doi.org/10.4067/S0718-85602017000300254> Spanish.
  12. Sequeira CM, Lin EL, Navarro MJ. [Overview and update of anticoagulant management in urgent and elective procedures]. Ciencia & Salud [Internet]. 2023; 7(4): 67-85. Available from: <https://doi.org/10.34192/cienciaysalud.v7i4.648> Spanish.
  13. Stanifer JW, Pokorney SD, Chertow GM, Hohnloser SH, Wojdyla DM, Garonzik S, et al. Apixaban versus warfarin in patients with atrial fibrillation and advanced chronic kidney disease. Circulation [Internet]. 2020; 141(17): 1384-1392. Available from: <https://doi.org/10.1161/circulationaha.119.044059>
  14. Chen A, Stecker E, Warden BA. Direct oral anticoagulant use: a practical guide to common clinical challenges. J Am Heart Assoc [Internet]. 2020; 9(13): e017559. Available from: <https://doi.org/10.1161/jaha.120.017559>
  15. Alcalai R, Butnaru A, Moravsky G, Yagel O, Rashad R, Ibrahimli M, et al. Apixaban vs. warfarin in patients with left ventricular thrombus: a prospective multicentre randomized clinical trial. Eur Heart J Cardiovasc Pharmacother [Internet]. 2022; 8(7): 660-667. Available from: <https://doi.org/10.1093/ehjcvp/pvab057>
  16. Kwak EJ, Nam S, Park KM, Kim SY, Huh J, Park W. Bleeding related to dental treatment in patients taking novel oral anticoagulants (NOACs): a retrospective study. Clin Oral Investig [Internet]. 2019; 23(1): 477-484. Available from: <https://doi.org/10.1007/s00784-018-2458-2>
  17. Polo-García J. [New versus classical anticoagulants: advantages and disadvantages]. Semergen [Internet]. 2013; 39(suppl. 1): 10-16. Available from: <https://www.elsevier.es/es-revista-medicina-familia-semergen-40-articulo-nuevos-anticoagulantes-frente-anticoagulantes-clasicos-S1138359313743764> Spanish.
  18. Serrano-Sánchez V, Ripollés-de Ramón J, Collado-Yurrita L, Vaello-Checa I, Colmenero-Ruiz C, Helm A, et al. New horizons in anticoagulation: Direct oral anticoagulants and their implications in oral surgery. Med Oral Patol Oral Cir Bucal [Internet]. 2017; 22(5): e601-e608. Available from: <https://pmc.ncbi.nlm.nih.gov/articles/PMC5694183/>
  19. Halaszynski TM. Administration of coagulation-altering therapy in the patient presenting for oral health and maxillofacial surgery. Oral Maxillofac Surg Clin North Am [Internet]. 2016; 28(4): 443-460. Available from: <https://doi.org/10.1016/j.coms.2016.06.005>
  20. Mariano LB, Barcellos BM, da Silveira IT, Duarte BG, Mariotto LG, Yaedú RY. [Evaluation of the need for suspension of new oral anticoagulants to perform dental extractions: systematic review]. Res Soc Dev [Internet]. 2023; 12(1): e28012139387. Available from: <https://doi.org/10.33448/rsd-v12i1.39387> Portuguese.
  21. Ockerman A, Miclotte I, Vanhaverbeke M, Vanassche T, Belmans A, Vanhove J, et al. Tranexamic acid and bleeding in patients treated with non-vitamin K oral anticoagulants undergoing dental extraction: the EXTRACT-NOAC randomized clinical trial. PLoS Med [Internet]. 2021; 18(5): e1003601. Available from: <https://doi.org/10.1371/journal.pmed.1003601>