



Gaceta Médica Boliviana
ISSN: 1012-2966
ISSN: 2227-3662
gacetamedicaboliviana@gmail.com
Universidad Mayor de San Simón
Bolivia

Sequelae of Blunt Eye Trauma, in economically active patients

Quispaya Q., Rolando; Fernandez M, Paola

Sequelae of Blunt Eye Trauma, in economically active patients

Gaceta Médica Boliviana, vol. 43, no. 1, 2020

Universidad Mayor de San Simón, Bolivia

Available in: <https://www.redalyc.org/articulo.oa?id=445674690037>

DOI: <https://doi.org/10.47993/gmb.v43i1.33>

Todos los derechos morales a los autores y todos los derechos patrimoniales a la Gaceta Médica Boliviana
Todos los derechos morales a los autores y todos los derechos patrimoniales a la Gaceta Médica Boliviana



This work is licensed under Creative Commons Attribution-ShareAlike 4.0 International.

Sequelae of Blunt Eye Trauma, in economically active patients

Secuelas de Trauma Ocular Contuso, en paciente económicamente activo

Rolando Quispaya Q. quispaya@gmail.com

Hospital Clínico Viedma y Hospital Harry Williams, Bolivia

Paola Fernandez M

Fundación Boliviana de Oftalmología, Universidad Mayor de San Simón, Bolivia

Gaceta Médica Boliviana, vol. 43, no. 1, 2020

Universidad Mayor de San Simón, Bolivia

Received: 19 March 2020

Accepted: 21 May 2020

DOI: <https://doi.org/10.47993/gmb.v43i1.33>

Redalyc: <https://www.redalyc.org/articulo.oa?id=445674690037>

Abstract: Ocular trauma is a frequent cause of consultation in ophthalmology departments and is more frequent in males. Depending on the severity of the damage caused, treatment represents a challenge for the ophthalmologist, because he is faced with an integral and complex pathological damage. The present case corresponds to a male patient with a significant decrease in visual acuity in (right in the right eye of the) the right eye, with a history of blunt ocular trauma caused by a stone in his work environment, who attended two months after the ocular trauma. On examination he presented with sequelae of the blunt eye trauma, anterior capsular fibrosis, traumatic cataract, subluxation of the crystalline lens, etc. The visual prognosis after a surgical procedure is good, however, the patient refuses surgery. Therefore, it is very important to wear work glasses that can prevent accidents at work.

Keywords: trauma, eye, fibrosis, subluxation lens.

Resumen: El trauma ocular es una causa frecuente de consulta en los servicios de oftalmología, es más frecuente en el género masculino. Dependiendo de la gravedad del daño ocasionado, el tratamiento representa un reto para el oftalmólogo, porque, se enfrenta ante un daño patológico integral y complejo. El presente caso corresponde a un paciente masculino con baja de agudeza visual importante en ojo derecho, con antecedente de trauma ocular contuso, ocasionado con una piedra, en su ambiente laboral, que acude dos meses posterior al trauma ocular. Al examen presenta secuelas del trauma ocular contuso, fibrosis capsular anterior, catarata traumática, subluxación de cristalino, etc. El pronóstico visual tras un procedimiento quirúrgico es bueno, sin embargo, el paciente rechaza la cirugía. Por lo tanto, es muy importante el uso de lentes de trabajo que puede prevenir accidentes laborales.

Palabras clave: trauma, ojo, fibrosis, subluxación de cristalino.

Ocular trauma is any injury caused by a mechanical agent on the eye, which causes tissue damage, compromising visual function ¹.

It is a frequent cause of consultation in emergency services, representing 3% of all cases, and most frequently affects people of productive age with an average age of 30.6 years, with the male sex accounting for 87% of all cases ².

According to the WHO, 90% of people with visual impairment live in low-income countries and 28% of people with moderate and severe visual impairment are of working age; these visual limitations affect the person?

s ability to lead a productive life, undermining employment possibilities. It is estimated that most cases of visual impairment are up to 80% preventable or treatable, but access to prevention, education, treatment and rehabilitation services is very limited ³.

The lack of use of personal protective equipment in motor vehicle accidents or occupational accidents speaks of the lack of regularization in this area and represents a fertile field for preventive medicine ⁴.

Case presentation

This is the case of a 26-year-old male patient, a bricklayer, who came for consultation due to a progressive decrease in visual acuity in the right eye, with a history of blunt eye trauma with a stone, two months prior to the consultation, while carrying out construction work. On ophthalmological examination he had a visual acuity of the right eye (OD) of finger count at 3 metres, left eye (OI) of 20/20. On biomicroscopic examination under mydriasis (Figure 1) in OD: folds were observed in the anterior capsule at 12:00 hrs. as a result of capsular fibrosis in situ, formed from a small rupture caused by the trauma, in addition to a traumatic cataract that is in progress from 3:00 to 6:00 hrs. The patient also has a subluxation of the crystalline lens towards the superior temporal as a result of the rupture of the Zinn's zonule in the inferior nasal area, caused by the strong contusive impact, and finally the presence of vitreous in the anterior chamber from 2:00 to 7:00 hrs. (Figure 2). OI: normal anterior segment. Fundus examination of both eyes showed no alterations.

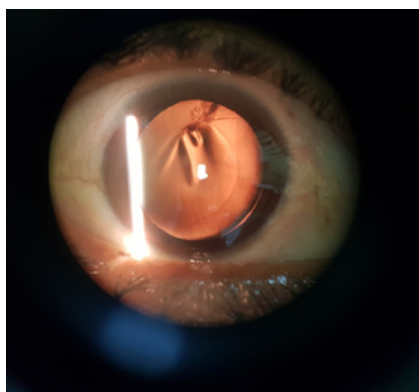


Figure 1.

Biomicroscopic examination of anterior segment under mydriasis medicamentosa.

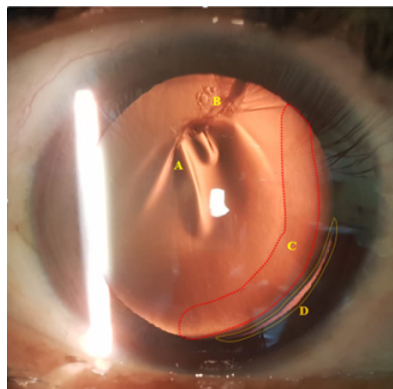


Figure 2.

Biomicroscopy by retroillumination (OD): A: folds in the anterior capsule + capsular fibrosis in situ. B: traumatic cataract in progress. C: vitreous in anterior chamber. D: lens subluxation due to Zinn's zonule rupture.

Due to the significant visual deficit, a surgical procedure consisting of cataract surgery using the phacoemulsification technique with implantation of a capsular tension ring and anterior vitrectomy was proposed. For this reason, it is recommended to wear work glasses during work activities to avoid this type of accident.

Discussion

Ocular trauma is one of the main causes of severe ocular morbidity, particularly in developing countries, and it is also a preventable disorder⁵. They can be open or closed; in the case presented, it is a closed ocular trauma. The literature indicates that one of the main complications of contusion is traumatic injury to the crystalline lens, causing traumatic cataract and/or dislocation or subluxation of the lens⁶. Cataract causes a visual impairment that slowly and progressively decreases vision; it is the leading cause of reversible blindness⁷. The treatment of traumatic cataract is performed by a surgical procedure, phacoemulsification being one of them, this is one of the safest surgical techniques with the best results, but it must be performed by trained ophthalmic surgeons with the appropriate technical conditions⁸. Cataract remains one of the leading causes of poor vision, the proportion of which is higher in low- and middle-income countries than in high-income countries. Such is the case of the patient, who, due to his economic conditions, had to refuse the indicated surgery, with which he would have a good visual prognosis⁹.

Severe ocular trauma generates a significant socio-economic impact that makes it a global health problem as a result of the high costs associated with medical management and treatment¹⁰ and when accompanied by inadequate safety measures at home, in the workplace and lack of easy access to medical specialists, it is responsible for the poor visual outcome of ocular trauma in developing countries¹¹.

It is important to establish health policies regarding eye trauma, even more so if it is clear that more than 90% of eye injuries can be prevented with basic eye care measures ¹².

We present the case of a young patient, who is in his full socioeconomic productive years, who after suffering an accident at work, does not have medical insurance, which is why he does not go for ophthalmological consultation in the first instance and hopes to improve spontaneously, which did not happen and after 2 months he is forced to make the consultation, by his own means, after noticing progressive low vision that makes it difficult for him at work and although the studies show that in his case he has a good visual prognosis, the reality is that the patient rejects the surgical indication, because he cannot access it. This is the importance of being able to prevent this type of accidents at work, with the correct use of work glasses, which are cheaper and more accessible compared to the cost of surgery.

References

1. D 1. Diagnóstico y tratamiento de Contusión Ocular y orbitaria. México: Secretaria de Salud, citado 27 de Julio de 2018. Disponible en internet: http://www.cenetec.salud.gob.mx/descargas/gpc/CatalogoMaestro/436_GPC_Contusixn_ocular_y_orbitaria/GER_Contusixn_ocular_y_orbitaria.pdf [Links]
2. Sanchez R, Pivcevic D, Leon A, Ojeda M. Trauma ocular. Cuadernos de Cirugia [Internet].2008. 22(1):91-97. Disponible en: <http://revistas.uach.cl/html/cuadcir/v22n1/body/art13.html>
3. OMS Organización Mundial de la Salud. Ceguera y discapacidad. Nota descriptiva, Octubre de 2017. Disponible en: <https://www.who.int/es/news-room/fact-sheets/detail/blindness-and-visual-impairment>
4. Puoucell Ferraez JL, Perdomo Martinez R. Epidemiological characteristics of ocular trauma, classified according to the ocular trauma score. Rev Med UAS [Internet].2019. 9(3):143-150. Disponible en: <http://hospital.uas.edu.mx/revmeduas/articulos/v9/n3/traumaocular.pdf>
5. Chen Chen Z, Li SM. Trauma of the globe: State of art in global and in China. Chin J Traumatol [Internet]. 2016;19(6):317-8. Disponible en: <https://www.sciencedirect.com/science/article/pii/S1008127516303662>
6. American Academic of Ophthalmology. Lens and Cataract. Volumen 11. San Francisco: European Board of Ophthalmology; 2018-2019. Pág. 50-51
7. Mijenes O, Martínez S, Aguilar V, Rodríguez Y, Santos S, Sanjurjo J. Factores de riesgo ocular y experiencia del cirujano en las complicaciones de la cirugía de catarata. Revista Cubana de Oftalmología. 2014; 27(2): 203-211. Disponible en: <https://www.medigraphic.com/cgi-bin/new/resumen.cgi?IDARTICULO=57080>
8. Welch Welch G, Cruz M, Escalona M, Fundora V. Facoemulsificación en la cirugía de catarata. Revista Cubana de Medicina Militar. 2017; 46(3): 244-255. Disponible en: http://scielo.sld.cu/scielo.php?script=sci_arttext&pid=S0138-65572017000300005

9. Organización Organización Mundial de la Salud. Ceguera y discapacidad visual. [Internet]; 2018. Disponible en: <https://www.who.int/es/newsroom/fact-sheets/detail/blindness-and-visual-impairment>.
10. Diazgranados F J, Anaya D, Arias D, Pinto I, Solano A, Carvajal R. Trauma Ocular Abierto en el Hospital de San José. *Visión Pan-American* [Internet]. 2018 [citado 20 Feb 2019];17(2):79-83.
11. C. Girkin, G. McGwin Jr, R. Morris, F. Kuhn Glaucoma following penetrating ocular trauma: A cohort study of the United States Eye Injury Registry. *American Journal of Ophthalmology*. 2004;139(1):100-5. Disponible en: [https://www.ajo.com/article/S0002-9394\(04\)01037-2/abstract](https://www.ajo.com/article/S0002-9394(04)01037-2/abstract)
12. Ministerio de Salud. Guía Clínica Trauma ocular grave. Santiago: Minsal, 2007. Pag.1-37. Disponible en: <http://www.bibliotecaminsal.cl/wp/wp-content/uploads/2016/04/Trauma-Ocular-Grave.pdf>

Alternative link

http://www.scielo.org.bo/scielo.php?script=sci_arttext&pid=S1012-29662020000100018&lng=es&nrm=iso
(html)