



Semina: Ciências Agrárias

ISSN: 1676-546X

ISSN: 1679-0359

Universidade Estadual de Londrina

Góss, Geórgia Camargo; Duarte, Claudia Acosta; Mozzaquatro, Fabricio
Desconsi; Döwich, Gabriela; Klaus, Gustavo; Altermann, Othon; Severo,
Eduarda Sacardi; Nunes, Onildo Gonçalves; Bataglin, Caroline Frizzo
Ultrasonographic measurement of collateral ligaments of the distal interphalangeal joint in Criollo horses
Semina: Ciências Agrárias, vol. 39, no. 6, 2018, November-December, pp. 2867-2874
Universidade Estadual de Londrina

DOI: <https://doi.org/10.5433/1679-0359.2018v39n6p2867>

Available in: <https://www.redalyc.org/articulo.oa?id=445759861045>

- How to cite
- Complete issue
- More information about this article
- Journal's webpage in redalyc.org

UAEM
redalyc.org

Scientific Information System Redalyc
Network of Scientific Journals from Latin America and the Caribbean, Spain and
Portugal

Project academic non-profit, developed under the open access initiative

Ultrasonographic measurement of collateral ligaments of the distal interphalangeal joint in Criollo horses

Mensuração ultrassonográfica dos ligamentos colaterais da articulação interfalangeana distal de equinos da raça Crioula

Geórgia Camargo Góss^{1*}; Claudia Acosta Duarte²; Fabricio Desconsi Mozzaquatro²; Gabriela Döwich³; Gustavo Klaus⁴; Othon Altermann⁴; Eduarda Sacardi Severo⁴; Onildo Gonçalves Nunes Junior⁴; Caroline Frizzo Bataglin⁴

Abstract

Criollo horses were used in the past only for field services, especially countryside work. However, currently, they have been used as sports animals in several modalities involving turns in legs and exercises on irregular terrain, predisposing them to injuries in the distal extremity. Among the alterations recognized as cause of lameness in this region are the conditions related to collateral ligaments of the distal interphalangeal joint (CL-DIPJ), which in horses are structures that help to maintain joint stability and suffer a high pressure due to the high body weight, especially when it is not equally distributed at the stance phase. Considering the importance of the ultrasound anatomical knowledge of this structure for the early diagnosis of locomotive affections in the digit of Criollo horses, this study aimed to standardize CL-DIPJ measurements in healthy horses of this breed. We used 25 adult Criollo horses not submitted to sports practice. For ultrasonographic evaluation, after a trichotomy of the region, an ultrasound Chison 8300VET and a 6.0 MHz linear probe were used with a standoff pad. This technique uses a cross-sectional view, in which CL-DIPJ is visualized in the distal concavity portion of the middle phalanx, being a standard for the measurements. For ligament measurements, the variables dorsopalmar diameter (DPD), latero-medial diameter (LMD), and cross-sectional area (CSA) of ligaments were used. Three measurements were performed for each variable and average values were obtained, which were compared to each other and did not present significant differences ($p > 0.05$). The average measurements of diameter and area of collateral ligaments of the distal interphalangeal joint in Criollo horses were 9.04 mm for DPD, 7.55 mm for LMD, and 0.52 mm² for CSA. This was the first study that standardized the size of this structure in this breed.

Key words: Collateral ligament. Distal interphalangeal joint. Equine. Measures. Criollo.

¹ Discente de Mestrado, Programa de Pós-Graduação em Ciência Animal, Universidade Federal do Pampa, UNIPAMPA, Uругuaiana, RS, Brasil. E-mail: georgia_goss@hotmail.com

² Profs., Curso de Graduação em Medicina Veterinária, UNIPAMPA, Uругuaiana, RS, Brasil. E-mail: caduarte74@gmail.com; fmozzaquatro@yahoo.com.br

³ Residente em Medicina Veterinária, UNIPAMPA, Uругuaiana, RS, Brasil. E-mail: gabrieladowich@hotmail.com

⁴ Discentes, Curso de Medicina Veterinária, UNIPAMPA, Uругuaiana, RS, Brasil. E-mail: othon_altermann@hotmail.com; eduardasacardi@hotmail.com; carolinefrizzob@hotmail.com; nunesonildo@hotmail.com; gklaus990@gmail.com

* Author for correspondence

Resumo

Os cavalos da raça Crioula eram utilizados apenas para serviços de campo, especialmente no trabalho com o gado. No entanto, atualmente, são utilizados também como animais de esporte em diversas modalidades que envolvem paleteadas, movimentos de giros apoiados sobre os membros pélvicos e exercícios em terrenos irregulares, predispondo-os às lesões na região distal dos dígitos. Dentre as alterações reconhecidas como causa de claudicação nesta região, encontram-se as afecções vinculadas aos ligamentos colaterais da articulação interfalangeana distal (LC-AID), que são estruturas que auxiliam a manter a estabilidade articular e sofrem alta tensão, devido ao elevado peso corporal, especialmente quando não estão igualmente distribuídos no momento de apoio do casco no solo. Tendo em vista a importância do conhecimento anatômico ultrassonográfico dessa estrutura para o diagnóstico precoce de afecções locomotoras no dígito de cavalos Crioulos, o objetivo deste trabalho foi padronizar as medidas dos LC-AID em equinos hípidos desta raça. Foram utilizados 25 equinos Crioulos adultos não submetidos à prática esportiva. Para a avaliação ultrassonográfica, após tricotomia da região, foi utilizado o aparelho Chison 8300VET e probe linear de 6,0MHz com auxílio de standoff pad e, a técnica empregada utilizou um corte transversal, no qual o LC-AID é visualizado na concavidade da porção distal da falange média, como padrão para a obtenção das medidas. Para mensuração dos ligamentos, utilizaram-se três variáveis denominadas diâmetro dorso palmar (DDP), diâmetro latero medial (DLM) e área transversal do ligamento (ATL). Realizaram-se três medições para cada uma das variáveis e, a partir destas medidas, obtiveram-se os valores de média, os quais foram comparados entre si e não apresentaram diferenças significativas ($p > 0,05$). Concluiu-se que as médias das medidas de diâmetro e área dos ligamentos colaterais da articulação interfalangeana distal em equinos da raça Crioula foram de 9,04mm para o DDP, 7,55mm para o DLM e 0,52mm² para a ATL, sendo o primeiro trabalho que padronizou o tamanho desta estrutura na raça.

Palavras-chave: Ligamento colateral. Articulação interfalangeana distal. Equino. Medidas. Crioulo.

Criollo is a medium-sized horse, very balanced, agile, fast in its movements, and with good abilities with cattle. Such characteristics made this species be chosen for field works in southern Brazil, Uruguay, and Argentina (VIDART, 2004). With breed evolution, these animals have also been destined to sports practice, standing out the competition *Freio de Ouro* (ABCCC, 2017). The exercises to which the Criollo horses are submitted predispose them to lesions in the distal portion of the digit, being this region a frequent place of origin of locomotor system disorders, leading to lameness in about 68.6% of the animals studied by Abreu et al. (2011). In addition, changes in CL-DIPJ have been increasingly related to the cause of lameness (DYSON et al., 2004).

Desmopathies involving CL-DIPJ are usually presented as acute lameness from scores 1 to 4 out of 5, with no painful response to hoof sensitivity test (MCDIARMID, 1998). Lameness presents improvement after perineural blocking of the palmar digital nerve in the abaxial sesamoid region

(TROPE; WHITTON, 2009) and is characterized by being refractory to treatment with intra-articular corticosteroids (TURNER; SAGE, 2002; ZUBROD et al., 2005). Affected animals may show tumefaction in the ligament region and/or distention of the distal interphalangeal joint capsule (DYSON et al., 2004).

Exercises that involve stops and turns, especially on irregular terrains, angular deformities, and hoof imbalances are the main factors that predispose animals to the development of this disease (ZUBROD et al., 2005). Its diagnosis is adequately performed by means of ultrasonography (MITCHELL, 2013).

Considering this scenario, the knowledge of physiological measurements of this ligament in Criollo horses can help in the early diagnosis and prognosis of lesions in this structure. Therefore, the aim of this study was to standardize, by ultrasonography, CL-DIPJ measurements in healthy Criollo horses not submitted to athletic training.

This research was approved by the Ethics Committee on Animal Use (CEUA) of the Federal University of Pampa (UNIPAMPA) under the protocol No. 027/2017.

Twenty-five adult Criollo horses, four of them castrated males and the other 21 non-pregnant females, were used in the experiment. Animals had a good body condition and an average age of 4.5 years (standard deviation of 1.26), an average weight of 392 kg (standard deviation of 34.9), with a maximum weight of 450 kg and a minimum weight of 325 kg, and an average height of 1.42 m (standard deviation of 0.04). All the animals were from the same farm of Uruguaiana, RS, Brazil, being used to work with cattle. No animal had undergone athletic training nor had a history of lameness originating in the distal portion of the digit. Moreover, no animal was regularly shod nor trimmed, thus presenting irregular and expanded hooves. The same evaluator performed a general and specific clinical evaluation of the locomotor system systematically and only animals without clinical changes and lameness were selected for the experiment.

After washing with soap and water, trichotomy was performed on the dorsolateral and dorsomedial faces of both thoracic limbs, extending approximately three centimeters above the coronary band. Ultrasonographic evaluation of lateral and medial collateral ligaments of the distal interphalangeal joint was performed by the same evaluator only in the thoracic limbs since CL-DIPJ of pelvic limbs are rarely affected (TROPE; WHITTON, 2009). An ultrasound Chison 8300VET, with a linear probe and a standoff pad, was used with a frequency of 6.0 MHz. Animals were kept in a quadrupedal position, resting on the studied thoracic limb. Due to the docile temperament of the horses, there was no need to sedate or contain them in handling chutes.

The ultrasonographic technique used in this study was recommended by Denoix et al. (2011), with the ultrasonographic cut-off in position A, in which CL-DIPJ is observed in the distal concavity

of the middle phalanx. We measured the four CL-DIPJ of the thoracic limbs of each animal. For this, after animal preparation and probe positioning, three images of each studied ligament were captured. Measurements were performed in each of the images by means of the ultrasound equipment, which also allowed obtaining the values of CL-DIPJ area. With the three measurement values, the average of each variable was calculated. The sites for performing the measurements followed the recommendations of Contreras (2009) and the studied variables were named as the dorsopalmar diameter (DPD), latero-medial diameter (LMD), and cross-sectional area (CSA) of ligaments, which are shown in Figure 1.

The values of lateral CL-DIPJ between left (LTL) and right thoracic limbs (RTL), medial CL-DIPJ between LTL and RTL, and between lateral and medial CL-DIPJ were compared regardless of the studied thoracic limb. For this, the t-test was used at 5% error probability.

Although in the literature we have found other studies that used the same ultrasonographic technique used in our study and with measures for this structure, the measurements were carried out in different breeds, such as quarter horses (TURNER; SAGE, 2002; RIBEIRO, 2016), purebred Arabian horses, paint horses (TURNER; SAGE, 2002), and purebred Chilean horses (CONTRERAS, 2009). Thus, there were no standardizing of CL-DIPJ measurements in Criollo horses.

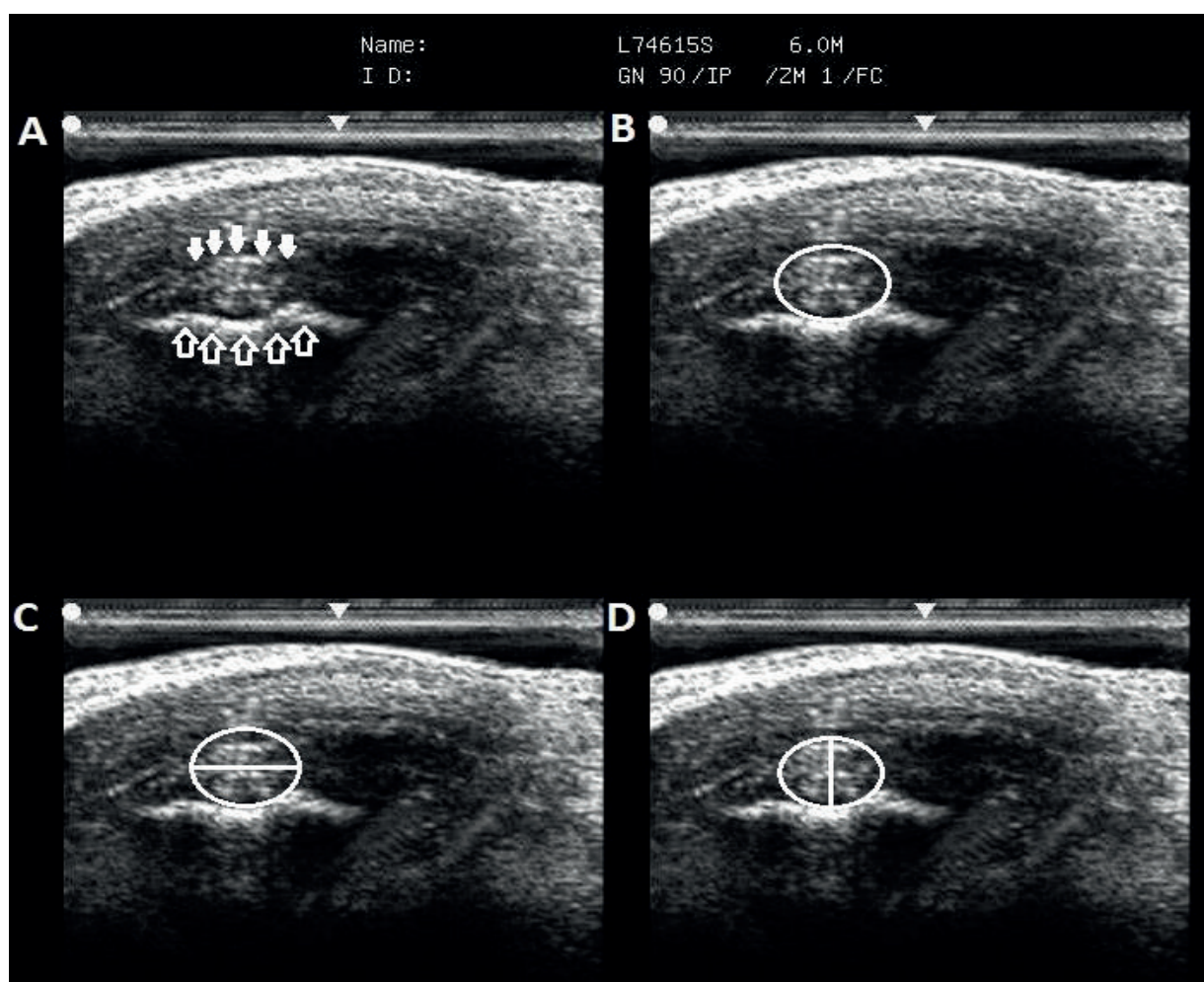
The choice of this technique and position A, as recommended by Denoix et al. (2011), for CL-DIPJ measurements allowed measuring the studied ligaments in a satisfactory, fast, and relatively easy way. Moreover, due to the irregularity of shoeing and trimming, animals presented expanded hooves, which makes it relatively easier to see the studied structures, as described by Ribeiro (2016).

The evaluator had a greater difficulty in obtaining images of the medial collateral ligaments (MCL), which was also reported by Whitcomb (2009) and Ribeiro (2016). In addition, although all the animals

have presented hooves with similar characteristics, we observed slight variations in CL-DIPJ shapes, with some ligaments being flatter or more rounded and varying between individuals and between the lateral collateral ligaments (LCL) and MCL of the same individual. Denoix et al. (2011) and Ribeiro (2016) also described similar results. This

characteristic did not cause a great complication to carry out the measurements, but it reinforces the fact that individuals have variations between each other and that an individual evaluation must be carried out carefully, respecting the characteristics of each animal.

Figure 1. Ultrasonographic images demonstrating the sites where CL-DIPJ measurements were carried out. A) Standard image used in this study. Note that CL-DIPJ is presented as an oval and echogenic structure (filled white arrows) located in the concavity of the distal edge of the second phalanx (non-filled white arrows). B) Ligament area (white circle). C) Dorso-palmar diameter (horizontal white line). D) Latero-medial diameter (vertical white line).



In both thoracic limbs, the probe was positioned dorsolaterally and dorsomedially on the coronary band, as described by Turner and Sage (2002)

and Evrard et al. (2012). This structure served as a window and allowed finding the concavity of the distal edge of the middle phalanx and using

it as a reference point in the chosen position, as described by Denoix et al. (2011) and Turner and Sage (2002). Although CL-DIPJ has particular characteristics regarding their echogenicity during the ultrasonographic evaluation due to the variation in the direction of its ligament fibers along the length (DENOIX et al., 2011; EVRARD et al., 2012), the positioning allowed visualizing the ligament with echogenic characteristics without major difficulties. Moreover, in cases where an anisotropy was observed in position A, a slight adjustment in the probe angulation by the evaluator was sufficient to undo this effect.

The use of a linear probe at a frequency of 7.5 MHz is indicated for CL-DIPJ evaluation, especially

to observe changes in echogenicity (DYSON et al., 2004; DENOIX et al., 2011). However, using a frequency of 6 MHz, although the loss of image quality to evaluate fiber echogenicity, we observed a better delimitation of this structure, avoiding a possible erroneous evaluation of CL-DIPJ size.

The average values found for MCL and LCL of the left and right thoracic limbs are shown in Table 1. These values were compared to each other and no statistically significant difference was observed between the MCL of the right and left thoracic limbs ($p>0.05$). The same result was obtained when LCL values of both limbs were compared to each other ($p>0.05$).

Table 1. Averages of the three variables related to the size of LCL and MCL of the left and right thoracic limbs of Criollo horses not submitted to sports activities.

Measure	Medial collateral ligament		Lateral collateral ligament	
	LTL ¹	RTL ²	LTL ¹	RTL ²
DPD ³	9.93±0.27 mm	10.04±0.20 mm	9.48±0.18 mm	9.22±0.21 mm
LMD ⁴	7.13±0.13 mm	6.97±0.1 mm	6.8±0.14 mm	6.8±0.17 mm
CSA ⁵	0.55±0.009 cm ²	0.54±0.01 cm ²	0.51±0.012 cm ²	0.49±0.01 cm ²

* The comparison between column values did not present significant differences ($p>0.05$).

* ¹Left thoracic limb; ²Right thoracic limb; ³Dorso-palmar diameter; ⁴Latero-medial diameter; ⁵Cross-sectional area of the ligament.

When LCL and MCL were compared, regardless of the studied thoracic limb, the average values of DPD, LMD, and CSA were, respectively, 9.63±0.15 mm, 6.88±0.1 mm, and 0.52±0.009 cm² for LCL and 9.71±0.14 mm, 6.99±0.1 mm, and 0.53±0.008 cm² for MCL. Although the averages of MCL were higher when compared to LCL, no significant difference was observed between them ($p>0.05$). This result is in accordance with Contreras (2009) and Ribeiro (2016).

Considering that there was no statistical difference between lateral and medial ligaments, the average size of CL-DIPJ in Criollo horses was 9.67 mm for DPD, 6.94 mm for LMD, and 0.52 cm² for CSA. In fact, domestic animals are anatomically divided into antimeres, which would justify the

absence of large bilateral asymmetries in individuals (DIDIO, 1981).

The average values of ATL (0.52 cm²) differed from the values found by Denoix et al. (2011), Turner and Sage (2002), and Ribeiro (2016), who used horses submitted to physical exercises and found values ranging from 0.6 to 0.9 cm² in horses weighing 550 kg, 0.61 to 0.65 cm² in Arabian, quarter, and paint horses, and 0.77±0.17 cm² in quarter horses with an average weight of 450 kg. Contreras (2009) described measures with an area similar to those found in our study in purebred Chilean horses submitted to sports training, with values between 0.55 and 0.61 cm². This similarity in measures may have a relation with the origin and conformation of the purebred Chilean horses,

which resemble those observed in Criollo horses (GAJARDO, 2009).

Regarding diameter measurements, we obtained averages of 9.67 mm for DPD and 6.94 mm for LMD. These values of LMD are similar to those found by Denoix et al. (2011), who observed values of 6-9 mm. However, they were higher than the values of 5.4-5.9 mm found by Contreras (2009). For DPD, the values found in our study were lower when compared to those observed by Contreras (2009), Denoix et al. (2011), and Ribeiro (2016), with values of 12.7-13 mm, 12-16 mm, and 11.7±1.4 mm, respectively.

Although the similarity between LMD values obtained here and in other studies, a marked difference was observed when the variables CSA and DPD were observed, with values for Criollo animals lower than those found for other breeds were. Turner and Sage (2002), Denoix et al. (2011), and Ribeiro (2016) evaluated animals with a minimum weight of 450 kg, while in this study, horses had a maximum weight of 450 kg, which could be considered as smaller animals. Although the comparison between our study and the existing literature is valid, it is very important that more studies be carried out in order to prove the relationship between body size of animals and ligament size.

The average measurements of diameter and area of collateral ligaments of the distal interphalangeal joint in Criollo horses were 9.67 mm for DPD, 6.94 mm for LMD, and 0.52 cm² for CSA.

Although the description of measurements of collateral ligaments of the distal interphalangeal joint in equines is found in the literature, this was the first study that standardized the size of this structure in Criollo horses.

Acknowledgments

To the veterinarian Marcelo Teixeira Napoleão and the Estância Itapitocai for making available the animals used in this study.

References

- ABREU, H. C.; De La CORTE, F. D.; BRASS, K. E.; POMPERMAYER, E.; LUZ, T. R. R. da; GASPERI, D. de. Claudicação em cavalos Crioulos atletas. *Ciência Rural*, Santa Maria, v. 41, n. 12, p. 2114-2119, 2011.
- ASSOCIAÇÃO BRASILEIRA DE CRIADORES DE CAVALO CRIOULO - ABCCC. O cavalo crioulo. Porto Alegre: Hostche Interatividade Digital, 2017.
- CONTRERAS, R. A. C. *Caracterización ecotomográfica de los ligamentos colaterales de la articulación interfalángica distal en el equino puro sangre chileno*. 2009. Monografía (Trabajo de Conclusión de Curso en Medicina Veterinaria) - Universidad de Chile, Santiago.
- DENOIX, J. M.; BERTONI, L.; HEITZMANN, A. G.; WERP, N.; AUDIGIÉ, F. Ultrasonographic examination of the collateral ligaments of the distal interphalangeal joint in horses: Part A: technique and normal images. *Equine Veterinary Education*, Fordham, v. 23, n. 11, p. 574-580, 2011.
- DIDIO, S. J. A. Variação anatômica. In: Sisson, S.; Grossman, J. D. *Anatomia dos animais domésticos*. 5. ed. São Paulo: Interamericana, 1981. v. 1, p. 268-272.
- DYSON, S. J.; MURRAY, R.; SCHRAMME, M.; BRANCH, M. Collateral desmitis of the distal interphalangeal joint in 18 horses (2001-2002). *Equine Veterinary Journal*, Fordham, v. 36, n. 2, p. 160-166, 2004.
- EVARD, L.; BOLEN, G.; MAQUET, N.; BUSONI, V. Ultrasonography of the collateral ligaments of the distal interphalangeal joint: technique and reference images. *Journal of Equine Veterinary Science*, Amsterdam, v. 32, n. 9, p. 584-589, 2012.
- GAJARDO, A. M. Caballos en américa; Sello racial del caballo chileno. In: _____. *Historia del rodeo chileno*. Santiago: [s.n.], 2009. Cap. 2, v. 1, p. 28-32.
- McDIARMID, A. C. Distal interphalangeal joint lameness in a horse associated with damage to the insertion of the lateral collateral ligament. *Equine Veterinary Education*, Fordham, v. 10, n. 3, p. 114-118, 1998.
- MITCHELL, R. D. Distal limb lameness in the sport horse: a clinical approach to diagnosis. In: AAEP ANNUAL CONVENTION, 59., 2013, Nashville. *Proceedings...* Nashville: AAEP, 2013. p. 244-259.
- RIBEIRO, G. H. C. *Avaliação ultrassonográfica dos ligamentos colaterais da articulação interfalangeana distal do membro torácico em equinos quarto de milha*. 2016. Dissertação (Mestrado em Ciência Animal) - Universidade Federal de Goiás. Goiânia.

TROPE, G. D.; WHITTON, R. C. Medial collateral ligament desmitis of the distal interphalangeal joint in the hindlimb of a horse: treatment with cast immobilisation. *Australian Veterinary Journal*, Queensland, v. 87, n. 12, p. 499-502, 2009.

TURNER, T. A.; SAGE, A. M. Desmitis of the distal interphalangeal collateral ligaments: 22 cases. In: AAEP ANNUAL CONVENTION, 48., 2002, Orlando. *Proceedings...* Orlando: AAEP, 2002. p. 343-346.

VIDART, D. Orígenes del caballo criollo. In: LEÓN, L. P.; SAN MARTÍN, A. Z. *Criollos de America*. Montevideo: Ponce de León y Zorrilla, 2004. p. 15-26.

WHITCOMB, M. B. Ultrasonographic evaluation of the distal extremity. *Journal of Equine Veterinary Science*, Amsterdam, v. 29, n. 1, p. 47-59, 2009.

ZUBROD, C. J.; FARNSWORTH, K. D.; TUCKER, R. L.; RAGLE, C. A. Injury of the collateral ligaments of the distal interphalangeal joint diagnosed by magnetic resonance. *Veterinary Radiology & Ultrasound*, Harrisburg, v. 46, n. 1, p. 11-16, 2005.

