



Autopsy and Case Reports

ISSN: 2236-1960

Hospital Universitário da Universidade de São Paulo

Rodríguez, Angela De La Hoz; Martino, Marcello
Di; Mazeyra, Mariel Valdivia; Martín-Pérez, Elena
Solitary fibrous tumor of the pancreas
Autopsy and Case Reports, vol. 11, e2021245, 2021
Hospital Universitário da Universidade de São Paulo

DOI: <https://doi.org/10.4322/acr.2021.245>

Available in: <https://www.redalyc.org/articulo.oa?id=576067146049>

- How to cite
- Complete issue
- More information about this article
- Journal's webpage in [redalyc.org](https://www.redalyc.org)

The Redalyc logo consists of the word "redalyc" in a lowercase sans-serif font, with a red stylized graphic element resembling a lowercase 'r' or a flame to its right.

Scientific Information System Redalyc
Network of Scientific Journals from Latin America and the Caribbean, Spain and
Portugal

Project academic non-profit, developed under the open access initiative

Solitary fibrous tumor of the pancreas

Angela De La Hoz Rodríguez¹ , Marcello Di Martino¹ ,
Mariel Valdivia Mazeyra², Elena Martín-Pérez¹ 

How to cite: Rodríguez ADLH, Martino MD, Mazeyra MV, Martín-Pérez E. Solitary fibrous tumor of the pancreas. Autops Case Rep [Internet]. 2021;11:e2021245. <https://doi.org/10.4322/acr.2021.245>

Keywords

General Surgery; Pancreas; Solitary Fibrous Tumors

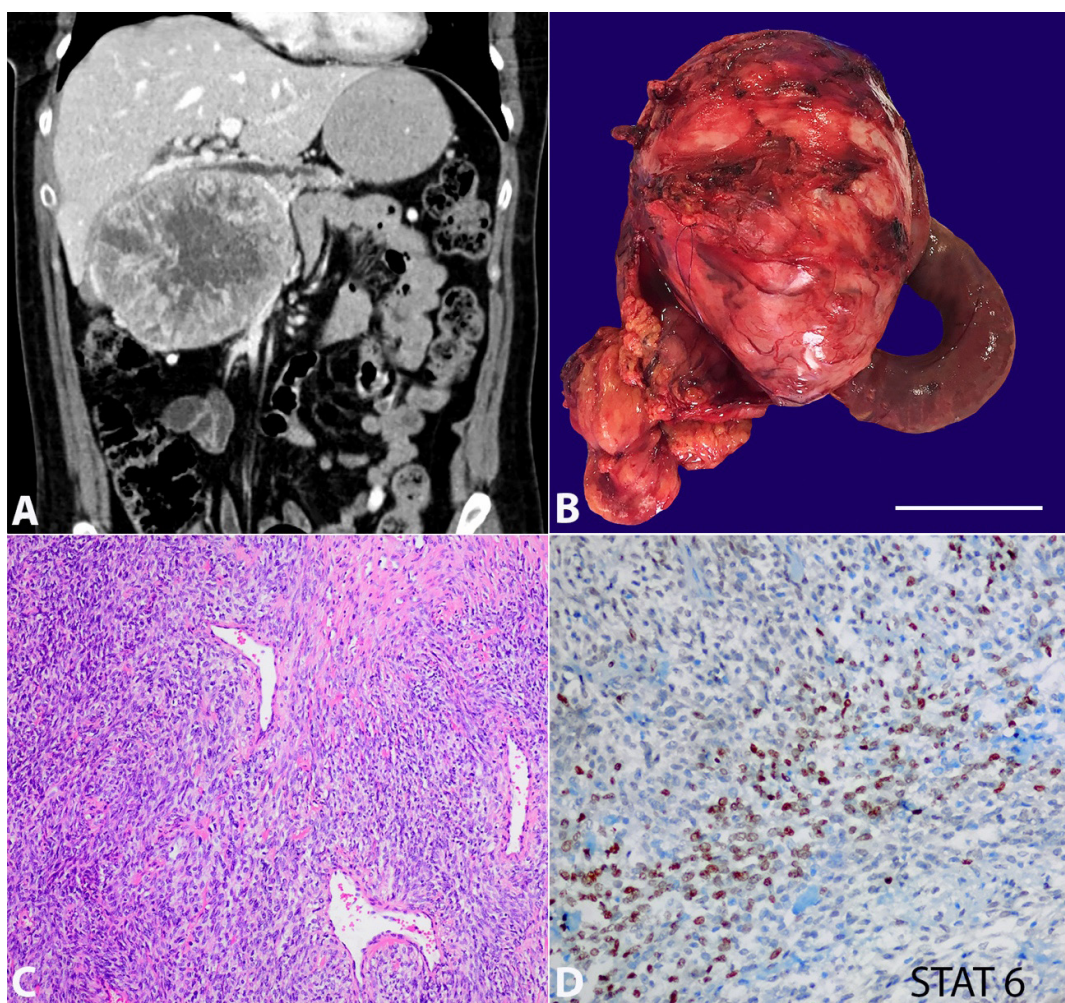


Figure 1. **A** – Abdominal computed tomography showing a well-circumscribed 13 x 10 x 9.5 cm mass in the head of the pancreas, portal vein displacement, and pancreatic main duct dilatation; **B** – Surgical specimen of total pancreatectomy and external surface of the tumor (scale bar: 7 cm); **C** – Hemangiopericytoma-like branching vascular pattern, with stromal collagen fibers surrounded by blood vessels with a “deer horn” stromal pattern (H&E, 10x); **D** – Immunostaining for STAT-6.

¹ Hospital Universitario de la Princesa, General Surgery Department. Madrid, Spain

² Hospital Universitario de la Princesa, Pathology Department. Madrid, Spain

Solitary fibrous tumors (SFT) are mesenchymal tumors with a haemangiopericytoma-like branching vascular pattern, which usually presents as a well-circumscribed mass. The majority of these tumors have been reported in the pleura.¹ The pancreas is an unusual location for this tumor, with less than 20 cases described in the literature. The differential diagnosis of pancreatic SFTs includes several spindle cell neoplasms such as GIST, leiomyosarcoma, schwannoma, and fibromyxoid sarcoma.² However, the definitive diagnosis of SFT can only be provided by the histological examination with the immunohistochemical analysis. Particularly, the growth pattern and the positivity for STAT-6 and CD 34 are helpful in differentiating SFTs from other mesenchymal tumors.³ There are scarce data about the biological behavior of SFT. Malignancy criteria include tumor size (>10 cm), infiltrative margins, high cellularity, nuclear pleomorphism, tumor necrosis and increased mitotic index (≥ 10 mitotic figures per 10 high powered fields).⁴ Therefore, complete surgical excision is the gold standard treatment and close follow-up is highly recommended since the prognosis of this tumor is uncertain.

Figure 1 refers to the imaging documentation of a 48-year-old woman with a history of orbital exenteration and maxillectomy for a synovial sarcoma ten years before. She was referred to the Hepatobiliary Surgical Clinic with mild abdominal pain and an abdominal mass in physical examination. The abdominal computed tomography scan (CT) showed a well-defined hypervascular pancreatic mass of 13 x 10 x 9.5 cm without evidence of distant metastasis. The mass caused portal vein (PV) displacement in a 6 cm segment and dilatation of the main pancreatic duct in the absence of pancreatic tail parenchyma atrophy

(Figure 1A). Surgical intervention was scheduled. Total pancreatectomy with PV resection and end-to-end reconstruction with a left renal vein graft was performed (Figure 1B). The pathological analysis revealed a solitary fibrous tumor (SFT) with fusiform fibroblastic cells, scarce cytoplasm and no nuclear atypia. The lesion presented a hemangiopericytoma-like branching vascular pattern, with stromal collagen fibers surrounded by blood vessels with a “deer horn” stromal pattern (Figure 1C). Immunohistochemically, the tumor cells were positive for STAT-6: a sensitive and specific marker for solitary fibrous tumor (Figure 1D). All lymph nodes received in the specimen were negative. The postoperative course was uneventful, and the patient was discharged on the 12th postoperative day. Chemo - radiotherapy was not necessary. No tumor recurrence was found in one year of follow-up.

REFERENCES

1. Han HS, Baek HY, Han SY, et al. Solitary fibrous tumor of the pancreas: A case report and review of the literature. *Korean J Med*. 2015;88(3):293-8. <http://dx.doi.org/10.3904/kjm.2015.88.3.293>.
2. Spasevska L, Janevska V, Janevski V, Noveska B, Zhivadinovik J. Solitary fibrous tumor of the pancreas: a case report and review of the literature. *Pril*. 2016;37(2-3):115-20. <http://dx.doi.org/10.1515/prilozi-2016-0024>. PMID:27883325.
3. Paramythiotis D, Kofina K, Bangeas P, Tsiompanou F, Karayannopoulou G, Basdanis G. Solitary fibrous tumor of the pancreas: case report and review of the literature. *World J Gastrointest Surg*. 2016;8(6):461-6. <http://dx.doi.org/10.4240/wjgs.v8.i6.461>. PMID:27358679.
4. Gold JS, Antonescu CR, Hajdu C, et al. Clinicopathologic correlates of solitary fibrous tumors. *Cancer*. 2002;94(4):1057-68. <http://dx.doi.org/10.1002/cncr.10328>. PMID:11920476.

This study was carried out at the Hospital de la Princesa, Madrid, Spain.

Authors' contributions: The manuscript was produced, reviewed, and approved by all of the authors collectively. De la Hoz Rodríguez A wrote the manuscript under the supervision and guidance of Di Martino M, Valdivia Mazeyra M and Martín-Pérez E. Martín Pérez E performed the surgical intervention. Valdivia Mazeyra M assisted the biopsy proceedings.

Ethics statement: The authors retain informed consent signed by the patient, authorizing the data publication.

Conflict of interest: The authors declared no conflict of interest.

Financial support: The authors declare that no financial support was received.

Submitted on: November 1st, 2020.

Accepted: November 27th, 2020.

Correspondence

Ángela de la Hoz Rodríguez

General Surgery Department. Hospital Universitario de La Princesa

Calle Diego de León 62, Postal Code 28006, Madrid, Spain

Phone: +34915202200

angelahoz90@gmail.com