



Autopsy and Case Reports

ISSN: 2236-1960

Hospital Universitário da Universidade de São Paulo

Pessoa-Gonçalves, Yago Marcos; Silva, Ana Clara Vaz e; Oliveira,
Carlo José Freire; Adad, Sheila Jorge; Guimarães, Lucinda Calheiros
Primary spontaneous pneumothorax

Autopsy and Case Reports, vol. 14, e2023468, 2024
Hospital Universitário da Universidade de São Paulo

DOI: <https://doi.org/10.4322/acr.2023.468>

Available in: <https://www.redalyc.org/articulo.oa?id=576077572001>

- ▶ [How to cite](#)
- ▶ [Complete issue](#)
- ▶ [More information about this article](#)
- ▶ [Journal's webpage in redalyc.org](#)

The Redalyc logo consists of the word 'redalyc.org' in a stylized font, with a red dot above the 'i' in 'org'.

Scientific Information System Redalyc

Network of Scientific Journals from Latin America and the Caribbean, Spain and
Portugal

Project academic non-profit, developed under the open access initiative

Primary spontaneous pneumothorax

Yago Marcos Pessoa-Gonçalves¹ , Ana Clara Vaz e Silva¹ ,
Carlo José Freire Oliveira¹ , Sheila Jorge Adad² ,
Lucinda Calheiros Guimarães² 

How to cite: Pessoa-Gonçalves YM, Silva ACV, Oliveira CJF, Adad SJ, Guimarães LC. Primary spontaneous pneumothorax. *Autops Case Rep* [Internet]. 2024;14:e2023468. <https://doi.org/10.4322/acr.2023.468>

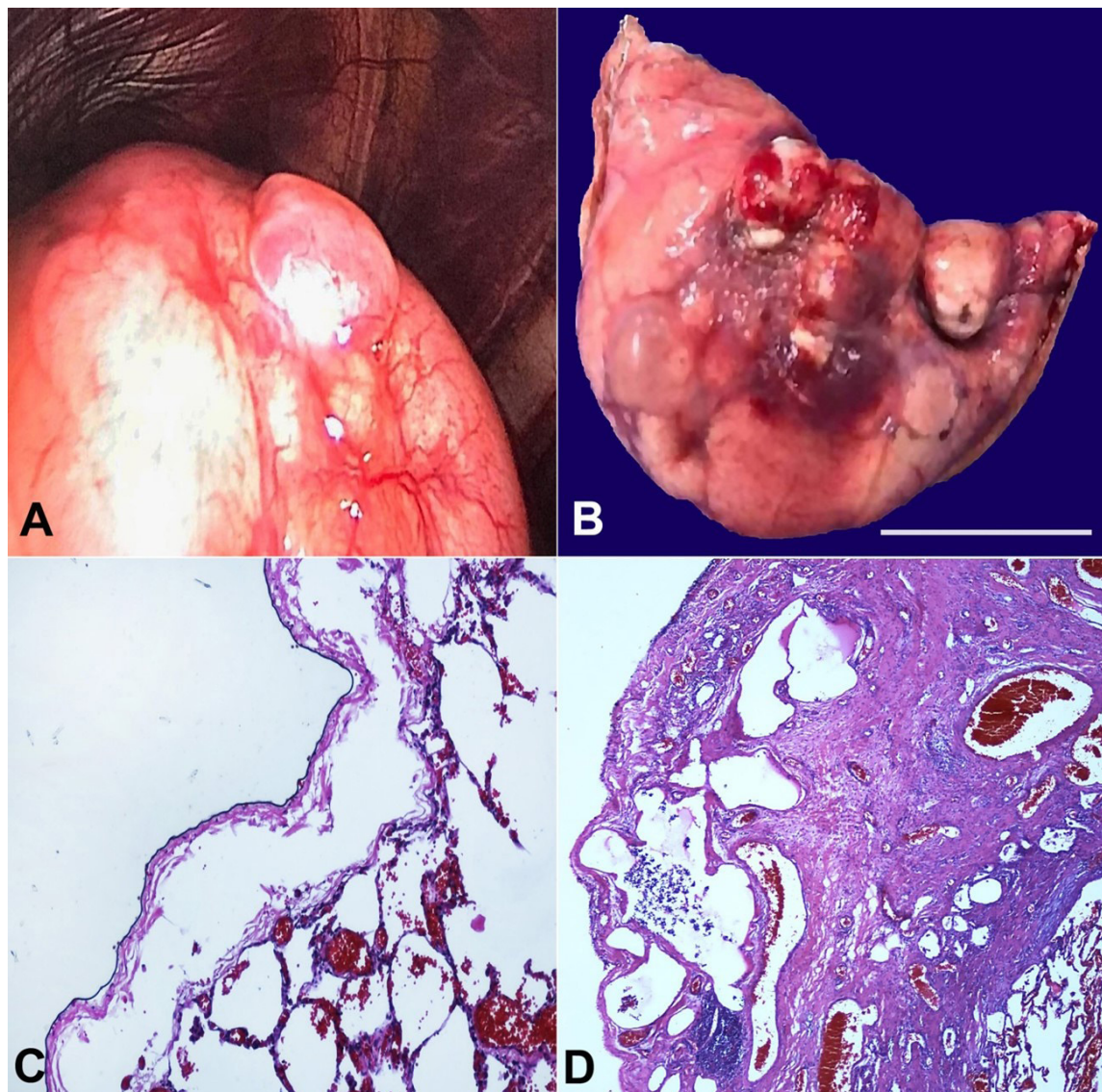


Figure 1. **A** - video-assisted thoracoscopy reveals a bulla surrounded inferiorly by an area with increased vascularity and pleural retraction; **B** - surgical specimen from the lung apex with several bullae (scale bar= 2cm); **C** - areas exhibiting subpleural and intrapleural air accumulation (H&E; 100x); **D** - pleural porosity characterized by intense fibrous thickening of the visceral pleura, interspersed with air within the fibrotic regions (H&E; 100x).

¹ Universidade Federal do Triângulo Mineiro (UFTM), Laboratório de Imunologia e Bioinformática, Uberaba, MG, Brasil

² Universidade Federal do Triângulo Mineiro (UFTM), Unidade de Análises Clínicas e Anatomia Patológica, Uberaba, MG, Brasil

Pneumothorax is the presence of air in the pleural space, clinically classified as spontaneous when no identifiable precipitating factors exist and non-spontaneous when such factors are present. Further subdivision delineates into primary in the absence of an evident clinical cause and secondary when a causal relationship exists with an underlying medical condition. Thus, primary spontaneous pneumothorax (PSP) is characterized by air in the pleural space in patients without manifest clinical or pulmonary disorders.^{1,2}

The annual incidence of PSP ranges from 7.4 to 18 cases per 100,000 in males and 1.2 to 6 cases per 100,000 in females.³ Patients with PSP typically exhibit a phenotype characterized by leanness and tall stature. Predisposing factors such as family history, Marfan syndrome, thoracic endometriosis, smoking, bronchiolitis, Birt-Hogg-Dubé syndrome, and homocystinuria may be associated with this entity. Changes in atmospheric pressure can also precipitate PSP.^{3,4} It commonly occurs at rest and is not correlated with physical activity. Most patients with PSP experience sudden ipsilateral pleuritic pain. Chest radiography and clinical history provide a highly accurate diagnosis, while occasional cases with small air volumes may require a computed tomography for diagnosis.^{1,4}

Many authors⁵⁻⁷ suggest that spontaneous rupture of a subpleural bleb or bulla causes PSP. However, the mechanism behind the accumulation of subpleural air has yet to be clearly described. Currently, the likely cause is believed to be the degradation of lung elastic fibers induced by factors like smoking. This degradation increases neutrophils' and macrophages' concentration, thereby enhancing elastic degradation.^{1,3} Air can enter the interlobular septum through alveolar ruptures and accumulate in the subpleural regions. Additionally, pleural porosity has been described as an area where disruption of mesothelial cells in the visceral pleura occurs, leading to their replacement by fibroblastic tissue and increased porosity that permits air to enter the subpleural space.^{5,6}

The treatment of PSP remains controversial, lacking a definitive consensus to date. Some studies indicate that outpatient treatment or sole pleural drainage results in a 38% recurrence rate of PSP.

Conversely, patients treated with bullectomy, involving the surgical removal of blebs typically situated at the apex of the lung, combined with pleurodesis—a procedure inducing a fibrotic reaction in the pleura—demonstrate no recurrence.^{8,9} Ongoing debate surrounds the necessity of routine anatomopathological analysis post-surgery for all patients with PSP, as it might not change the prognosis in numerous cases.⁵⁻⁷

In this report, we present the gross and histopathological findings from a 20-year-old male patient. He stood at 192 cm, weighed 75 kg, with a body mass index of 20.35, and experienced sudden left thoracic pain and dyspnea while walking. An imaging workup revealed a significant air volume in the pleural cavity along with numerous apical blebs in the left lung. Subsequently, the treatment involved apical segment excision of the left lung, followed by pleurodesis.

During the surgical approach using video-assisted thoracoscopy, we observed a sizable bulla surrounded by an area displaying increased vascularity and pleural retraction inferiorly, likely attributed to the prior rupture of another bulla or inflation (Figure 1A). The surgical specimen obtained from the apex of the left lung showed several bullae containing hematic contents, likely due to surgical manipulation, alongside areas consistent with previously ruptured bullae (Figure 1B). Microscopic analysis revealed areas demonstrating subpleural and intrapleural air accumulation, such as pleural interstitial emphysema (Figure 1C). Evidence of pleural porosity, characterized by intense fibrous thickening of the visceral pleura interspersed with air within the fibrotic regions, was observed (Figure 1D). The microscopic findings are significant as they correspond with the presumed mechanism involved in bleb formation.

Keywords

Pleura; Pleurodesis; Pneumothorax

ACKNOWLEDGEMENTS

The authors express their sincere gratitude to all the collaborators from the Unidade de Análises Clínicas e Anatomia Patológica at the Clinical Hospital and the collaborators from the Laboratório de Imunologia e Bioinformática at the Universidade Federal do Triângulo Mineiro.

REFERENCES

1. Grundy S, Bentley A, Tschopp JM. Primary spontaneous pneumothorax: a diffuse disease of the pleura. *Respiration*. 2012;83(3):185-9. <http://dx.doi.org/10.1159/000335993>. PMID:22343477.
2. Baumann MH, Strange C, Heffner JE, et al. Management of spontaneous pneumothorax: an American College of Chest Physicians Delphi consensus statement. *Chest*. 2001;119(2):590-602. <http://dx.doi.org/10.1378/chest.119.2.590>. PMID:11171742.
3. Noppen M. Spontaneous pneumothorax: epidemiology, pathophysiology and cause. *Eur Respir Rev*. 2010;19(117):217-9. <http://dx.doi.org/10.1183/09059180.00005310>. PMID:20956196.
4. Tschopp JM, Bintcliffe O, Astoul P, et al. ERS task force statement: diagnosis and treatment of primary spontaneous pneumothorax. *Eur Respir J*. 2015;46(2):321-35. <http://dx.doi.org/10.1183/09031936.00219214>. PMID:26113675.
5. Sauter JL, Butnor KJ. Pathological findings in spontaneous pneumothorax specimens: does the incidence of unexpected clinically significant findings justify routine histological examination? *Histopathology*. 2015;66(5):675-84. <http://dx.doi.org/10.1111/his.12523>. PMID:25234592.
6. Bintcliffe OJ, Hallifax RJ, Edey A, et al. Spontaneous pneumothorax: time to rethink management? *Lancet Respir Med*. 2015;3(7):578-88. [http://dx.doi.org/10.1016/S2213-2600\(15\)00220-9](http://dx.doi.org/10.1016/S2213-2600(15)00220-9). PMID:26170077.
7. Khan OA, Tsang GM, Barlow CW, Amer KM. Routine histological analysis of resected lung tissue in primary spontaneous pneumothorax -- is it justified? *Heart Lung Circ*. 2006;15(2):137-8. <http://dx.doi.org/10.1016/j.hlc.2005.10.007>. PMID:16497556.
8. Brown SGA. Pleurodesis for primary spontaneous pneumothorax. *Lancet*. 2013;382(9888):203. [http://dx.doi.org/10.1016/S0140-6736\(13\)61592-5](http://dx.doi.org/10.1016/S0140-6736(13)61592-5). PMID:23870526.
9. Vuong NL, Elshafay A, Thao LP, et al. Efficacy of treatments in primary spontaneous pneumothorax: a systematic review and network meta-analysis of randomized clinical trials. *Respir Med*. 2018;137:152-66. <http://dx.doi.org/10.1016/j.rmed.2018.03.009>. PMID:29605200.

This study was carried out at Universidade Federal do Triângulo Mineiro, Uberaba, MG, Brazil.

Authors' contributions: Yago Marcos Pessoa-Gonçalves and Ana Clara Vaz e Silva contributed to the analysis of the pathologic findings, manuscript writing, and critically analyzed clinical data. Lucinda Calheiros Guimarães and Sheila Jorge Adad verified the histopathological aspects and edited the manuscript. Carlo José Freire Oliveira reviewed and edited the manuscript.

Ethics statement: This study followed the guidelines set forth by the Brazilian Human Research Ethics Evaluation System (CEP/CONEP) and was clearance by the Institutional Ethics Committee under protocol CAAE: 73435223.6.0000.8667. The authors retain informed consent signed by the patient authorizing the data publication.

Conflict of interest: None.

Financial support: Fundação de Amparo à Pesquisa supported this study do Estado de Minas Gerais (FAPEMIG), Coordenação de Aperfeiçoamento de Pessoal de Nível Superior (CAPES), and Conselho Nacional de Desenvolvimento Científico e Tecnológico. The funding sources were not involved in the study design, in the collection, analysis, and interpretation of data, in the report's writing, or in submitting the article for publication.

Submitted on: December 13th, 2023

Accepted on: December 22nd, 2023

Correspondence

Carlo José Freire Oliveira

Universidade Federal do Triângulo Mineiro (UFTM), Laboratório de Imunologia e Bioinformática

Research Building Prof. Aluizio Rosa Prata, 100 Vigário Carlo Street, ZIP Code 38025-180, Uberaba, MG, Brazil

Phone: +55 (34) 88567251

carlo.oliveira@uftm.edu.br