



Revista MVZ Córdoba
ISSN: 0122-0268
ISSN: 1909-0544
revistamvz@gmail.com
Universidad de Córdoba
Colombia

Duran P, Nazly; Franco G, Mónica; G Riva, Henrique; Flórez G, José
Prevalence of gastrointestinal endoparasites and ectoparasites in ex situ snakes in Barranquilla, Colombia
Revista MVZ Córdoba, vol. 25, no. 1, 2020, -, p. 1537
Universidad de Córdoba
Colombia

DOI: <https://doi.org/10.21897/rmvz.1537>

Available in: <http://www.redalyc.org/articulo.oa?id=69361538019>

- ▶ How to cite
- ▶ Complete issue
- ▶ More information about this article
- ▶ Journal's webpage in redalyc.org

LUZMA
redalyc.org

Scientific Information System Redalyc





Network of Scientific Journals from Latin America and the Caribbean, Spain and Portugal

Project academic non-profit, developed under the open access initiative



Original

Prevalence of gastrointestinal endoparasites and ectoparasites in *ex situ* snakes in Barranquilla, Colombia

Nazly Duran P^{1*}  MV; Mónica Franco G²  MVZ; Henrique G Riva²  MV; José Flórez G¹  Ph.D.

¹Universidad de Pamplona, Facultad de Ciencias Agrarias, Programa de Medicina Veterinaria, Km 1 vía Bucaramanga Ciudad Universitaria, Pamplona, Colombia.

²Fundación Botánica y Zoológica de Barranquilla, Departamento de Veterinaria, Calle 77#68-40, Barranquilla, Colombia.

*Correspondencia: mvduranazly@outlook.es

Received: May 2019; Accepted: August 2019; Published: January 2020.

ABSTRACT

Objective. The aim of this study was to identify the prevalence of endoparasites and ectoparasites in *ex situ* snakes at the Barranquilla Zoo. **Materials and Methods.** Stool samples and ectoparasites of 2 colubrids (*Leptophis ahaetulla* and *Spilotes pullatus*), 2 diapsids (*Oxybelys aeneus* and *Thamnodynastes paraguanae*) and 13 boids (9 specimens of *Boa constrictor*, 2 of *Epicrates maurus* and 2 *Eunectes murinus*) were analyzed using flotation method in saturated sugar solution and direct observation. **Results.** The results showed that 65% (11/17) of the animals were positive to the presence of parasites. In relation to the positive specimens, 91% (10/11) belong to the Boidae family, presenting mostly nematodes, in the diapsid's samples mainly protozoans were observed and the colubrid's samples were negative. Regarding ectoparasites, 2 species of ticks (*Amblyomma dissimile* and *Ornithodoros turicata*) were found in specimens of *Boa constrictor*, *Epicrates maurus* and *Spilotes pullatus*. **Conclusions.** The identification of parasites in this research represents a contribution to the study of parasitology in snakes *ex situ* in Colombia. It provides information to develop preventive measures against pathological agents and allows comparing results with other studies with animals in the wild and under human care.

Keywords: Argasidae; Boidae; Colubridae; Dipsadinae; Ixodidae; Parasitology (*Sources: MeSH, DeCS*).

RESUMEN

Objetivo. Identificar la prevalencia de endoparásitos y ectoparásitos en serpientes *ex situ* en la Fundación Botánica y Zoológica de Barranquilla. **Materiales y métodos.** Para esto se analizaron muestras de materia fecal y ectoparásitos de 2 colúbridos (*Leptophis ahaetulla* y *Spilotes pullatus*), 2 dipsadinos (*Oxybelys aeneus* y *Thamnodynastes paraguanae*) y 13 boidos (9 individuos de la especie *Boa constrictor*, 2 de *Epicrates maurus* y 2 de *Eunectes murinus*) utilizando los métodos de flotación en solución saturada de azúcar y observación directa. **Resultados.** Los resultados obtenidos mostraron que el 65% (11/17) de los animales evaluados fueron positivos a la presencia de parásitos,

How to cite (Vancouver).

Duran PN, Franco GM, Riva HG, Flórez GJ. Prevalence of gastrointestinal parasites and ectoparasites in *ex situ* snakes in Barranquilla, Colombia. Rev MVZ Córdoba. 2020; 25(1):e1537. DOI: <https://doi.org/10.21897/rmvz.1537>



©The Author(s), Journal MVZ Córdoba 2020. This article is distributed under the terms of the Creative Commons Attribution 4.0 International License (<https://creativecommons.org/licenses/by-nc-sa/4.0/>), lets others remix, tweak, and build upon your work non-commercially, as long as they credit you and license their new creations under the identical terms.

de los cuales el 91% (10/11) de los ejemplares pertenece a la familia Boidae presentando en su mayoría nematodos, mientras que en los dipsadinos se observaron principalmente protozoarios y los colúbridos resultaron negativos. Finalmente como ectoparásitos se identificaron 2 especies de garrapatas (*Amblyomma dissimile* y *Ornithodoros turicata*) halladas en ejemplares de *Boa constrictor*, *Epicrates maurus* y *Spilotes pullatus*. **Conclusiones.** La identificación de las formas parasitarias en este trabajo representa una contribución para el conocimiento de los parásitos en serpientes *ex situ* en Colombia. Provee información para desarrollar medidas profilácticas y permite comparar los datos sobre las formas parasitarias encontradas con muestreos de estas especies en vida silvestre y bajo cuidados humanos.

Palabras clave: Argasidae; Boidae; Colubridae; Dipsadinae; Ixodidae; Parasitología (Fuente: MeSH, DeCS).

INTRODUCTION

Zoos are institutions that have several animal species under their care. They also incorporate plans of education for conservation within their mission and offer an experience to visitors in order to make them aware of subjects related to the loss of biodiversity (1). Additionally, the husbandry of animals *ex situ* presents several challenges such as animal welfare, space requirements and veterinary attention (2), since living in a controlled environment does not exempt animals from presenting parasites or any other health disorder.

Snakes can have ectoparasites and endoparasites both *in situ* and *ex situ*, however, those are rarely studied and therefore not well known. Apart from the above, only one individual or very small populations are usually examined. However, certain studies describe nematodes such as *Dracunculus brasiliensis*, found in *Eunectes murinus* (3), oxyurids in *Boa constrictor* and *Python regius* (4), *Cruzia* sp., *Kalicephalus subulatus*, *Styphlodora horridum* (5) *Eimeria* spp., *Capillaria* spp., *Sarcocystis* spp., *Kapsulotaenia* spp. (6) *Rhabdias* spp., *Porocephalus* spp. in *Epicrates cenchria* (7), and ticks like *Rhipicephalus* sp., *Aponomma* sp. and *Amblyomma* sp. (8).

Reports of the prevalence of gastrointestinal endoparasites and ectoparasites in snakes in Colombia are scarce. A literature review resulted in only two studies (9,10), which describe the finding of *Amblyomma dissimile* in two specimens of *Boa constrictor* and one specimen of *Spilotes pullatus*. Considering the importance of expanding the knowledge about parasites in snakes, the present study aimed to identify the prevalence of gastrointestinal endoparasites and ectoparasites in snakes under human care at the Barranquilla Zoo.

MATERIALS AND METHODS

Area of Study. The study was performed at the Barranquilla Zoo's herpetarium, located in the city of Barranquilla - Colombia. Geoclimatic conditions: Barranquilla has an average minimum temperature of 25°C and a maximum of 33.5°C, rains that range between 70-178 mm/month and a relative humidity of 84%. Coordinates: 11°00' 38"N 74°47' 49"O (IDEAM Colombia).

Animals for study. The study was performed during 12 weeks with the snake species listed on Table 1. Two of the 9 specimens of *B. constrictor* were in the same terrarium, and the remaining specimens were located in individual terrariums.

Table 1. Snake species in Barranquilla Zoo's collection.

Common Name	Scientific Name	Number of individuals	Body weight (sex)
Common Boa	<i>Boa constrictor</i>	9	4 kg (M); 2.6 kg (M); 2,3 kg (M); 2.8 kg (F); 7,7 kg (F); 4.2 kg (F); 2 kg (F); 2 kg (F); 2,9 kg (F)*
Colombian Rainbow Boa	<i>Epicrates maurus</i>	2	0,6 kg (M); 0,6 kg (M)
Parrot Snake	<i>Leptophis ahaetulla</i>	1	0,08 kg (M)
Brown Vine Snake	<i>Oxybelis aeneus</i>	1	0,08 kg (F)
Yellow Rat Snake	<i>Spilotes pullatus</i>	1	0,6 kg (F)
Paraguana Mock Viper	<i>Thamnodynastes paraguanae</i>	1	0,05 kg (M)
Green Anaconda	<i>Eunectes murinus</i>	2	12,9 kg (M); 33,3 kg (F)
Total		17	

*(M) Male, (F) Female.

All the snakes listed in Table 1 were under human care for over two years, with the exception of two *B. constrictor*. Both boas entered the institution one year prior to the collection of samples for this study, after undergoing the quarantine process described below in the preventive medicine section.

The specimens were fed with mice (*Mus musculus*), rats (*Rattus rattus*) or chickens (*Gallus gallus*), bred for this purpose in the bioterium of the Barranquilla Zoo. The feeding frequency (weekly or twice a month) and the type of prey varied depending on the size of each specimen.

The animals bred at the bioterium were fed with commercial pellets with sawdust as substrate which was changed weekly. Additionally, stool analysis were performed (direct fecal smear and Sheather technique) in pool samples every 3 months with de specimens from the bioterium. During the first week of sample collection for this study, the rodents were tested positive to *Hymenolepis diminuta* and *Aspiculuris tetraptera*.

Description of the terrarium. The snakes were located at the Herpetarium area which included 18 terrariums. The enclosures had concrete walls on three sides (laterals and back), one metallic mesh roof (for ventilation), and the front on template glass to allow the observation of the animals. The terrariums had an approximate dimension of 1.1 x 1.1 m x 1.5 m. They also contained live plants, dry leaves, and different substrates (sand, rocks or gravel). The terrariums do not have any heating systems due to Barranquilla's climate conditions. The design of the enclosures does not allow the snakes to move between terrariums, neither permits free ranging animals to enter, except insects such as cockroaches or beetles. However, animals such as iguanas, birds, squirrels and other free rodents can walk on the roof of the terrariums and even be in contact with the mesh located on the top.

Cleaning and disinfection of the terrariums. Cleaning and disinfection of the water bowls consisted in washing them with soap and water daily, as well as the disinfection with sodium hypochlorite at 1% once a week. The complete disinfection of each terrarium was performed when an animal was transferred to a new enclosure or due to specific sanitary conditions.

The disinfection consisted in changing the substrate and spray glutaraldehyde at 0.05% and quaternary ammonium at 0.01% at walls, hangers and substrate.

Preventive Medicine. Annually, a clinical exam was performed to the snakes located in the Herpetarium. Said medical exam consisted of: a complete clinical exam, collection of blood samples (complete hemogram and biochemical exams) and stool samples. The animals received treatment against parasites when tested positive. New individuals in the collection went through a minimum period of 3 months in quarantine, isolated from the main collection. Each individual required three negative samples (direct fecal smear, Sheather technique and modified Ziehl-Neelsen technique) and one clinical evaluation before being transferred to the Herpetarium. Additionally, biochemical tests (uric acid, albumin, aspartate aminotransferase and creatine phosphokinase) were performed depending on the size of the snake.

Sample analysis. Approximately, 2 to 5 g of feces were collected from the area each animal was located. These samples were stored in labelled plastic containers under refrigeration at 4°C until analysis (refrigeration time that did not surpass 24 hours). The recollection of a total of three samples were initially planned for each animal. The ectoparasite samples were taken directly from the animal's skin and deposited in eppendorf tubes with 70% alcohol. The stool samples were analyzed through a direct fecal smear and floating techniques. The later was implemented through sugar saturated solution described by Kassa et al (11). On the other hand, a stereoscope was used to identify the ectoparasites through anatomical characteristics that allowed the classification according to Quiroz's description (12). The specific prevalence reported were obtained by dividing the number of individuals with parasites, by the number of individuals evaluated, and multiplying it by one hundred.

Finally, the ethical, technical, scientific and administrative norms for animal research contained in Law 84 by the Colombian Congress were taken into account to sample collection, handling, and preservation procedures. Also, this study was performed during preventive medicine procedures approved by the Barranquilla Zoo's Veterinary Department.

RESULTS

During the present study, 43 stool samples were collected from a total of 17 specimens (Table 2).

65% (11/17) of the snakes tested positive for parasites. Among the positive, 91% (10/11) were boids. The nematodes were found more significantly in boids, while in dipsadinae's snakes protozoa were detected. The presence of protozoa was identified as flagellates and endoparasites belonging to the Eimeriidae family, and nematodes like *Capillaria* sp., larvated and non-larvated eggs belonging to Strongylida and Rhabditiformes larvae (Figure 1).

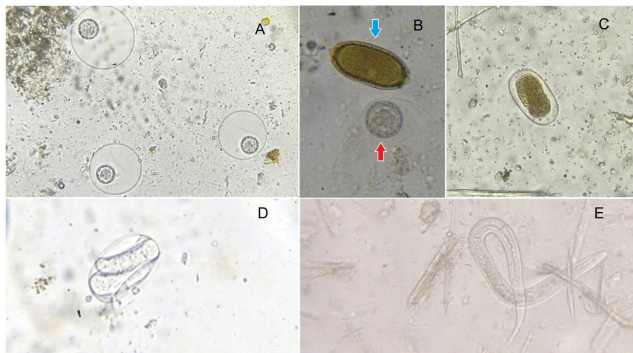


Figure 1. Endoparasites identified in Barranquilla Zoo's snakes, objective of 400x. **A:** Oocyst of parasites of the Eimeriidae family found in *E. murinus*, direct fecal smear. **B:** *Capillaria* sp. egg (blue arrow) and Oocyst of parasites of the Eimeriidae family (red arrow) found in *E. murinus*, direct fecal smear. **C:** Non-larvated egg of nematode of the Strongylida order found in *B. constrictor*, flotation exam. **D:** Larvated egg of nematode of the Strongylida order found in *B. constrictor*, flotation exam. **E:** Rhabditiform larvae found in *T. paraguanae*, direct fecal smear. Source: Duran, 2016.

Within the positive boids, nematodes presented greater prevalence than protozoa (Eimeriidae family and Flagellates), being identified in 100% of the boids (10/10), while protozoa was found only in 20% (2/10). In the *E. murinus* specimens, *Capillaria* sp., was identified, as well as endoparasites belonging to the Eimeriidae family, being the only boids with multiple parasites. In the Colubridae and Dipsadinae families (*Leptophis ahaetulla*, *Oxybelis aeneus*, *Spilotes pullatus*, and *Thamnodynastes paraguanae*), only one sample tested positive. (*T. paraguanae*), identifying Rhabditiformes larvae and flagellates. Flagellates were identified in 3 of 4 samples analyzed of the specimen *T. paraguanae* (Table 2).

A prevalence of 24% (4/17) was determined for non-larvated eggs of nematodes from Strongylida, 18% (3/17) for larvated eggs of nematodes from Strongylida, 12% (2/17) for parasites of the Eimeriidae family and *Capillaria* sp., 24% (4/17) for Rhabditiform larvae, and 6% (1/17) for flagellates.

The presence of parasites in the positive samples (Table 2) varied as following: 36% (4/11) of *B. constrictor* were positive for non-larvated eggs of Strongylida, 27% (3/11) had larvated eggs from Strongylida, and 9% (1/11) had Rhabditiform larva. Regarding *E. murinus*, the Eimeriidae family and *Capillaria* sp. were found in the two specimens evaluated. Likewise, Rhabditiform larvae was observed in the two individuals of *E. maurus* evaluated. Finally, three of four samples of the only *T. paraguanae* specimen evaluated tested positive for flagellates and one for Rhabditiform larva.

Table 2. Endoparasites found in samples of snakes at the Barranquilla Zoo.

Specie (number of individuals)	Parasites						* M+	* M-	Total
	NLE	LE	Larvae R.*	Eimeriidae family	Capillaria sp.	Flagellates			
<i>B. constrictor</i> (9)	4	3	1	0	0	0	8	11	19
<i>E. murinus</i> * (2)	0	0	0	1*	1*	0	1	0	1
<i>E. maurus</i> (2)	0	0	3	0	0	0	3	3	6
<i>S. pullatus</i> (1)	0	0	0	0	0	0	0	5	5
<i>O. aeneus</i> (1)	0	0	0	0	0	0	0	2	2
<i>T. paraguanae</i> (1)	0	0	1	0	0	3	4	3	7
<i>L. ahaetulla</i> (1)	0	0	0	0	0	0	0	2	2
Total	4	3	5	1*	1*	3	16	26	42

NLE= Non-larvated egg of the Strongylida order; LE= Larvated egg of the Strongylida order; *The *E. murinus* sample was performed in pool; Larvae R: Rhabditiform larvae; *M+: Positive samples; *M-: Negative samples.

Apart from the above, seven samples of ectoparasites were found in the terrariums of the following species: 5 *Boa constrictor*, one *Spilotes pullatus* and one *Epicrates maurus* (Table 3). The tick *Ornithodoros turicata* of the Argasidae family (Figure 2) was identified in six samples. Additionally, the tick *Amblyomma dissimile* of the Ixodidae family (Figure 3) was identified in one sample belonging to *B. constrictor*.

Table 3. Ectoparasites identified in samples of snakes at the Barranquilla Zoo.

Species	Ectoparasites	
	<i>A. dissimile</i>	<i>O. turicata</i>
<i>Boa constrictor</i>	1	4
<i>Eunectes murinus</i>	0	0
<i>Epicrates maurus</i>	0	1
<i>Spilotes pullatus</i>	0	1
<i>Oxybelis aeneus</i>	0	0
<i>Thamnodynastes paraguanae</i>	0	0
<i>Leptophis ahaetulla</i>	0	0
Total	1	6

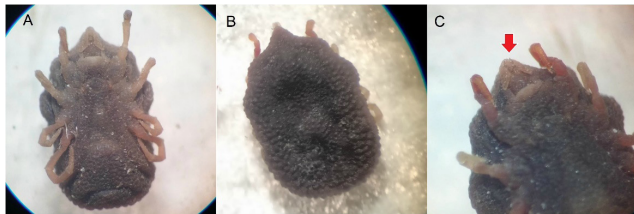


Figure 2: *Ornithodoros turicata* tick identified in *B. constrictor*, *S. pullatus* and *E. maurus*. **A.** ventral view, **B.** dorsal view (papilliform body) **C.** poorly developed hypostome (red arrow). Source: Duran, 2016.




Figure 3: *Amblyomma dissimile* tick identified in *B. constrictor*, long palps (red arrow) with the second segment being shorter than wider. **A.** Dorsal view, **B.** shield (yellow arrow) and hypostome (blue arrow) and **C.** ventral view. Source: Duran, 2016

The previously named ectoparasites presented greater prevalence in boids than in Colubrid's snakes, since only one colubrid (*S. pullatus*) tested positive for the presence of ectoparasites. However, it must be taken into account that the number of boids is much higher than that of

colubrids in the present study. The tick species with the largest prevalence was *Ornithodoros turicata*, being found in six specimens of *B. constrictor* and in one individual of *S. pullatus*. Meanwhile, *Amblyomma dissimile* was only identified in one specimen of *B. constrictor*, as previously mentioned.

DISCUSSION

In the present study, 65% (11/17) of the animals tested positive for gastrointestinal parasites, as described in table 2. Two species of protozoa were identified (Flagellates and parasites of the Eimeriidae family) and 4 types of nematodes (non-larvated eggs and larvated eggs of nematodes of the Strongylidae order, *Capillaria* sp. and Rhabditiform larvae). 27% (3/11) of the individuals had multiple parasites and 73% (8/11) only had nematodes (Table 2).

The high prevalence of nematodes with direct life cycles is attributed to their characteristic of presenting free life parasitic forms. That allows them to survive in the environment for long periods of time, awaiting the precise moment to infect the host, which favors reinfection (10). On the other hand, boids (*Boa constrictor*, *E. maurus* and *E. murinus*) represented 91% (10/11) of the positive specimens, in which both protozoa and nematodes were identified. However, it must be considered that boids are the taxonomic group with the largest number of individuals in the present study.

The specimens were asymptomatic to the clinical signs typical of infections by nematodes and protozoa. For example: anorexia, lethargy, postprandial regurgitation, obstruction, vascular lesions, dispnea, weight loss, acute enteritis, and diarrhea (5, 13, 14). The exception was the only specimen of *T. paraguanae* presented aqueous and mucous feces during the entire study, one of the symptoms attributed to parasites from flagellates (15).

The results of this study are in accordance with the literature regarding the parasites identified (14). However, parasites from the Eimeriidae family were reported to be the Coccidia with greater incidence in *ex situ* reptiles, while in this study the prevalence was low (12%). Other authors (11,13,15,16,17), reported the identification of nematodes (*Strongylus* sp. and *Strongyloides* sp.), *Capillaria* sp., flagellates and *Eimeria* sp., in snakes. These results match with

those in the present study. Flagellate protozoa were reported as a parasite largely found in *ex situ* snakes (18), however, this differs from the results obtained in this work, as only one specimen tested positive for parasitosis due to flagellates. On the other hand, the presence of multiple parasites was more common than simple parasitosis agreeing with a study performed in Iran (19).

Some authors found the parasite *Hymenolepis* spp. in snake samples and have classified them as pseudo-parasites, as they come from infected rodents, without being pathogenic for snakes (3,20). However, this relation was not present in this investigation, since these parasites were not identified in the coprological exams, although the food sources (rodents) were contaminated (*Hymenolepis diminuta* and *Aspicularis tetraptera*).

Regarding the identification of ectoparasites, the tick *Amblyomma dissimile* was identified in a specimen of *B. constrictor*, as reported in literature (9,10). It is important to highlight this species as a transmitter of *Hepatozoon* sp. and *Rickettsia* sp., and that it affects species like *Epicrates* spp. (7,8). Although *A. dissimile* only affected one of the 17 specimens in this study, we cannot dismiss its presence in the future since it is possible for it to be contaminating the substrate or other parts of the exhibition. Apart from this, the parasite has been reported as the tick that most affects *ex situ* reptiles in Central and South America (8). Like the above, some authors report *A. dissimile* as the tick that most affects snakes of the *B. constrictor* species (21). Likewise, others report findings of species of *Amblyomma* sp. in *E. murinus* (22). However, different from these reports, *E. murinus* did not present ectoparasites in the present study. Finally, in contrast with *A. dissimile* reported in colubrids (23), this ectoparasite was not present in colubrids assessed in this investigation.

Apart from the prior tick species, we identified *Ornithodoros turicata*, which has already been reported in other countries as affecting reptiles (24). As far as we know, this is the first report of said tick species as ectoparasite in snakes in Colombia. Likewise, we observed that this tick originally from the United States and Mexico is also recognized as a vector of the spirochaete (*Borrelia turicatae*). A pathogen that causes recurrent fever and is a possible transmitter of the African swine fever (24). It is worth

highlighting that *O. turicata* was found in samples of six boidae (*B. constrictor* and *E. maurus*) and only one colubrid (*S. pullatus*). In relation to the possibility of virus transmission, we should note that a specimen of *B. constrictor* died in the eighth week of the study with neurological symptoms. The death could possibly be associated with inclusion body disease (IBD), after an infestation of this species of tick. Although, this diagnosis was not confirmed due to the fact that the specimen presented advanced autolysis that did not allow taking samples for histopathology. It is possible that there is a relation between this tick species and the retrovirus that causes IBD.

In conclusion, the variety of endoparasites and ectoparasites found in this study is in accordance with literature reports. However, the prevalence in this study differed from other authors considering that it was developed with animals under human care. The food and water sources of each species studied have cleaning and disinfection plans that reduce the probability of occurrence of internal parasites contracted through feeding. In addition, the terrariums have a cleaning and disinfection plan that notably reduces the presence of ectoparasites. On the other hand, there are free-ranging iguanas (*Iguana iguana*) within the zoo's installations, which could be a source of parasite transmission. Considering that only direct cycle parasites were found and that all the snakes passed through the quarantine period testing negative for parasites, it is likely that these specimens were contaminated from contact with iguana feces that were circulating in the area or by insects serving as paratenic hosts. Finally, the identification of the parasites of ophidians in this work is an important contribution for the parasitology of this group of reptiles in Colombia. Since it provides information to develop preventive measures against pathological agents and allows comparing results with other studies with animals in the wild and under human care.

Conflict of Interests

The authors of the present article state that they do not have any type of conflict of interest related to the financial, intellectual, family or proprietary part that would constitute a conflict, whether effective potential or apparent.

Acknowledgments

The Barranquilla Zoo for allowing the development of the study in association with the University of Pamplona.

REFERENCES

1. Mellish S, Ryan J.C, Pearson E.L, Tuckey M.R. Research methods and reporting practices in zoo and aquarium conservation-education evaluation. *Conserv Biol.* 2019; 33(1):40-52. <https://doi.org/10.1111/cobi.13177> _
2. Bais B, Tak L, Mahla S. Study of preventive health measures for wildlife in captivity: a review of management approaches. *Int J Avian & Wildlife Biol.* 2017; 2(3):73-75. <https://doi.org/10.15406/ijawb.2017.02.00020>
3. Okulewicz A, Kaźmierczak M, Zdrzalik K. Endoparasites of exotic snakes (Ophidia). *Helminthologia.* 2014; 51(1):31-36. <https://doi.org/10.2478/s11687-014-0205-z>
4. Villalobos F, Troncoso I, Loyola E, Robles A, Aguilar J, Fernández I et al. Determinación coproscópica de formas parasitarias en heces de ofidios: *Boa constrictor* y *Python regius*. *Revista Científica FCV-LUZ.* 2014; 24(5):454-457. URL Disponible en: <http://produccioncientificaluz.org/index.php/cientifica/article/view/11805> _
5. González D, Durán J, Cedeño J. Helmintos parásitos de *Boa constrictor* (Serpentes: Boidae) en el sur de Quintana Roo. *Rev Mex Biodivers.* 2014; 85(3):831-837. <https://doi.org/10.7550/rmb.40515>
6. Wolf D, Globokar-Vrhovec M, Failing K, Rossier C, Hermosilla C, Pantchev N. Diagnosis of gastrointestinal parasites in reptiles: comparison of two coprological methods. *Acta Vet Scand.* 2014; 56(44):1-13. <https://doi.org/10.1186/s13028-014-0044-4>
7. Chávez L, Serrano-Martínez H, Tantaleán M, Quispe M, Casas G.C. Parásitos Gastrointestinales en Reptiles en Cautiverio en Lima Metropolitana. *Rev Inv Vet Perú.* 2015; 26(1):127-134. <http://dx.doi.org/10.15381/rivep.v26i1.10909>
8. Novakova M, Literak I, Chevez L, Martins F, Ogrzewalska M, Labruna B. Rickettsial infections in ticks from reptiles, birds and humans in Honduras. *Ticks Tick Borne Dis.* 2015; 6(6):737-742. <https://doi.org/10.1016/j.ttbdis.2015.06.009>
9. Carrascal J, Oviedo T, Monsalve S, Torres A. *Amblyomma dissimile* (Acari: Ixodidae) parásito de *Boa constrictor* en Colombia. *Rev MVZ Córdoba.* 2009; 14(2):1745-1749. <https://doi.org/10.21897/rmvz.358>
10. Paternina L, Verbel E , Bejarano E. First report of *Amblyomma dissimile* (Acari: Ixodidae) on *Spilotes pullatus* (Squamata: Colubridae) from Colombia. *Rev Inv Med Trop.* 2015; 1(1):23-25. URL Disponible en: <https://repositorio.unisucre.edu.co/handle/001/968>
11. Kassa D, Mengestie A, Ayalew N, Belaynew A, Mebrie Z, Metadel T. A Review on Diagnostic Techniques in Veterinary Helminthology. *Nat Sci.* 2016; 14(7):109-118. <https://doi.org/10.7537/marsnsj140716.15>
12. Quiroz H. Parasitología. 4th. ed. Mexico D.F: LIMUSA S.A; 1990.
13. Md-Robiul K, Fuchang Y, Jian L, Junqiang L, Longxian Z, Rongjun W et al. First molecular characterization of enteric protozoa and the human pathogenic microsporidian, *Enterocytozoon bienersi*, in captive snakes in China. *Parasitol Res.* 2014; 113(8):3041-3048. <https://doi.org/10.1007/s00436-014-3967-9>
14. Vergles A, Lindtner-Knific R, Vlahović K, Mavri U, Dovč A. Parasites in pet reptiles. *Acta Vet Scand.* 2011; 53(1):1-20. <https://doi.org/10.1186/1751-0147-53-33> _
15. Jepson, L. Medicina de animales exóticos guía de referencia rápida. 1ª. Ed. España: Elsevier; 2011.

16. Rinaldi L, Mihalca A, Cirillo R, Maurelli M, Montesano M, Capasso M et al. Flotac can detect parasitic and pseudoparasitic elements in reptiles. *Exp Parasitol*. 2012; 130(3):282–284. <https://doi.org/10.1016/j.exppara.2012.01.011>
17. Panayotova M. Parasites in captive animals: a review of studies in some european zoos. *Zool Gart*. 2013; 82(1-2):60-71. <https://doi.org/10.1016/j.zoolgart.2013.04.005>
18. Scullion F, Scullion M. Gastrointestinal protozoal diseases in reptiles. *J Exot Pet Med*. 2009; 18(4):266-278. <https://doi.org/10.1053/j.jepm.2009.09.004>
19. Nasiri V, Mobedi I, Dalimi A, Zare A, Ghaffarifard F, Teymurzadeh S et al. A description of parasites from Iranian snakes. *Exp Parasitol*. 2014; 147:7–15. <https://doi.org/10.1016/j.exppara.2014.09.007>
20. Raś-Noryńska M, Sokół R. Internal parasites of reptiles. *Ann Parasitol*. 2015; 61(2):115-117. https://www.annals-parasitology.eu/go.live.php/download_default/D667/internal-parasites-of-reptiles.html
21. Mogollón M, Pineda A, Benavides Y, Vargas L. *Amblyomma dissimile* en *Boa constrictor* en cautiverio del Centro de Atención y Valoración de Fauna Silvestre de Montería (Córdoba, Colombia). *Rev Med Vet*. 2017; (35): 29-34. <http://dx.doi.org/10.19052/mv.4386>
22. Guerrero R, Rodríguez-Acosta A. Primer reporte de infestación de la serpiente reinita *Erythrolamprus melanotus* (Shaw, 1802) (Serpentes: Dipsadidae) por el ácaro *Amblyomma dissimile* Koch, 1844 (Acarina: Ixodidae) en Venezuela. *Cuad Herpetol*. 2014; 28(2):241-143. URL disponible en: <http://ppct.caicyt.gov.ar/index.php/cuadherpetol/article/view/3052>
23. Mihalca A. Ticks imported to Europe with exotic reptiles. *Vet Parasitol*. 2015; 213(1-2):67–71. <https://doi.org/10.1016/j.vetpar.2015.03.024>
24. Donaldson, T.G, Pérez de León A, Li A, Castro-Arellano I, Wozniak W, Boyle W et al. Assessment of the Geographic Distribution of *Ornithodoros turicata* (Argasidae): Climate Variation and Host Diversity. *PLOS Neglected Tropical Diseases*. 2016; 10(3):e0004383. <https://doi.org/10.1371/journal.pntd.0004383>