



Revista Salud Uninorte

ISSN: 0120-5552

ISSN: 2011-7531

Fundación Universidad del Norte, División de Ciencias de la

Orozco Ariza, José de Jesús; Del Rio Rocha, Daniel Gustavo; Díaz Caballero, Antonio José
Residual cyst with semisolid content, a clinical case
Revista Salud Uninorte, vol. 34, no. 3, 2018, September-December, pp. 824-829
Fundación Universidad del Norte, División de Ciencias de la

Available in: <https://www.redalyc.org/articulo.oa?id=81759607029>

- ▶ How to cite
- ▶ Complete issue
- ▶ More information about this article
- ▶ Journal's webpage in redalyc.org

UNEN redalyc.org

Scientific Information System Redalyc

Network of Scientific Journals from Latin America and the Caribbean, Spain and Portugal

Project academic non-profit, developed under the open access initiative

Residual cyst with semisolid content, a clinical case.

Quiste residual con contenido semisólido, a propósito de un caso clínico

José de Jesús Orozco Ariza¹, Daniel Gustavo Del Rio Rocha²,
Antonio José Díaz Caballero³

Abstract

Objective: to present a clinical case of a residual cyst in the right maxillary region with semi-solid content.

Main data of the case: 61-year-old patient who comes to consultation for the realization of upper jaw dentures, during the clinical examination a slight facial asymmetry of the right side is observed; radiographic and tomographic examination revealed a radiolucent lesion in the right premolar region. It is diagnosed as a residual cyst and an enucleation is decided; during the surgical procedure a viscous content of yellowish coloration and semi-solid content is observed.

Main comments: it is very rare to find residual cysts with semi-solid content, since they generally have purulent or serosanguinous contents.

Keywords: residual cyst, odontogenic cyst, periapical granuloma, radicular cyst, oral pathology. (DeCs)

Resumen

Objetivo: presentar un caso clínico de un quiste residual en la región maxilar derecha, con contenido semisólido.

Datos principales del caso: paciente de 61 años, que acude a consulta para la realización de una prótesis en el maxilar superior, al examen clínico se observa leve asimetría facial del lado derecho; al examen radiográfico y tomográfico se observa lesión radiolúcida en región premolar derecha. Se diagnostica como quiste residual y se decide enucleación, en el procedimiento quirúrgico se observa un contenido viscoso de coloración amarillenta y contenido semisólido.

Principales comentarios: es muy poco común encontrar quistes residuales con contenido semisólido, generalmente son de contenido purulento o serosanguinoso.

Palabras claves: quiste residual, quiste odontogénico, granuloma periapical, quiste radicular, patología oral (DeCS).

¹ Odontólogo, Universidad Metropolitana. Especialista en Estomatología y Cirugía Oral, Magíster en Educación, Universidad de Cartagena. Docente cátedra, Universidad de Cartagena.

² Odontólogo, Universidad De Cartagena.

³ Odontólogo, Universidad de Cartagena. Especialista en Periodoncia, Universidad Javeriana. Magíster en Educación, Universidad del Norte. Doctorado en Ciencias Biomédicas, Universidad de Cartagena. Docente titular, Universidad de Cartagena. Director, Grupo de investigaciones GITOU.

Correspondencia: Daniel Del Rio Rocha Dirección: Facultad de odontología, Universidad de Cartagena, Barrio Zaragocilla Carrera 50 No. 29 – 11. Código Postal: 130015. Teléfono: 6698173 Ext. 110 Email: ddelrior@unicartagea.edu.co

INTRODUCTION

A cyst is defined as a pathological cavity lined on the inside by epithelium and covered on its outer side by connective tissue, which encloses a liquid, semi-liquid or gaseous content; it is not a cavity created by accumulation of pus, generally lacks internal pressure since the content enters the cavity by osmosis. They are asymptomatic and are discovered in routine radiographic studies (1). According to the classification given by the WHO in 1992, cysts are classified according to their pathogenesis, as lesions produced during development, odontogenic and non-odontogenic, which can be transformed into a pathology with signs of malignancy or radicular cysts of inflammatory origin (2, 3). In 2005 the WHO classified cysts into three main categories, jaw cysts, cysts associated with cavities of the maxillaries and cysts associated with soft tissues of the mouth, face, neck and salivary glands. (4)

Residual cysts are radicular cysts that remain or form after the responsible tooth has been extracted, this pathology may have been previously a lateral cyst or an apical cyst and after the tooth has been extracted, the cyst remains in the bone tissue without having been excised (5, 6). This type of cyst usually does not present symptoms and goes unnoticed until it is discovered in a routine radiographic examination or indicated to evaluate another clinical situation; however, many times, when the cysts reach a larger size, they cause facial asymmetry accompanied by some degree of pain (1, 7). Regarding its frequency, it occupies the second place among inflammatory cysts, and is usually of greater incidence in males, they occur mainly in non-vital teeth, in older individuals and in the mandibular region (8).

The objective of this publication is the presentation of a clinical case of a residual cyst with semi-solid content.

CLINICAL OBSERVATIONS

A 61-year-old female patient, consulted for anodontics in both posterior and anterior upper region, referring that she wants to get dentures for that area. In the anamnesis she reports not having any systemic diseases, nor consuming drugs, also states that in her youth many extractions were performed in her upper and lower jaw because of deep caries, the physical examination revealed a facial asymmetry in the middle third of the right hemi-face, secondary to a tumor. During the stomatological examination, swelling of 4 x 6 cm was observed, located in the right alveolar ridge, which produces effacement of the superior buccal sulcus, the mucosa that covers it has an appearance and color within normal parameters, of stony consistency, asymptomatic, non-depressible, non-mobile and with more than four years of evolution (Figure 1). Clinical diagnosis was established: residual cyst and as a differential diagnosis: development cyst, odontogenic and non-odontogenic tumor and mucocele.

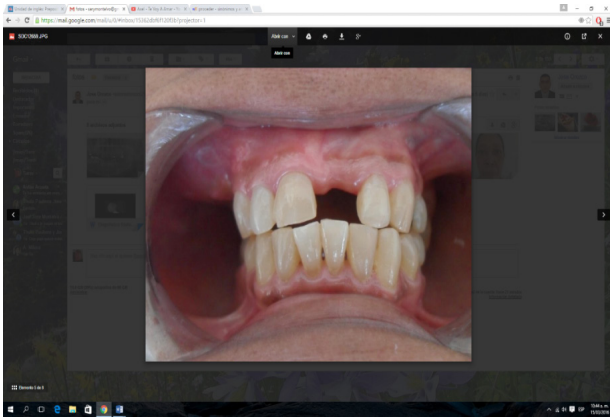
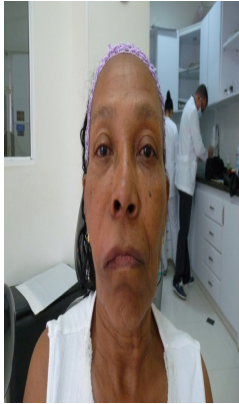

Figure 1. A. The facial asymmetry at the level of the cheekbones and above the right upper lip is observed. B. Intraoral photography before the procedure, there is swelling and effacement of the superior buccal sulcus, with a normal appearance on the mucosa that covers it, the dates indicate the comparison of the right and left cheeks.

On the radiographic examination, with panoramic x-rays (Figure 2), a radiolucent image with well-defined, smooth edges of 4x6 cm was observed, involving the edentulous area of the dental organs 14, 15, 16, 17 and without maxillary sinus involvement.

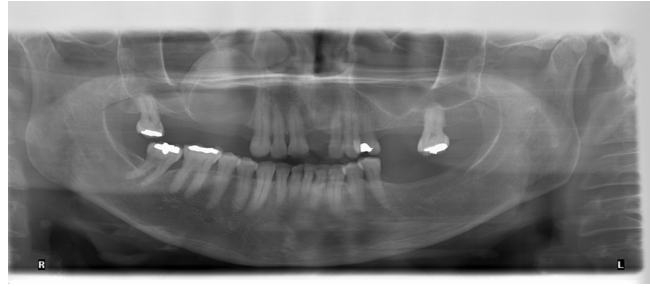

Figure 2. Panoramic x-rays, a radiolucent lesion was observed in the upper premolar area of the right side, with defined edges, without involvement of the maxillary sinus.

To corroborate the diagnosis and verify the real magnitude of the lesion, it was decided to perform a simple CT scan (computerized axial tomography) of the face (Figure 3), where an expansive image of 6 cm in diameter was observed, which presses the floor of the maxillary sinus, producing a reduction in its dimension. Taking into account the clinical history of the patient, clinical and radiographic characteristics, the diagnosis of residual cyst (RC) is presumed. Due to the patient's urgent need to perform the rehabilitation of the area, it was decided to perform the complete removal of the lesion as a definitive treatment, since it did not present malignant characteristics and an unknown content, it was decided to send the specimen to pathology in order to confirm the presumptive diagnosis.

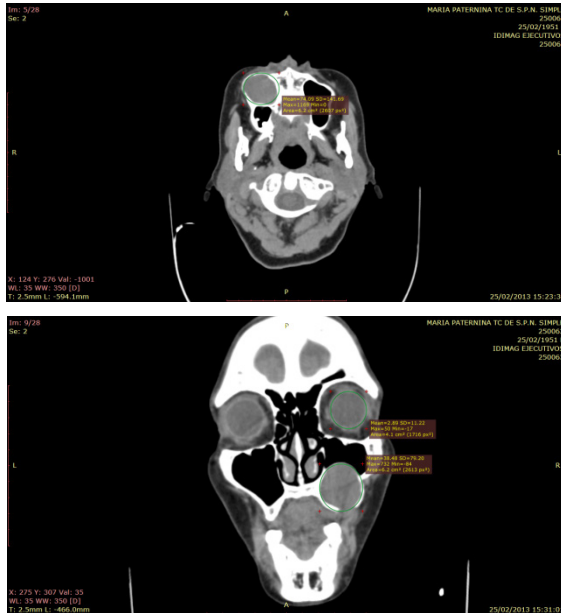


Figure 3. On the left side, in a coronal section, the well-defined lesion is observed, with a diameter of 6.2 mm. On the right side, the lesion was observed in a cross section and its diameter was compared with the diameter of the eyeball with a difference of 2.1 mm, with a larger diameter of the cyst and a close relationship with the maxillary sinus.

The procedure was initiated with local anesthesia, with a posterior superior alveolar nerve block, medial superior alveolar nerve block, infraorbital nerve block, anterior and posterior palatine nerves, with previous asepsis and antisepsis of the area; an intrasulcular incision was made from the distal of the dental organ #13 to the mesial of dental organ #18, with anterior and posterior relaxants, complete Neumann flap, then a mucoperiosteal flap was raised, an osteotomy was performed to obtain a bone window, exposing the cystic membrane and extracting its contents, which had a yellow semi-solid consistency (Figure 4), all its content was removed and proceeded to remove the cystic membrane, which was deposited in a container with 10% formaldehyde and it was hermetically sealed and

referred to pathology, which showed the result of inflammatory cyst and, taking into account the 2005 WHO classification and the patient's history, it was diagnosed as a residual cyst.

The tissues were repositioned, sutured with 4/0 silk; the procedure was well tolerated and without complications. The pertinent recommendations were given and antibiotics and analgesics were prescribed. 1) Amoxicillin 500 mg. capsules every 8 hours for 5 days. 2) Nimesulide 100 mg. tablets every 12 hours for 3 days. Clinical and radiographic follow-ups were performed at three, seven, 15 and 21 days and then at one, three and six months period during which the patient did not report any discomfort, confirming in the radiographic studies the complete bone healing in the intervened area.

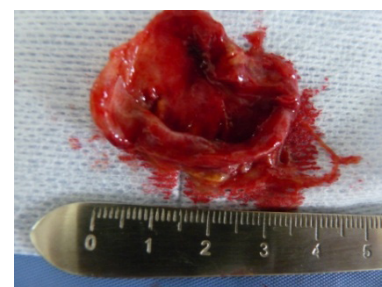
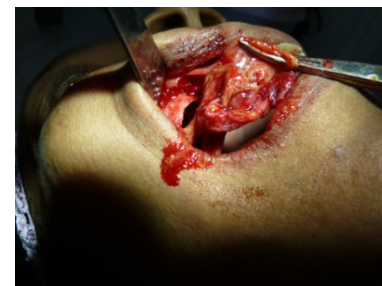
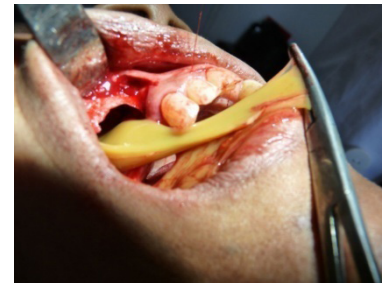
Figure 4. The semi-solid content of the cyst, its capsule and its diameter after its enucleation are shown.

DISCUSSION

The authors presented a case of a slow-growing residual cyst in the upper right maxillary region, without noticeable macroscopic changes, without symptoms or discomfort in the patient. It was detected by means of a routine examination for the installation of prosthetic elements, which agrees with many authors who affirm the eventuality of the findings with this type of inflammatory pathologies (2,3,7,9,10); when performing the enucleation of the cyst, a semi-solid, viscous, yellowish-colored content was found, which is not usual in this type of cysts. There are few studies that report this type of contents in residual cysts, hence its importance. Sridevi *et al* report a clinical case of residual cyst which, after aspiration biopsy prior to surgical removal, reveals serosanguinous content with cholesterol crystals (10), Jamdade *et al* report a clinical case of a periapical residual cyst that, upon cytological examination of the aspirates, the extracted liquid seemed to be a chronic inflammatory fluid, at the moment of the enucleation a yellowish and solidified material surrounded by a thin capsule was observed.

In 2014, Rivero *et al* reported a case of a giant residual cyst, which was the result of trauma in the lower posterior area, for which the definitive treatment was its complete enucleation. The most coherent general reasons to treat these cystic lesions are: 1) the growth of the cyst, which destroys the surrounding bone and can cause the involvement of neighboring structures, such as the nasal cavity or the maxillary sinus and cause repeated nasal

obstruction or sinusitis; 2) the possibility of infection attributable to the cyst, with its corresponding complications; 3) the need to perform a histopathological study to be certain of the true nature of the lesion (7).

CONCLUSIONS

Residual cysts are lesions commonly found in routine exams since they do not usually present symptoms, they generally present liquid content; in this clinical case a residual cyst with semi-solid content was evidenced, which is uncommon in dental practice.

REFERENCES

1. García-Rubio A, Bujaldón-Daza A, Rodríguez-Archilla A. Lesiones periapicales: diagnóstico y tratamiento. *Av Odontoestomatol.* 2015;31(1):31-42.
2. Vega-Llauradó A, Ayuso-Montero R, Teixidor-Olmo I, Salas-Enric J, Marí Roig A, López-López J. Opciones terapéuticas en quistes odontogénicos: Revisión. *Av Odontoestomatol.* 2013;29(2):81-93.
3. Molgatini S, Rey E, Basilaki J, Mosca C, Galante R, Gliosca L. Quiste odontogénico inflamatorio: aislamiento de *Pseudomonas stutzeri*. *Relevancia diagnóstica. AAM.* 2017;49(1):32-8.
4. Bharat-Sumbh DSGS, Pooja J, Jaishree P. Clasificación de odontogenic Cysts: A Review. *IOSR Journal of Dental and Medical Sciences (IOSR-JDMS)* 2017;16(4):79-82.
5. Díaz-Fernández JM, Puig-Ravinal LE, Vives-Folgar CB. Perfil epidemiológico, clínico y terapéutico de los quistes odontogénicos en Santiago de Cuba. *Medisan.* 2014;18(1):52-60.
6. Imran A, Jayanthi P, Tanveer S, Gobu SC. Classification of odontogenic cysts and tumors—Antecedents. *Journal of oral and maxillofacial pathology: JOMFP.* 2016;20(2):269.
7. Rivero-Pérez O, Albornoz López del Castillo C, Nápoles-González IdJ. Quiste resi-

- dual gigante: presentación de un caso. *AMC*. 2014;18(5):578-86.
8. Fungi-Monetti M. Revisión analítica de los quistes odontogénicos: Archivo de la Cátedra de Anatomía Patológica Facultad de Odontología UdelaR. *Odontoestomatología*. 2011;13(18):56-65.
 9. Jamdade A, Nair GR, Kapoor M, Sharma N, Kundendu A. Localization of a peripheral residual cyst: diagnostic role of CT scan. *Case Rep Dent*. 2012;2012.
 10. Sridevi K, Nandan SRK, Ratnakar P, Srikrishna K, Pavani BV. Residual cyst associated with calcifications in an elderly patient. *JCDR*. 2014;8(2):246.