

Reportes de Caso

# Candida parapsilosis endocarditis without vegetations at Echocardiography: a case report

Endocarditis por *Candida parapsilosis* sin vegetaciones  
ecocardiográficas: Un reporte de caso

*Natalia Vargas-Herrera*

*Centro Nacional de Salud Pública. Unidad de intervenciones  
estratégicas, Perú*

*Instituto Nacional de Salud, Perú*

*nataliavh84@gmail.com*

*Jose M. Estrada-Grossmann*

*Universidad Peruana de Ciencias Aplicadas, Perú*

*Marcos Saavedra-Velasco*

*Universidad Ricardo Palma, Perú*

*Gian Marco Arango-Rojas*

*Hospital Nacional Edgardo Rebagliati Martínez, Perú*

Acta Médica Peruana vol. 40 núm. 4 329  
333 2023

Colegio Médico del Perú  
Perú

Recepción: 27 Junio 2023  
Aprobación: 01 Febrero 2024

**Abstract:** *Candida* endocarditis is a very serious manifestation of candida infections, and it has increased in incidence over the past years. Of these, *C. parapsilosis* has been described as a cause of endocarditis in native valves of intravenous drug users and prosthetic valves. We report the case of a female that developed a cerebrovascular accident secondary to emboli from aortic prosthetic valve *C. parapsilosis* endocarditis, despite apparently normal echocardiography. She received antifungal therapy without surgical intervention.

**Keywords:** *Candida parapsilosis*, Endocarditis, Echocardiography, Transesophageal, Biofilms, Candidiasis, Invasive.

**Resumen:** La endocarditis por *Candida* spp. es una manifestación muy grave de las infecciones por este patógeno y su incidencia ha ido aumentando en los últimos años. La *Candida parapsilosis* se ha descrito como causa de endocarditis en válvulas nativas de usuarios de drogas intravenosas y prótesis valvulares. Presentamos el caso de una mujer que desarrolló un accidente cerebrovascular secundario a émbolos fúngicos procedentes de una prótesis valvular aórtica infectada por *C. parapsilosis*, a pesar de un ecocardiograma sin vegetaciones. La paciente recibió tratamiento antifúngico sin necesidad de intervención quirúrgica.

**Palabras clave:** *Candida parapsilosis*, Endocarditis, Ecocardiografía Transesofágica, Biopelículas, Candidiasis Invasiva.

## INTRODUCTION

*C. parapsilosis* has been considered a nosocomial pathogen for years, it frequently colonizes skin (it has been isolated in the hands of healthcare professionals) and adheres to synthetic material such as parenteral nutrition lines, intravascular catheters and other prosthetic devices by using biofilms<sup>[1,2]</sup>.

Among fungal endocarditis, *C. parapsilosis* represents the most common non-albican species isolated, and it is known to be an important cause of invasive candidiasis<sup>[2,3]</sup>. Heart valve surgery, intravenous drug consumption, prolonged antibiotic therapy, immunosuppression, previous episodes of endocarditis, and preexisting valve disease, are some of the main predisposing factors for *C. parapsilosis* infective endocarditis (CPIE)<sup>[3,4]</sup>. Of note, the most commonly affected heart tissue is the aortic valve, followed by the mitral and the tricuspid valve; also, in the outbreaks of CPIE, it has been found that intraoperative contamination is the most possible source of infection<sup>[4]</sup>.

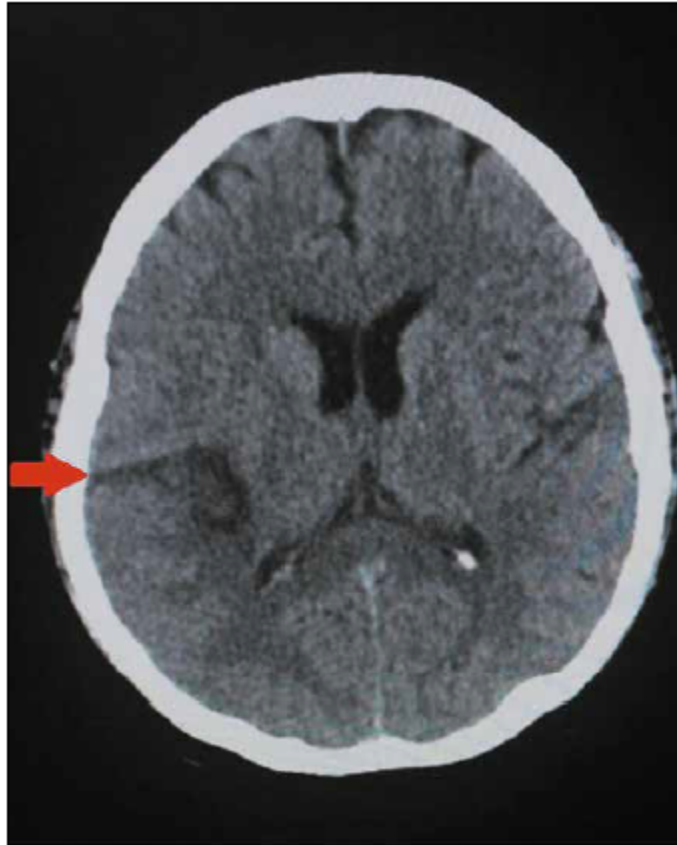
In the literature there are some case reports of CPIE but most of these have imaging evidence of vegetations on the echocardiography. We describe the case of a middle-aged peruvian woman with history of heart valve surgery who presented to the emergency with a cardioembolic event due to a fungal endocarditis despite four echocardiographic procedures without evidence of vegetations or valve lesions. Treatment with high dose echinocandin was successful without the need of surgical intervention.

## CASE REPORT

A 49-year-old female with past medical history of hypertension and severe aortic stenosis with subsequent aortic valve placement by modified Bentall procedure 8 months before, presented to the hospital with a seven-hour history of left arm and left leg numbness plus weakness and dysarthria. She was using warfarin since her prosthetic valve surgery. On admission, she complained of occipital headache and showed left hemiplegia on physical examination; no mental status changes or heart murmurs were auscultated. She was afebrile with a temperature of 36.5°C, a heart rate of 98 beats per minute, blood pressure of 140/90mmHg and respiratory rate of 18 breaths per minute. The brain computed tomography (CT) showed an ischemic stroke in the territory of the right middle cerebral artery (Figure 1), however no atherosclerosis was found on the carotid doppler ultrasound, and the trans-thoracic echocardiography (TTE) did not show vegetations. Additionally, the electrocardiogram was unremarkable.

Her white blood cell count was 5.48 cells/mm<sup>3</sup>, hemoglobin of 11.9 g/dL and she had a normal platelet count of 201 x 10<sup>9</sup>/L. She was subsequently admitted to the neurology ward.

On the third day of hospitalization, she began with daily temperatures of 37.6°C that reached 38.9°C plus episodes



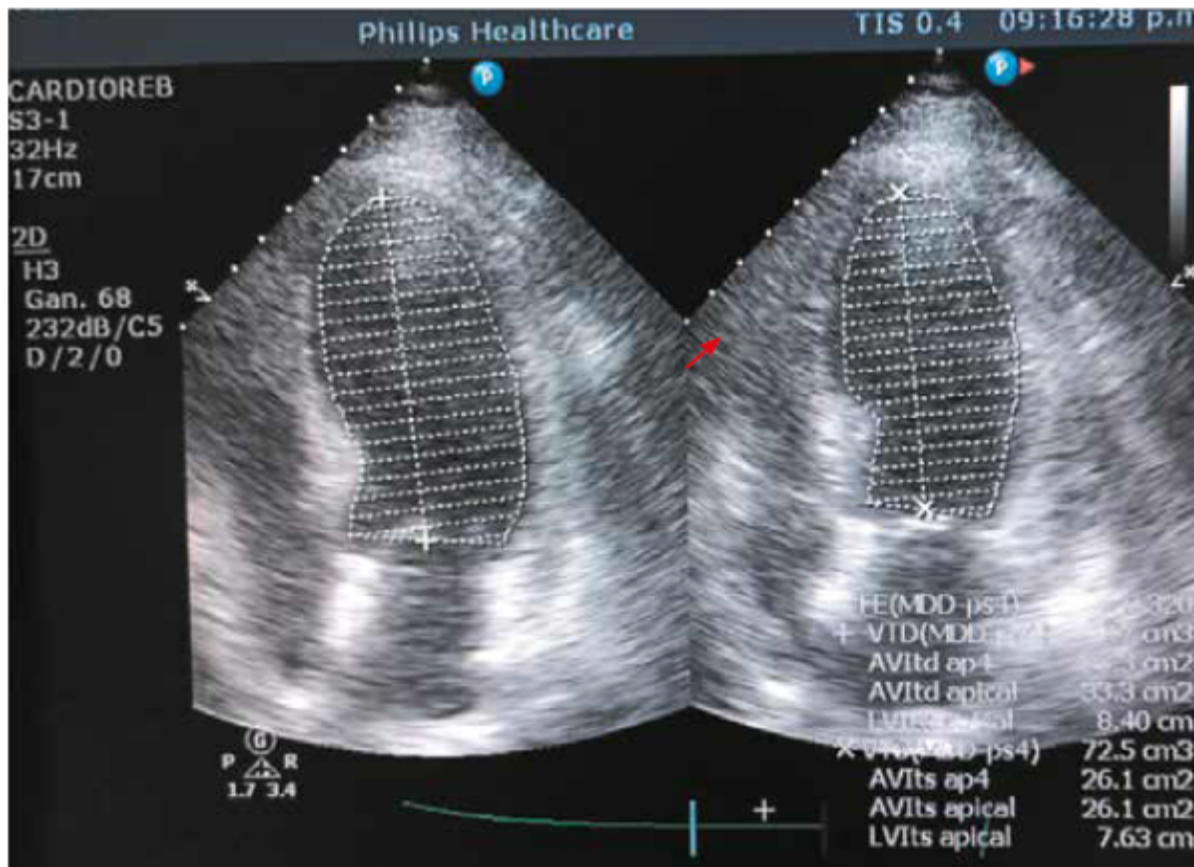
**Figure 1.**

Noncontrast brain computed tomography showing an ischemic lesion hypodense area

of hypotension, she was started on empiric intravenous (IV) Vancomycin 1g/12h. plus Ceftriaxone 2g/day. Her urine analysis and chest radiograph were unremarkable, however she was still febrile, and her third set of blood cultures started growing yeast; the patient was started on IV Fluconazole 200mg/12h. Since a second TTE was normal, a transesophageal echocardiography (TEE) (Figure 2) was performed on the second week of hospitalization given the high suspicion of endocarditis but did not report any cardiac lesions including fistula or dehiscence. Blood cultures pending results confirmed the presence of *C. parapsilosis* in addition, a CT abdomen and eye examination were unremarkable.

During a 2-week period many infectious agents were tested including HBV, HCV, HIV, HTLV, tuberculosis and there were no markers of autoimmune disease. Despite antifungal therapy with IV fluconazole for almost 2 weeks, in which isolated *C. parapsilosis* was

susceptible to all antifungals tested, except to ketoconazole according to the antifungal sensitivity test, MicroScan® (according to the FDA, is an automated system that provides results that are substantially equivalent to the generated using suitable reference methods)<sup>[5]</sup>, the patient remained febrile, presented again episodes of hypotension and her INR reached 5.7. On the third week, in view of a possible interaction between warfarin and fluconazole, this antifungal was switched to Caspofungin 70mg IV as first day loading dose, followed by 50mg/day IV. During that week, the patient did not present fever again, was hemodynamically stable but her new set of blood cultures yielded *C. parapsilosis* once again on the tenth day of Caspofungin therapy. A second TEE was performed searching for fungal vegetations that could explain the persistent fungemia despite the prolonged antifungal therapy, but once again it was unremarkable. Caspofungin dose was increased to 150mg/day IV (invasive candidiasis dose according to the 2016 IDSA guidelines) for 1 week. Control blood cultures repeated daily from day 1 of the high Caspofungin dose were sterile and patient did not develop fever again.



**Figure 2.**  
Transesophageal echocardiography not showing vegetations

She was finally discharged on oral Fluconazole 14 days after her last sterile blood culture, asymptomatic and hemodynamically stable. The patient was scheduled for follow-up in the infectious diseases clinic

## DISCUSSION

The frequency of endocarditis due to *C. parapsilosis* has increased in recent years, this due to its ability to form biofilms which also explains its high mortality<sup>[1]</sup>, and according to the 2023 Duke ISCVIV Criteria, *Candida spp.* is now considered a “typical” infective endocarditis (IE) pathogen in the setting of intracardiac prosthetic material<sup>[6]</sup>.

For a successful outcome, an accurate diagnosis of IE is necessary to provide adequate treatment. In this case, the patient had two positive *C. parapsilosis* blood cultures which constitute a major criterion plus three minor criteria for IE: previous history of prosthetic valve, previous valve repair and fever. This confirmed the diagnosis.

On the other hand, despite having several echocardiographic procedures including TEE (which has high specificity and sensitivity especially in patients with prosthetic valves)<sup>[7]</sup>, no vegetations were identified. This could be explained by the fact that fungal vegetations have a higher incidence of embolic events compared to bacterial endocarditis, and these may have detached before TEE was performed<sup>[8]</sup>. In addition, it has been described that TEE could not confirm or exclude an IE diagnosis in challenging clinical situations such as patients with intracardiac implants<sup>[6]</sup>. In those scenarios, other diagnostic techniques such as cardiac computed tomography (CCT) and/or positron emission computed tomography (PET/CT) should be used in order to improve the identification of IE especially of prosthetic origin <sup>[6]</sup>. In fact, CCT in combination with TEE has higher sensitivity for the detection of both valvular and paravalvular lesions, while PET/CT is preferred to diagnose PVE over echocardiography. Both imaging techniques are included in the 2023 Duke-ISCVID IE Criteria<sup>9</sup>.

Regarding clinical manifestations, common infectious endocarditis signs like heart murmurs may be absent in fungal endocarditis, however *Candida* endocarditis has certain characteristics such as loss of visual acuity or cutaneous nodules. Likewise, the vegetations are large and have a greater tendency to embolize<sup>[7]</sup>. Also, Garzoni in his review of the literature regarding *C. parapsilosis* endocarditis, found that 43.8% of 72 cases presented cerebral thromboembolic events, and he also mentioned that

fever and embolic events should raise the suspicion of infective endocarditis, specially of fungal origin<sup>[9]</sup>. In addition, *Candida spp.* is described in the literature as a cause of cardioembolic strokes and Lipton et al mentioned in their study that when *Candida*



endocarditis is suspected, the rate of spread to the central nervous system can reach up to 80%<sup>[10]</sup>.

The definitive treatment for *Candida* endocarditis is the combination of antifungal therapy and surgery according to the 2016 IDSA candidiasis guidelines and the 2015 American Heart Association infective endocarditis guidelines<sup>[11–13]</sup>. However, it was suggested through a meta-analysis of *Candida* endocarditis, that combined antifungal therapy versus medical-surgical therapy have similar success rate in the specific case of *C. parapsilosis*<sup>[14]</sup>. The ESCAPE study concluded that the induction treatment should be based on Liposomal – Amphotericin followed by fluconazole maintenance therapy to prevent relapses<sup>[15]</sup>. However, other authors consider high dose echinocandins as the preferred options for initial therapy given their better tolerability and exceptional fungicidal activity in the presence of biofilms; this may be an exception for *C. parapsilosis* as it is sometimes resistant to echinocandins<sup>[8,12,16,17]</sup>.

On the physical exam, the patient did not show murmurs and four echocardiograms were unremarkable making the diagnosis challenging. However it is known that in patients with preexisting valvular disease, the detection of vegetations even by TEE can be suboptimal<sup>[17]</sup>. In fact, Hershman-Sarafov described in his retrospective analysis of IE that 44% of the 538 cases were echocardiogram-negative and mostly occurred on damaged valves and elderly patients<sup>[18]</sup>.

Our patient received a long course of IV fluconazole without a good clinical and microbiological response despite fluconazole susceptibility (MIC: 0.12). She started on IV caspofungin, however the blood cultures continued to grow *C. parapsilosis* until the dose was increased to 150mg/day, which is the dose recommended for invasive candidiasis<sup>[11]</sup>. This supports the idea that the patient had an invasive candidiasis (*C. parapsilosis* endocarditis and fungemia) since the specific caspofungin dose for this clinical presentation of candida infection led into a good outcome.

We must conclude that *C. parapsilosis* endocarditis incidence is rising and must be suspected in patients with risk factors such as prosthetic heart valves or valve disease, injection drug use history, indwelling central venous catheters, cancer chemotherapy, prior bacterial endocarditis or low birthweight neonates<sup>[7,19–21]</sup>. Antifungal susceptibility testing should always be performed and negative echocardiographic examinations, including TEE do not rule out infective endocarditis especially in the presence of a prosthetic valve.

## REFERENCES

1. Viehman JA, Clancy CJ, Liu G, Cheng S, Oleksiuk LM, Shields RK, et al. 383. An Increased Rate of *Candida* parapsilosis Infective Endocarditis Is Associated with Injection Drug Use. *Open Forum Infect Dis.* 2018;5(Suppl 1): S148. doi: 10.1093/ofid/ofy210.394.
2. Weems JJ Jr. *Candida* parapsilosis: epidemiology, pathogenicity, clinical manifestations, and antimicrobial susceptibility. *Clin Infect Dis.* 1992 Mar;14(3):756-66. doi: 10.1093/clinids/14.3.756. PMID: 1345554
3. Jain AG, Guan J, D'Souza J. *Candida* parapsilosis: An Unusual Cause of Infective Endocarditis. *Cureus.* 2018 Nov 6;10(11):e3553. doi: 10.7759/cureus.3553. PMID: 30648085; PMCID: PMC6324854.
4. Treviño-Rangel R, González J, Garza Gonzalez E, González G. *Candida* parapsilosis, una amenaza desafiante. *Med Univ.* 2012; 14:155-63.
5. Clinical and Laboratory Standards Institute (CLSI). Performance standards for antimicrobial susceptibility testing, 29th ed, CLSI supplement M100, Wayne, Pennsylvania 2019. <https://www.nih.org.pk/wp-content/uploads/2021/02/CLSI-2020.pdf>.
6. Fowler VG, Durack DT, Selton-Suty C, Athan E, Bayer AS, Chamis Al et al. The 2023 Duke-International Society for Cardiovascular Infectious Diseases Criteria for Infective Endocarditis: Updating the Modified Duke Criteria. *Clin Infect Dis.* 2023 Aug 22;77(4):518-526. doi: 10.1093/cid/ciad271. Erratum in: *Clin Infect Dis.* 2023 Oct 13;77(8):1222. PMID: 37138445; PMCID: PMC10681650.
7. Nguyen MH, Nguyen ML, Yu VL, McMahon D, Keys TF, Amidi M. *Candida* prosthetic valve endocarditis: prospective study of six cases and review of the literature. *Clin Infect Dis.* 1996 Feb;22(2):262-7. doi: 10.1093/clinids/22.2.262.
8. Pasha AK, Lee JZ, Low SW, Desai H, Lee KS, Al Mohajer M. Fungal Endocarditis: Update on Diagnosis and Management. *Am J Med.* 2016 Oct;129(10):1037-43. doi: 10.1016/j.amjmed.2016.05.012.
9. Habib G, Badano L, Tribouilloy C, Vilacosta I, Zamorano JL, Galderisi M et al; Recommendations for the practice of echocardiography in infective endocarditis. *Eur J Echocardiogr.* 2010 Mar;11(2):202-19. doi: 10.1093/ejechocard/jeq004. PMID: 20223755.
10. Garzoni C, Nobre VA, Garbino J. *Candida* parapsilosis endocarditis: a comparative review of the literature. *Eur J Clin Microbiol Infect Dis.* 2007 Dec;26(12):915-26. doi: 10.1007/s10096-007-0386-1.

11. Lipton SA, Hickey WF, Morris JH, Loscalzo J. Candidal infection in the central nervous system. *Am J Med.* 1 de enero de 1984;76(1):101-8. doi: 10.1016/0002-9343(84)90757-5.
12. Pappas PG, Kauffman CA, Andes DR, Clancy CJ, Marr KA, Ostrosky-Zeichner L et al. Clinical Practice Guideline for the Management of Candidiasis: 2016 Update by the Infectious Diseases Society of America. *Clin Infect Dis.* 2016 Feb 15;62(4):e1-50. doi: 10.1093/cid/civ933. Epub 2015 Dec 16. PMID: 26679628; PMCID: PMC4725385.
13. Ahuja T, Fong K, Louie E. Combination antifungal therapy for treatment of *Candida parapsilosis* prosthetic valve endocarditis and utility of T2Candida Panel®: A case series. *IDCases.* 2019;15: e00525. doi: 10.1016/j.idcr.2019.e00525.
14. Baddour LM, Wilson WR, Bayer AS, Fowler VG Jr, Bolger AF, Levison ME et al; Committee on Rheumatic Fever, Endocarditis, and Kawasaki Disease; Council on Cardiovascular Disease in the Young; Councils on Clinical Cardiology, Stroke, and Cardiovascular Surgery and Anesthesia; American Heart Association; Infectious Diseases Society of America. Infective endocarditis: diagnosis, antimicrobial therapy, and management of complications: a statement for healthcare professionals from the Committee on Rheumatic Fever, Endocarditis, and Kawasaki Disease, Council on Cardiovascular Disease in the Young, and the Councils on Clinical Cardiology, Stroke, and Cardiovascular Surgery and Anesthesia, American Heart Association: endorsed by the Infectious Diseases Society of America. *Circulation.* 2005 Jun 14;111(23):e394-434.
15. Steinbach WJ, Perfect JR, Cabell CH, Fowler VG, Corey GR, Li JS, et al. A meta-analysis of medical versus surgical therapy for *Candida* endocarditis. *J Infect.* 2005 Oct;51(3):230-47. doi: 10.1016/j.jinf.2004.10.016.
16. Rivoisy C, Vena A, Schaeffer L, Charlier C, Fontanet A, Delahaye F, et al. Prosthetic Valve *Candida* spp. Endocarditis: New Insights into Long-term Prognosis-The ESCAPE Study. *Clin Infect Dis.* 2018 Mar 5;66(6):825-832. doi: 10.1093/cid/cix913.
17. Ben-Ami R. Treatment of Invasive Candidiasis: A Narrative Review. *J Fungi (Basel)* S. 2018 Aug 16;4(3):97. doi: 10.3390/jof4030097.
18. Arnold CJ, Johnson M, Bayer AS, Bradley S, Giannitsioti E, Miró JM, et al. *Candida* Infective Endocarditis: An Observational Cohort Study with a Focus on Therapy. *Antimicrob Agents Chemother.* 2015 Apr;59(4):2365-73. doi: 10.1128/AAC.04867-14. Epub 2015 Feb 2.
19. Hershman-Sarafov M, Paz A, Potasman I. Echo-Negative Endocarditis: Analysis of 538 Consecutive Transesophageal Echocardiographies.



Open Forum Infect Dis. 2016;3. <https://doi.org/10.1093/ofid/ofw172.808>

20. Pierrotti LC, Baddour LM. Fungal endocarditis, 1995-2000. *Chest*. 2002 Jul;122(1):302-10. doi: 10.1378/chest.122.1.302.
21. Ellis ME, Al-Abdely H, Sandridge A, Greer W, Ventura W. Fungal endocarditis: evidence in the world literature, 1965-1995. *Clin Infect Dis*. 2001 Jan;32(1):50-62. doi: 10.1086/317550.
22. Levy I, Shalit I, Birk E, Sirota L, Ashkenazi S, German B, et al. Candida endocarditis in neonates: report of five cases and review of the literature. *Mycoses*. 2006 Jan;49(1):43-8. doi: 10.1111/j.1439-0507.2005.01183.x.

### Notas de autor

nataliavh84@gmail.com



**Disponible en:**

<https://www.redalyc.org/articulo.oa?id=96678469007>

Cómo citar el artículo

Número completo

Más información del artículo

Página de la revista en redalyc.org

Sistema de Información Científica Redalyc  
Red de revistas científicas de Acceso Abierto diamante  
Infraestructura abierta no comercial propiedad de la  
academia

Natalia Vargas-Herrera, Jose M. Estrada-Grossmann,  
Marcos Saavedra-Velasco, Gian Marco Arango-Rojas  
**Candida parapsilosis endocarditis without vegetations at  
Echocardiography: a case report**  
Endocarditis por Candida parapsilosis sin vegetaciones  
ecocardiográficas: Un reporte de caso

*Acta Médica Peruana*  
vol. 40, núm. 4, p. 329 - 333, 2023  
Colegio Médico del Perú, Perú  
[actamedicaperuana@cmp.org.pe](mailto:actamedicaperuana@cmp.org.pe)

**ISSN:** 1018-8800 / **ISSN-E:** 1728-5917

**DOI:** <https://doi.org/10.35663/amp.2023.404.2662>

**AMP**



**CC BY 4.0 LEGAL CODE**

**Licencia Creative Commons Atribución 4.0 Internacional.**