



RSBO Revista Sul-Brasileira de  
Odontologia

ISSN: 1806-7727

fbaratto1@gmail.com

Universidade da Região de Joinville  
Brasil

Candido Ferreira, Vitor Hugo; Strujak, Guilherme; Carlini, João Luiz  
Tooth alveolus repositioning of impacted canine – case report  
RSBO Revista Sul-Brasileira de Odontologia, vol. 14, núm. 2, abril-junio, 2017, pp. 120-  
123  
Universidade da Região de Joinville  
Joinville, Brasil

Available in: <http://www.redalyc.org/articulo.oa?id=153053120010>

- How to cite
- Complete issue
- More information about this article
- Journal's homepage in redalyc.org

redalyc.org

Scientific Information System

Network of Scientific Journals from Latin America, the Caribbean, Spain and Portugal

Non-profit academic project, developed under the open access initiative

## Case Report Article

# Tooth alveolus repositioning of impacted canine – case report

Vitor Hugo Candido Ferreira<sup>1</sup>  
Guilherme Strujak<sup>2, 3</sup>  
João Luiz Carlini<sup>1, 2</sup>

### Corresponding author:

Vitor Hugo Candido Ferreira  
Rua Roberto Christensen, 75 – B – Portão  
CEP: 80330-270 – Curitiba – Paraná – Brasil  
E-mail: vhcferreira@yahoo.com.br

<sup>1</sup> Department of Dentistry, Federal University of Paraná – Curitiba – PR – Brazil.

<sup>2</sup> Department of Oral and Maxillofacial Surgery, Center for the Care of the Individual with Cleft Lip and Palate– Curitiba – PR – Brazil.

<sup>3</sup> Department of Dentistry, Pontifical Catholic University of Paraná – Curitiba – PR – Brazil.

*Received for publication: April 26, 2017. Accepted for publication: June 13, 2017.*

**Keywords:** impacted tooth; orthodontics; molar.

## Abstract

**Introduction:** Impacted teeth with complete root formation in adult patients is challenging for both the surgeon and orthodontist. Described for more than 40 years and still rarely used, the technique of tooth alveolus repositioning has excellent treatment results in these cases. **Objective:** To report the case of a impacted canine in an adult patient, not responsive to standard surgical orthodontic traction, managed through the technique of tooth alveolus repositioning. **Case report:** Male patient, 28 years old, with presence of tooth #23 impacted and with no success to standard surgical orthodontic traction. To return the tooth in position and function the treatment performed was repositioning the alveolar block. After two years of follow-up the tooth stays in the ideal position, without root resorption and with pulp vitality. **Conclusion:** The tooth alveolus repositioning proved to be a good treatment option, restoring function and esthetics and reaching the expectations of both the patient and professionals.

## Introduction

The importance of permanent teeth in the dental arch is essential to achieve occlusal stability/laterality, and lip projection, directly influencing in function and esthetics [2].

One of the available better suited techniques to carry out the repositioning of impacted teeth is the orthodontic traction through the accessory bonding because of the ease of implementation, positive results, and high predictability [1, 2]. However, for cases in which there is full root formation of the impacted tooth and/or the standard technique is not successful, the treatment options are restricted and little reported, resulting in extraction of impacted tooth and bone loss, which will need rehabilitation treatment to replace the missing tooth [5].

The aim of this paper is to report the case of an impacted maxillary canine with complete root formation, not responsive to orthodontic traction, treated by the technique of tooth alveolus repositioning (tooth and surrounding bone).

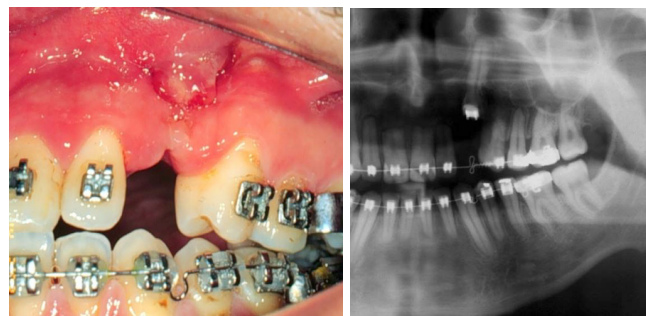
## Case report

Patient A.M.M., male, 28 years-old, with absence of tooth #23. The patient reported three previous unsuccessful attempts of orthodontic traction with intrusion of adjacent teeth and changes in arch shape. Also, technique of forced luxation with aid of traction was tried without success. At radiographic evaluation, tooth #23 was fully included, with complete root formation and consequent suspicion of alveolar ankylosis. The first choice would be the tooth extraction due to the failure of previous attempts and the patient's age. The case was taken under discussion with an orthodontist and we opted for the attempt to reposition through tooth alveolus repositioning (tooth and surrounding bone). The patient was informed regarding the procedure and risks.

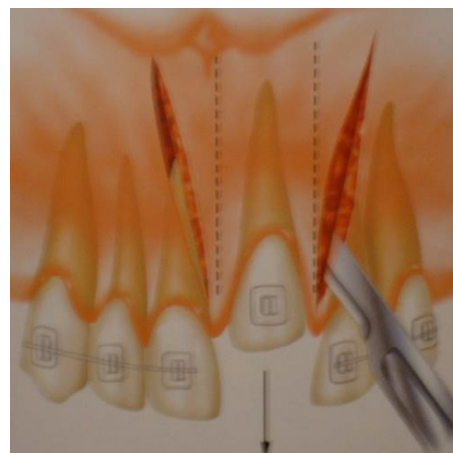
The surgical technique consists of an intrasulcular incision with bilateral relaxing incisions and full flap raising. After exposure of the tooth, osteotomy was carried out preserving at least 2 mm of bone around the tooth, with the aid of a reciprocating saw, fissure Burs (701 or zecrya) or piezo surgery. Next, the tooth alveolus is repositioned at the deal position and stabilized through semi-rigid splinting with thin and flexible orthodontic

wire for 14 days. Stable internal splinting with miniplates and screws is not required. The flap is also apically repositioned, leaving exposed only the coronal portion of the tooth. We highlighted the importance to minimize the trauma on the tooth, especially on the cementum and periodontal ligament, preserving the surrounding bone. After tooth alveolus repositioning, the tooth should be minimally handled and the preparation of the bone bed is performed in such a way that the transplanted tooth remains positioned passively, to avoid possible resorption.

The 24-month following-up revealed tooth vitality without root resorption. The case is shown in the images 1 to 8.

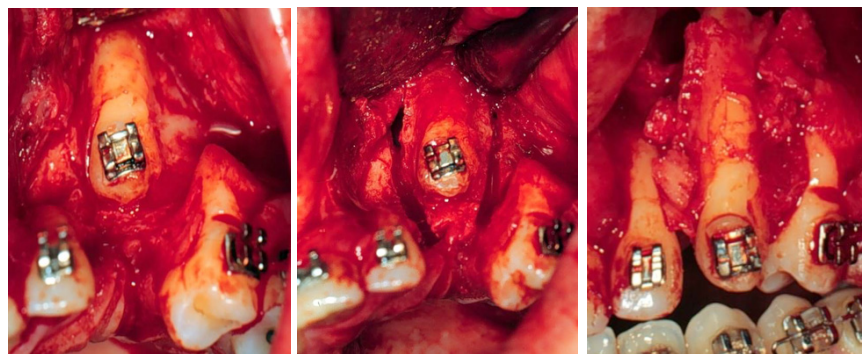


**Figures 1 and 2** – Preoperative clinical and radiographic aspect. Note the presence of the orthodontic accessory used in previous traction attempts and the orthodontically created space for tooth repositioning

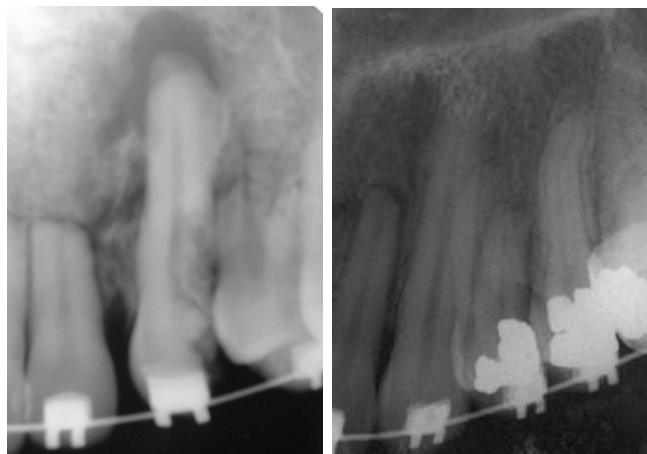


**Figure 3** – Drawing of the incision and osteotomy (dotted line)

Source: Medeiros and Bezerra [3]



**Figures 4-6** – Total exposure of the tooth after full flap raising osteotomy preserving bone around the tooth and tooth alveolus repositioning



**Figures 7 and 8** – Postoperative radiograph after seven days and 24 months

## Discussion

The incidence and frequency of retained teeth are well described in the literature, but the most important thing is to try to maintain their function and use in dental arch. We emphasize that this is a decision which should be taken together with the orthodontist, surgeon, and patient.

Sherwood [8] defines impacted tooth as the tooth that cannot erupt, not reaching the position on tooth arch within the expected time. The most common impacted teeth are the maxillary and mandibular third molars, followed by the maxillary canines and mandibular premolars [2, 6-8].

Among the causes of impaction, two theories are widely discussed and accepted in the literature, one genetic and other environmental [8]. The environmental factors include size discrepancy of the arches, prolonged retention of primary teeth, abnormal position of the dental buds, severe

crowding of the permanent teeth, root dilaceration, cysts and tumors, and nutritional and endocrine disorders [1, 2, 7].

In the literature, the technique of orthodontic accessory bonding with later traction offers the best result and it is considered the gold standard for the management of retained teeth [1, 2, 7]. Described by Shapira [7], the technique consists in bonding orthodontic accessory on the crown, resulting in a more conservative surgery with less extensive osteotomies, favoring a faster healing and preventing periodontal problems.

However, for adult patients and cases in which there is complete root formation, the traction technique does not offer satisfactory results, resulting in tooth extraction [4]. An option for these cases is the apicectomy technique associated with the conventional orthodontic-surgical traction [5], but this technique has low predictable results and need further endodontic monitoring.

The tooth alveolus repositioning is then a better choice. Described by Moss [4] in 1968, tooth alveolus repositioning offers flexibility to the management of impacted teeth and good prognosis. In a study with 31 teeth repositioned by this technique, Sagne *et al.* [6] showed success in all cases, with complete bone regeneration and formation of sound attached gingiva around all teeth.

We highlighted the importance to minimize the trauma on the tooth, especially on the cementum and periodontal ligament, preserving the surrounding bone. After tooth alveolus repositioning, the tooth should be minimally handled and the preparation of the bone bed is performed in such a way that the transplanted tooth remains positioned passively, to avoid possible resorption. Medeiros and Bezerra [3] also point out that, when the tooth has an exposed crown, the bone displacement is performed only

in the region of sutures, not to compromise the blood supply.

It is worth mentioning that the technique offers satisfactory results for the traction of the maxillary anterior teeth [3, 4, 6]. However, the tooth alveolar repositioning is not indicated for cases of mandibular impaction because of the high risk of necrosis of the tooth alveolus block [3].

Another advantage of the technique is the application of orthodontic forces in a short time after the surgery. The canine will not be completely immobilized by the orthodontic appliance and that possibility of orthodontic movement can stimulate the formation of new bone [6]. In addition, the fact of the dental crown is exposed makes oral hygiene ease, thus reducing the risk of infection.

With respect to the period of splinting, based on our experience, we opted for semi-rigid splinting to facilitate the orthodontic treatment with more satisfactory results.

Moss [4] and Sagne *et al.* [6] recommend performing endodontic treatment after two to four weeks of the completion of the surgery. However, in this case report, we opt to follow-up the tooth, which has pulpal vitality so far.

## Conclusion

The management of retained teeth with complete root formation in adult patients is challenging both for the surgeon and orthodontist. Orthodontic movement in this case needs caution regarding the adjacent teeth. In this present case report, the tooth alveolus repositioning proved to be an effective treatment option, restoring function and esthetics

and reaching the expectations of both the patient and professionals.

## References

1. Beadnell SW. Management of the impacted canine. *Current Therapy In Oral and Maxillofacial Surgery*. 2012;135-45.
2. Becker A, Chaushu S. Surgical treatment of impacted canines: what the orthodontist would like the surgeon to know. *Oral Maxillofacial Surg Clin N Am*. 2015;27:449-58.
3. Medeiros PJ, Bezerra AR. Treatment of an ankylosed central incisor by single-tooth dento-osseous osteotomy. *Am J Orthod Dentofac Orthop*. 1997;112:496.
4. Moss JP. Autogenous transplantation of maxillary canines. *J Oral Surg*. 1968;26:775-83.
5. Puricelli E. Treatment of impacted canine by apicoetomy. *Rev Gaúcha Odont*. 1987;35(4): 326-30.
6. Sagne S, Lennartsson B, Thilander B. Transalveolar transplantation of maxillary canines: an alternative to orthodontic treatment in adult patients. *Am J Orthod Dentofac Orthop*. 1986;90:149-57.
7. Shapira Y. The maxillary canine – surgical considerations and management. *Quintessence Int*. 1984;15(7):895-921.
8. Sherwood K. Evidence-based surgical-orthodontic management of impacted teeth. *Atlas Oral Maxillofac Surg Clin N Am*. 2013;21:199-210.