



Acta Scientiarum. Biological Sciences

ISSN: 1679-9283

eduem@uem.br

Universidade Estadual de Maringá  
Brasil

de Melo Tavares Vieira, Kátia Cristina; Alves Favareto, Ana Paula  
Experimental exposure to 3-monochloropropane-1,2-diol from the pre-puberty causes  
damage in sperm production and motility in adulthood  
Acta Scientiarum. Biological Sciences, vol. 39, núm. 2, abril-junio, 2017, pp. 235-242  
Universidade Estadual de Maringá  
Maringá, Brasil

Available in: <http://www.redalyc.org/articulo.oa?id=187151312011>

- How to cite
- Complete issue
- More information about this article
- Journal's homepage in redalyc.org

redalyc.org

Scientific Information System

Network of Scientific Journals from Latin America, the Caribbean, Spain and Portugal

Non-profit academic project, developed under the open access initiative



## Experimental exposure to 3-monochloropropane-1,2-diol from the pre-puberty causes damage in sperm production and motility in adulthood

Kátia Cristina de Melo Tavares Vieira and Ana Paula Alves Favareto\*

*Programa de Pós-graduação em Meio Ambiente e Desenvolvimento Regional, Universidade do Oeste Paulista, Rodovia Raposo Tavares, km 572, 19067-175, Presidente Prudente, São Paulo, Brazil. \*Author for correspondence. E-mail: anafavareto@unoeste.br*

**ABSTRACT.** 3-Monochloropropane-1,2-diol (3-MCPD) is a food contaminant that can be formed during the thermic processing of various foodstuffs. Studies of reproductive toxicology of 3-MCPD are mainly concentrated in the evaluation of possible insults caused by exposure of adult animals. However, the prepuberty might be a period of different susceptibility to chemicals. The aim of this study was to evaluate the effects on reproductive endpoints of the 3-MCPD-exposure prepubertal male rats. Wistar male rats were assigned to 4 groups: control and exposed to 2.5; 5 or 10 mg kg<sup>-1</sup> day<sup>-1</sup> of 3-MCPD for 30 days by gavage. Testis and epididymis were used for sperm counts and histology analysis. Sertoli cell number and dynamic of the spermatogenesis were evaluated. Sperm were collected from the vas deferens for evaluation of the sperm motility and morphology. Number of sperm with progressive movement, number of Sertoli cells and germ cells and relative daily sperm production were decreased in the groups exposed to 5 and 10 mg kg<sup>-1</sup> day<sup>-1</sup> of 3-MCPD. Sperm morphology, testicular and epididymal histology were comparable among groups. Results show that 3-MCPD-exposure of rats from prepuberty might cause alterations in spermatogenesis and sperm maturation, similarly to exposure in adulthood.

**Keywords:** monochloropropanol, puberty, rats, spermatogenesis, reproduction.

## Exposição experimental ao 3-monocloropropano-1,2-diol, a partir da pré-puberdade, causa alteração na produção e motilidade espermática na idade adulta

**RESUMO.** 3-monocloropropano-1,2-diol (3-MCPD) é um contaminante alimentar formado durante o processamento térmico de vários produtos. Estudos de toxicologia reprodutiva do 3-MCPD estão concentrados principalmente na avaliação de danos causados pela exposição de animais adultos. No entanto, a peri-puberdade pode ser um período de susceptibilidade diferente a produtos químicos. O objetivo deste estudo foi avaliar os efeitos reprodutivos da exposição de ratos machos pré-púberes ao 3-MCPD. Ratos Wistar machos foram divididos em quatro grupos: controle e expostos a 2,5; 5 ou 10 mg kg<sup>-1</sup> dia<sup>-1</sup> de 3-MCPD durante 30 dias, por gavagem. Os testículos e epidídimos foram usados para contagem espermática e análise histológica. Foram avaliados o número de células de Sertoli e a dinâmica da espermatogênese. Espermatozoides foram coletados a partir dos ductos deferentes para avaliação da motilidade e morfologia. O número de espermatozoides com movimento progressivo, o número de células de Sertoli e de células germinativas e a produção espermática foram reduzidos nos grupos expostos a 5 e 10 mg kg<sup>-1</sup> dia<sup>-1</sup> de 3-MCPD. A morfologia espermática e histologia testicular e epididimária foram semelhantes entre os grupos. Os resultados mostram que a exposição de ratos ao 3-MCPD, a partir da pré-puberdade, pode causar alterações na espermatogênese e na maturação espermática, de forma semelhante à exposição na idade adulta.

**Palavras-chave:** monocloropropanol, puberdade, ratos, espermatogênese, reprodução.

### Introduction

3-Monochloropropane-1,2-diol(3-MCPD) is a well-known food contaminant, and has been detected in processed foods, including cereals, coffee, fish, meat products, dairy products, soy sauce based on acid hydrolyzed vegetable protein (Baer, De La Calle, & Taylor, 2010). This compound can be found as free form or esterified with long-chain

fatty acids (Zelinkova, Svejková, Velíšek, & Dolezal, 2006, Fu et al., 2007).

The exact mechanism of 3-MCPD formation is still unknown (Rahn & Yaylayan, 2011). However, the compound may be formed during thermic processing, as a reaction product of triacylglycerols, phospholipids or glycerol and hydrochloric acid in fat-based or fat-containing foods, and refinement

process in vegetable fats and oils (Jędrkiewicz, Kupka, Głowacz, Gromadzka, & Namieśnik, 2016). Moreover, domestic processing (e.g. grilling and toasting) and the migration from coating materials treated with epichlorohydrin also can increase the 3-MCPD levels in foods (Crews, Brereton, & Davies, 2001, Hamlet & Sadd, 2009).

The maximum tolerable daily intake of the 3-MCPD is  $2 \mu\text{g kg}^{-1} \text{bw day}^{-1}$ . According its food occurrence and consumption, the exposure calculated of the compound for general population might range  $0.02 - 0.7 \mu\text{g kg}^{-1} \text{bw day}^{-1}$ . However, high consumers might ingest of  $0.06$  to  $2.3 \mu\text{g kg}^{-1} \text{bw day}^{-1}$  of 3-MCPD (Food and Agriculture Organization [FAO] & World Health Organization [WHO], 2007).

The presence of this contaminant in the diet raises concerns for the risks it may pose to health, due potential carcinogenic, effect possibly mediated by mechanisms involving either hormonal disturbances or cytotoxicity (Robjohns, Marshall, Fellows, & Kowalczyk, 2003). Moreover, Cho et al. (2008) indicate kidneys, testis and ovary as potential targets of the 3-MCPD toxicity.

3-MCPD has been associated to reproductive impact in adult rats (Sun et al., 2013, Sawada et al., 2015), but the effects of the exposure from the prepubertal period are unknown. Spermatogenesis and steroidogenesis are not yet fully established during prepuberty, which in rat occurs at postnatal day 36-55 or 60 (Clegg, 1960, Ojeda, Andrews, Advis, & White, 1980). This phase of the postnatal sexual development has been related as a critical period and more susceptible to reproductive impairment caused by chemical agents (Johnson, Welsh, & Wilker, 1997). That is why the possible reproductive insults caused by exposure in prepuberty should be particularly investigated (Perobelli, 2014).

Children and adolescents may be more exposed to the 3-MCPD than the adults (Li, Nie, Zhou, & Xie, 2015). Thus, the aim of this study was to evaluate the effects on reproductive endpoints of the 3-MCPD-exposure from the prepuberty. For this, testicular and epididymal histology and sperm parameters were analyzed, using the reproductive tract of Wistar rats as the experimental model.

## Material and methods

### Animals

Male (45 days old,  $n = 40$ ) Wistar rats supplied by the Central Vivarium of Unoeste – *Universidade do Oeste Paulista* – were housed in the Vivarium of Experimentation at the Unoeste. During the

experiment, animals were allocated into polypropylene cages ( $43 \times 30 \times 15 \text{ cm}$ ) with laboratory-grade pine shavings as bedding. Rats were maintained under controlled temperature ( $23 \pm 1^\circ\text{C}$ ) and lighting conditions (12L, 12D photoperiod). Rat chow and filtered tap water were provided *ad libitum*. The experimental protocol followed the Ethical Principles in Animal Research of the Brazilian College of Animal Experimentation and was approved by the Ethics Committee for Use of Animals at the Unoeste (Protocol # 2055-CEUA).

### Experimental design and treatment

The study was conducted according to the experimental design described below. Rats were randomly assigned into four experimental groups. Control animals ( $n = 10$ ) received vehicle (saline solution 0.9%), for 30 days by gavage. Rats from the 3-MCPD groups ( $n = 10 \text{ group}^{-1}$ ) received 2.5 (treated A – TA); 5 (treated B – TB) or  $10 \text{ mg kg}^{-1} \text{bw day}^{-1}$  (treated C – TC) of 3-MCPD (Sigma Chemical CO, St. Louis, U.S.A.) diluted in saline solution 0.9%, for 30 days by gavage. Rats were weighed three times for week and had your daily intake estimated ration (in g) and water (in milliliter). In addition, clinical signs of toxicity were observed.

### Organs collection

At the end of treatment rats from each experimental group were euthanized with sodium thiopental ( $100 \text{ mg kg}^{-1}$ ), by intraperitoneal administration.

The right testis, epididymis and vas deferens, ventral prostate, seminal vesicle (without the coagulating gland and full of secretion), liver, kidneys and pituitary were removed and their weights (absolute and relative to body weights) were determined.

### Sperm analysis

Immediately after euthanasia, the left vas deferens was collected and spermatozoa were obtained with the aid of a syringe and needle, through internal rinsing with 1.0 mL of PBS solution at  $34^\circ\text{C}$ . Warmed Newbauer chamber was loaded with a small aliquot of sperm solution. Sperm motility evaluation was performed by the same person throughout the study and was assessed by visual estimation (200 spermatozoa per animal, in duplicate) under a phase-contrast microscope (Leica DMLS) at 200X magnification. Spermatozoa were classified as: immotile, motile without progression and motile with progressive movement. With the aid

of a syringe and needle, sperm were removed from the right vas deferens through internal rinsing with 1.0 mL of buffered formalin. Sperm morphology analysis was performed according to Seed et al. (1996) and abnormalities were classified according to Filler (1993).

Right testes were decapsulated and caput/corpus and cauda segments of right epididymis were separated. Homogenization-resistant testicular spermatids (stage 19 of spermiogenesis) and sperm in the caput/corpus epididymis and cauda epididymis were assessed as described previously by Robb, Amann, and Killian (1978), with adaptations of Fernandes et al. (2007). To calculate daily sperm production (DSP) the number of spermatids was divided by 6.1 (number of days that these cells are present in the seminiferous epithelium). The sperm transit time through the epididymis was determined by dividing the number of sperm in each portion by DSP.

#### Histological procedures and quantitative analysis of spermatogenesis

The left testis and epididymis were collected and fixed in buffered formalin (10%) for 24 hours. After this period, these organs were sectioned and returned to the buffered formalin for additional 24 hours. The pieces were embedded in paraffin wax and sectioned at 5  $\mu$ m. The sections used for histological evaluation were stained with hematoxylin and eosin (HE), Periodic acid-Schiff (PAS) and Masson's trichrome and examined by light microscopy.

One hundred random tubular sections per animal ( $n = 10$  animals group<sup>-1</sup>) in three nonconsecutive testis cross-sections were classified into four categories, according to the type of germ cell present. The groups of stages I-VI (one spermatids generation), VII-VIII (spermatozoa), IX-XIII (two generations of spermatids) and XIV (secondary spermatocyte) of the seminiferous epithelium cycle (Leblond & Clemont, 1952) were identified under a light microscope (Leica DMLS) at  $\times 200$  magnification.

Nucleus of Sertoli cells and germ cells (spermatogonia type A, pachytene primary spermatocyte and round spermatid) were counted in 20 seminiferous tubules per rat ( $n = 10$  animals group<sup>-1</sup>) at stage VII of spermatogenesis, under a light microscope (Leica DMLS), at  $\times 400$  magnification. The number was corrected for nucleolus/nucleus size and section thickness, according to Abercrombie (1946).

#### Statistical analysis

Statistical analyses were conducted by the ANOVA, with *a posteriori* Tukey test or nonparametric Kruskal-Wallis test, with *a posteriori* Dunn test, according to the characteristics of each variable. The results were expressed as mean  $\pm$  standard deviation (SD) or median and quartile 1 and 3 (Q1/Q3). Differences were considered significant when  $p < 0.05$ .

#### Results and discussion

There was no statistical difference ( $p > 0.05$ ) in the body weight among experimental groups (Table 1) during the treatment period. The feed intake and water consumption were affected by the 3-MCPD-exposure only at the end of the treatment period (data not shown). On the 27 and 30<sup>th</sup> of exposure, there was an increase ( $p < 0.05$ ) of the feed intake in the TA group compared to the control group. It was also observed difference ( $p < 0.05$ ) between the TA and TB groups on the 27<sup>th</sup> day of treatment. On the 30<sup>th</sup> day of treatment, there was a lower ( $p < 0.05$ ) water consumption in the TC group compared to the TA group, but not in relation to other experimental groups.

The absolute and relative weights of reproductive organs, pituitary, liver and kidneys are shown in Table 1. Significant augmentation ( $p < 0.01$ ) in the absolute weight of the kidneys in rats from TC group in comparison to the control group was observed. However, relative weight of this organ was similar among experimental groups. The weight of the vas deferens was increased ( $p < 0.05$ ) in TA group, when compared to control group.

Sperm number per gram of testis and daily sperm production per gram of testis were significantly reduced ( $p < 0.05$ ) in TC and TB groups, when compared to control and TA groups, respectively (Table 2). Nevertheless, sperm number in the caput/corpus epididymis, epididymal transit time and sperm morphology were similar among experimental groups (Table 2). The number of sperm with progressive movement was significantly decreased ( $p < 0.05$ ) so that, consequently, the percentage of immotile sperm was increased ( $p < 0.05$ ) in the TB and TC groups in relation to control group (Figure 1).

Histopathological analysis of testis and epididymis from rats exposed to 3-MCPD showed that the morphological structures of the seminiferous tubules, interstitial tissue (Leydig cells) and different regions of the caput, corpus and cauda of the epididymis were similar to those of control, indicating the absence of pathological changes (Figure 2).

**Table 1.** Final body weight and reproductive organ weights of rats from control and treated with 2.5 (TA), 5 (TB) and 10 mg kg<sup>-1</sup> day<sup>-1</sup> (TC) of 3-MCPD groups.

	Control	TB	TA	TC
Final body weight (g)	289.33 ± 38.99a	317.50 ± 24.08a	306.57 ± 23.53a	319.76 ± 18.91a
Absolute weights				
Testis (g)	1.50 ± 0.09a	1.57 ± 0.15a	1.58 ± 0.12a	1.61 ± 0.12a
Epididymis (mg)	502.30 ± 45.30a	536.30 ± 77.87a	495.30 ± 34.34a	499.78 ± 50.04a
Vasdeferens (mg)	111.40 ± 17.86a	137.70 ± 29.35bc	126.10 ± 10.53ac	112.56 ± 17.28ac
Ventral prostate (mg)	424.10 ± 131.88a	461.00 ± 97.07a	432.40 ± 107.39a	387.33 ± 79.78a
Full seminal vesicle (g)	663.40 ± 286.15a	826.50 ± 167.37a	693.60 ± 229.15a	618.00 ± 263.91a
Empty seminal vesicle (mg)	389.70 ± 140.00a	520.20 ± 46.20a	459.10 ± 151.44a	371.00 ± 160.94a
Pituitary (mg)	6.00 ± 1.55a	5.50 ± 1.12a	4.90 ± 1.58a	5.89 ± 2.18a
Liver (g)	11.92 ± 2.69a	13.07 ± 1.92a	12.08 ± 2.21a	13.19 ± 2.35a
Kidney (right) (g)	1.13 ± 0.38a	1.38 ± 0.17ab	1.33 ± 0.14ab	1.52 ± 0.14bc
Kidney (left) (g)	1.23 ± 0.20a	1.40 ± 0.17ab	1.30 ± 0.14ab	1.51 ± 0.18bc
Relative weights				
Testis (g 100 g <sup>-1</sup> )	0.52 ± 0.06a	0.49 ± 0.04a	0.52 ± 0.05a	0.50 ± 0.02a
Epididymis (mg 100 g <sup>-1</sup> )	57.84 ± 8.13a	60.09 ± 7.16a	62.10 ± 5.51a	64.49 ± 6.23a
Vasdeferens (mg 100 g <sup>-1</sup> )	263.42 ± 36.35a	241.53 ± 56.37a	244.42 ± 22.63a	290.92 ± 48.13a
Ventral prostate (mg 100 g <sup>-1</sup> )	73.99 ± 21.42a	71.31 ± 12.49a	75.20 ± 18.01a	85.41 ± 15.82a
Full seminal vesicle (g 100 g <sup>-1</sup> )	54.72 ± 29.34a	40.26 ± 9.89a	48.78 ± 15.17a	49.21 ± 12.04a
Empty seminal vesicle (mg 100 g <sup>-1</sup> )	83.87 ± 31.29a	61.35 ± 5.45a	73.82 ± 23.50a	82.44 ± 20.82a
Pituitary (mg 100 g <sup>-1</sup> )	2.10 ± 0.60a	1.75 ± 0.40a	1.60 ± 0.50a	1.85 ± 0.71a
Liver (g 100 g <sup>-1</sup> )	4.09 ± 0.55a	4.12 ± 0.56a	3.93 ± 0.58a	4.10 ± 0.57a
Kidney (right) (g 100 g <sup>-1</sup> )	0.39 ± 0.12a	0.44 ± 0.04a	0.43 ± 0.04a	0.47 ± 0.03a
Kidney (left) (g 100 g <sup>-1</sup> )	0.42 ± 0.03a	0.44 ± 0.05a	0.42 ± 0.04a	0.47 ± 0.04a

Values expressed as mean ± S.D. ANOVA with *a posteriori* Tukey test. Different letters indicate statistically significant difference (*p* < 0.05).

**Table 2.** Sperm parameters of rats from control and treated with 2.5 (TA), 5 (TB) and 10 mg kg<sup>-1</sup> day<sup>-1</sup> (TC) of 3-MCPD groups.

Parameter	Control	TA	TB	TC
<sup>a</sup> Sperm counts and epididymal transit				
Sperm number per testis (x 10 <sup>6</sup> )	179.24 ± 23.71a	159.66 ± 18.83a	166.53 ± 15.76a	164.48 ± 13.93a
Sperm number per gram of testis (x 10 <sup>6</sup> g <sup>-1</sup> )	144.97 ± 16.45ac	145.03 ± 18.08a	124.56 ± 18.80bc	118.79 ± 12.18b
Daily sperm production (x 10 <sup>6</sup> testis <sup>-1</sup> )	29.38 ± 3.89a	26.71 ± 3.09a	27.30 ± 2.58a	26.96 ± 2.28a
Relative daily sperm production (x 10 <sup>6</sup> per g <sup>-1</sup> testis <sup>-1</sup> )	23.77 ± 2.70ac	23.77 ± 2.96a	20.42 ± 3.08bc	19.47 ± 2.00b
Sperm number in the caput/corpus epididymis (x 10 <sup>6</sup> )	92.26 ± 15.01a	92.39 ± 14.36a	81.08 ± 13.13a	82.05 ± 16.10a
Sperm number per gram of caput/corpus epididymis (x 10 <sup>6</sup> )	337.57 ± 22.36a	325.24 ± 29.13a	330.18 ± 20.26a	314.30 ± 18.35a
Sperm transit time in the caput/corpus (days)	3.18 ± 0.63a	3.55 ± 0.48a	2.97 ± 0.37a	3.06 ± 0.64a
Sperm number in the cauda epididymis (x 10 <sup>6</sup> )	184.67 ± 27.62a	205.70 ± 42.03a	197.06 ± 26.21a	194.18 ± 23.68a
Sperm number per gram of cauda epididymis (x 10 <sup>6</sup> )	806.25 ± 30.62a	819.38 ± 40.01a	787.50 ± 41.14a	805.56 ± 45.23a
Sperm transit time in the cauda (days)	6.42 ± 1.45a	7.99 ± 2.10a	7.28 ± 1.17a	7.22 ± 0.88a
<sup>b</sup> Sperm morphology				
Normal sperm (%)	91.75 (89.50 – 93.25)a	90.00 (86.12 – 94.37)a	92.75 (89.12 – 94.00)a	90 (86.50 – 92.00)a
Morphological abnormalities of the sperm head (%)	5.5 (4.62 – 6.37)a	5.5 (3.87 – 10.12)a	5.75 (4.12 – 7.62)a	8.00 (6.00 – 9.50)a
Morphological abnormalities of the flagellum (%)	2.00 (1.25 – 3.75)a	3.00 (2.00 – 4.37)a	1.50 (1.00 – 2.87)a	2.50 (2.00 – 3.50)a

<sup>a</sup>Values expressed as mean ± S.D. ANOVA with *a posteriori* Tukey test. <sup>b</sup>Values expressed as median (Q1 – Q3). Kruskal–Wallis test, with *a posteriori* Dunn test. Different letters indicate statistically significant difference (*p* < 0.05).

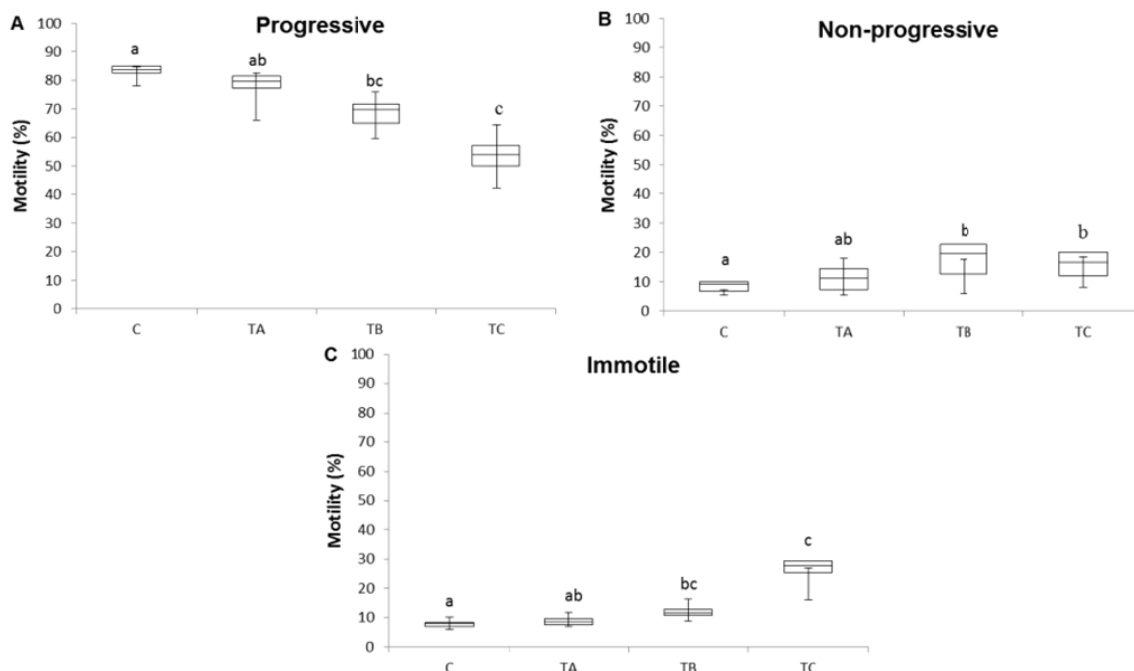
The stages of spermatogenesis were not significantly affected by different doses of 3-MCPD exposure (Table 3). On the other hand, the number of Sertoli cells and germ cells was lower in the TB and TC groups, when compared to control and TA groups (Table 3).

3-MCPD is a food contaminant found in various foods that are part of daily diet. Experimental studies with adult rodents have shown toxic effects of this compound, especially on the urinary and reproductive systems (Cho et al., 2008, Bakhiya, Abraham, Gürtler, Appel, & Lampen, 2011, Kim et al., 2014). However, the reproductive studies caused by exposure from prepubertal phase, which could have a relevant exposure, are scarce.

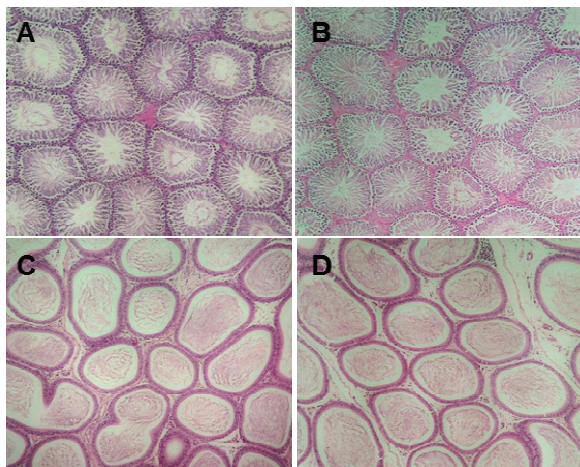
Although the levels of exposure to food contaminated by 3-MCPD is not high for the general population, the growing consumption of some foods, such as frozen meals, which have

higher levels of the contaminant, raise a concern (Arisseto, Vicente, Furlani, & Toledo, 2013). Furthermore, the presence of this compound in infant formulas and breast milk (Zelinková et al., 2008, Wöhrlin, Fry, Lahrssen-Wiederholt, & Preiß-Weigert, 2015) also indicates the need for further toxicological research in this area.

The assessment of body weight and nutritional status is extremely important to obtain information on the overall health of the animals exposed to chemicals (Clegg, Perreault, & Klinefelter, 2001). The reproduction is often one of the first functions to be affected when there is inadequate nutrition and loss body weight (Krasnow & Steiner, 2006). Thus, the analysis of these parameters is essential to interpretation of the effects of chemicals on the reproductive system. In the current study, final body weight of rats from different experimental groups was similar; corroborating study of Onami et al. (2014).



**Figure 1.** Sperm motility of rats from control (C) and exposed to 3-MCPD groups (TA = 2.5, TB = 5, and TC = 10 mg kg<sup>-1</sup> day<sup>-1</sup>). Values expressed as median (Q1 – Q3). Kruskal–Wallis test, with *a posteriori* Dunn test. Different letters indicate statistically significant difference ( $p < 0.05$ ).



**Figure 2.** Photomicrographs of testis sections from control (A) and 3-MCPD (2.5 mg kg<sup>-1</sup> day<sup>-1</sup> - B) groups and epididymis sections from control (C) and 3-MCPD (5 mg kg<sup>-1</sup> day<sup>-1</sup> - D) groups. Observe the absence of pathological changes. 100x. H & E stain.

Similarly food intake also were unaffected by 3-MCPD as observed by Yamada, Inoue, Sato, Yamagishi, and Sato (1995). However, Cho et al. (2008) observed decrease in the body weight of adult B6C3F1 mice, only after nine (female) and twelve (male) weeks of exposure to 400 ppm of 3-MCPD (approximately 76.79 mg kg<sup>-1</sup>). The absence of change in body weight of the animals indicates that the observed reproductive impact is result of the

direct action of the 3-MCPD and not a secondary effect of the systemic toxicity.

The kidney is a toxicity target for 3-MCPD (Lynch, Bryant, Hook, Nestmann, & Munro, 1998). The increase of the absolute weight of kidneys observed in TC group is concordant with nephrotoxicity related by several studies (Cho et al., 2008, Sawada et al., 2015). Renal tubular hyperplasia was observed after chronic exposure to 3-MCPD in rats (Hwang, Yoon, Kim, Jang, & Yoo, 2009). Onami et al. (2014) also observed increase in absolute and relative kidney weight after exposure of F344 gpt delta rats to 3-MCPD. After subchronic exposure to 36.97 and 76.79 mg kg<sup>-1</sup> of 3-MCPD in male mice, Cho et al. (2008) observed increase in relative weight of kidneys. This change was accompanied by interstitial nephritis, basophilic tubules and mineralization of the kidneys, but there was no statistically significant impact. In spite absence of histopathological lesions, proteome alterations associated to metabolic pathways may be found in this organ (Sawada et al. 2015).

As reported by Yamada et al. (1995), weights of reproductive organs were similar in the experimental groups. Kim et al. (2012) also observed no change in reproductive organ weights, with exception of increase in the absolute weight of epididymis (30 mg kg<sup>-1</sup> be day<sup>-1</sup> of 3-MCPD for 7 days).

**Table 3.** Stages of spermatogenesis and Sertoli cells and germ cells number in rats from control and treated with 2.5 (TA), 5 (TB) and 10 mg kg<sup>-1</sup> day<sup>-1</sup> (TC) of 3-MCPD groups.

Parameter	Control	TA	TB	TC
<sup>a</sup> Stages of spermatogenesis				
I-VI	46.50 (45.25-47.75)a	45.00 (43.25-46.00)a	46.00 (45.00-46.00)a	46.00 (44.0-47.00)a
VII-VIII	26.50 (26.00-27.00)a	25.50 (24.25-26.75)a	26.50 (26.00-27.00)a	26.00 (25.00-26.00)a
IX-XIII	22.50 (22.00-24.00)a	24.00 (24.00-25.50)a	23.50 (23.00-24.75)a	24.00 (23.00-24.00)a
XIV	3.50 (2.25-5.00)a	5.00 (4.25-5.75)a	4.50 (4.00-5.75)a	5.00 (4.00-6.00) a
<sup>b</sup> Cell counts				
Sertoli cell	11.75 ± 2.30a	11.60 ± 2.37a	10.83 ± 2.04b	10.49 ± 1.96b
Spermatogonia type A	9.28 ± 1.62a	9.22 ± 1.64a	8.13 ± 1.15b	7.60 ± 1.14b
Pachytene spermatocyte	48.61 ± 3.74a	49.03 ± 2.34a	45.97 ± 2.59b	45.31 ± 2.38b
Round spermatid	147.11 ± 4.33a	148.24 ± 2.83a	143.53 ± 3.84b	142.66 ± 3.01b

<sup>a</sup>Values expressed as median (Q1 – Q3). Kruskal–Wallis test, with *a posteriori* Dunn test. <sup>b</sup>Values expressed as mean ± S.D. ANOVA with *a posteriori* Tukey test. Different letters indicate statistically significant difference (*p* < 0.05).

Sperm parameters were impaired by 3-MCPD exposure. Sperm number per gram of testis and daily sperm production per gram of testis were significantly reduced in the rats from groups exposed to higher doses of food contaminant (5 and 10 mg kg<sup>-1</sup> bw day<sup>-1</sup>). These data corroborate with the reduction of the germ cells number observed. However, Kim et al. (2012) related that the exposure of adult rats (3, 10, and 30 mg kg<sup>-1</sup> bw day<sup>-1</sup> 3-MCPD for 7 days) no caused changes in the number of sperm head in the testis.

The impact on relative sperm production was not changed the cytoarchitecture of seminiferous tubules and the frequencies of different stages of the spermatogenic process. This absence of histological injury also was observed in study of Kwack et al. (2004). These researchers found impairment on fertility and pregnancy outcome, without histopathological changes in testis and epididymis, after paternal exposure to 5 mg kg<sup>-1</sup> bw of 3-MCPD for four weeks. Despite this, Cho et al. (2008) observed degeneration of the seminiferous epithelium in adult mice after subchronic exposure to higher doses of 36.97 and 76.79 mg kg<sup>-1</sup> of 3-MCPD.

In the present study, in spite the maintenance of the general morphological characteristics of the testes and absence of evident histological alterations, 3-MCPD exposure affected the number of germ cells per seminiferous tubules. In adult rats, Madhu, Sarkar, Biswas, Behera, and Patra (2011) observed reduction in seminiferous tubular areas, secondary spermatocytes and nuclear diameter of Leydig and Sertoli cells after 45 days of exposure to 1 mg kg<sup>-1</sup> bw day<sup>-1</sup> of 3-MCPD. Moreover, spermatogonia, primary spermatocytes and Sertoli cells increased at 15 and 45 days of exposure. On the other hand, in the current study the number of Sertoli cells was decreased in seminiferous tubules of rats exposed to 5 and 10 mg kg<sup>-1</sup> bw day<sup>-1</sup> of the food contaminant when compared to control and TA groups. This

result suggests that there was cell death and not a reduction of its proliferation, since the exposure began after the end of Sertoli cell proliferation period (Orth, Gunsalos, & Lampert, 1988). The decrease in Sertoli cell number may have triggered the reduction observed in counts of the spermatogonias type A, pachytene primary spermatocytes and round spermatids. This fact might be related to control on spermatogenesis magnitude exercised by Sertoli cell (Hess & França, 2005).

In the current study, epididymis histology was no impaired by 3-MCPD, corroborating study of Kwack et al. (2004). On the other hand, Kim et al. (2012) found spermatoc granuloma, cell debris, epithelial cell vacuolization and oligospermia in proximal caput epididymis of adult rats after treatment with 10 mg kg<sup>-1</sup> bw day<sup>-1</sup> of 3-MCPD for seven days.

Evaluation of sperm morphology by light microscopy indicated no difference among the experimental groups, as related by Kim et al. (2012). Nevertheless, electron microscopy analysis realized by Madhu et al. (2011), revealed sperm abnormalities, including deglutination of the acrosomal part, loss of head capsules, and fragmentation of tail fibrils.

3-MCPD did not affect the transit time through the epididymis; however, sperm motility was reduced, suggesting changes in the sperm maturation process. Several authors also observed impairment in sperm motility of adult rats after 3-MCPD exposure at different doses (Kwack et al., 2004, Kim et al., 2012). Decrease in H<sup>+</sup>-ATPase expression in the cauda epididymis (Kwack et al., 2004) and enzymes inhibition of sperm glycolysis, especially enzymes glyceraldehyde-3-phosphate dehydrogenase (GAPDH) and triosephosphate isomerase (Jones & Porter, 1995, Lynch et al., 1998) have been associated to motility change.

## Conclusion

These results show that prepubertal rats exposed to 3-MCPD might present alterations, number of Sertoli and germ cells, relative sperm production and motility, with impact on sperm quality, similar to impairment caused by exposure of adult animals reported in the literature. Since chloropropanols are present in the daily diet of population is essential determining their potential risks to human reproductive health. Thus, additional studies are needed to investigate more deeply the mechanisms involved in these reproductive effects observed and the relationship between the changes in sperm parameters and possible impact on fertility capacity.

## Acknowledgements

Grant support: CNPq (*Conselho Nacional de Desenvolvimento Científico e Tecnológico*).

## Reference

- Abercrombie, M. (1946). Estimation of nuclear population from microtome sections. *The Anatomical Record*, 94(2), 239-247.
- Arisseto, A. P., Vicente, E., Furlani, R. P. Z., & Toledo, M. C. F. (2013). Estimate of dietary intake of chloropropanols (3-MCPD and 1,3-DCP) and health risk assessment. *Ciência e Tecnologia de Alimentos*, 33(1), 125-133.
- Baer, I., De La Calle, B., & Taylor, P. (2010). 3-MCPD in food other than soy sauce or hydrolysed vegetable protein (HVP). *Analytical and Bioanalytical Chemistry*, 396(1), 443-456.
- Bakhiya, N., Abraham, K., Gürtler, R., Appel, K. E., & Lampen, A. (2011). Toxicological assessment of 3-chloropropane-1,2-diol and glycidol fatty acid esters in food. *Molecular Nutrition & Food Research*, 55(4), 509-521.
- Cho, W. S., Han, B. S., Lee, H., Kim, C., Nam, K. T., Park, K., ... Jang, D. D. (2008). Subchronic toxicity study of 3-monochloropropane-1,2-diol administered by drinking water to B6C3F1 mice. *Food and Chemical Toxicology*, 46(5), 1666-1673.
- Clegg, E. (1960). The age at which male rats become fertile. *Journal of Reproductive & Fertility*, 1(1), 119-120.
- Clegg, E. D., Perreault, S. D., & Klinefelter, G. R. (2001). Assessment of male reproductive toxicology. In H. Wallace (Ed.), *Principles and methods of toxicology* (4th ed., p. 1263-99). Philadelphia, PA: Taylor & Francis.
- Crews, C., Brereton, P., & Davies, A. (2001). The effects of domestic cooking on the levels of 3-monochloropropanediol in foods. *Food Additive and Contaminants*, 18(4), 271-280.
- Fernandes, G. S., Arena, A. C., Fernandez, C. D., Mercadante, A., Barbisan, L. F., & Kempinas, W. G. (2007). Reproductive effects in male rats exposed to diuron. *Reproductive Toxicology*, 23(1), 106-112.
- Filler, R. (1993). Methods for evaluation of rat epididymal sperm morphology. In R. E. Chapin, & J. H. Heindel (Eds.), *Methods in toxicology: Male reproductive toxicology* (p. 334-343). San Diego, CA: Academic Press.
- Food and Agriculture Organization., & World Health Organization. (2007). Safety evaluation of certain food additives and contaminants. Geneva, CH: FAO/WHO.
- Fu, W. S., Zhao, Y., Zhang, L., Li, J. G., Tang, C. D., Miao, H., ... Wu, Y. N. (2007). Occurrence of chloropropanols in soy sauce and other foods in China between 2002 and 2004. *Food Additive and Contaminants*, 24(8), 812-819.
- Hamlet, C. G., & Sadd, P. A. (2009). Chloropropanols and chloroesters. In R. H. Stadler, & D. R. Lineback (Eds.), *Process-Induced food toxicants: occurrence, formation, mitigation, and health risks* (p. 175-214). Hoboken, NJ: John Wiley & Sons Inc.
- Hess, R. A., & França, L. R. (2005). Structure of the Sertoli cell. In M. K. Skinner, & M. Dgswold (Eds.), *Sertoli cell biology* (p. 19-40). San Diego, CA: Elsevier Academic Press.
- Hwang, M., Yoon, E., Kim, J., Jang, D. D., & Yoo, T. M. (2009). Toxicity value for 3-monochloropropane-1, 2-diol using a benchmark dose methodology. *Regulatory Toxicology and Pharmacology*, 53(2), 102-106.
- Jędrkiewicz, R., Kupka, M., Głowacz, A., Gromadzka, J., & Namieśnik, J. (2016). 3-MCPD: A worldwide problem of food chemistry. *Critical Reviews in Food Science and Nutrition*, 56(14), 2268-2277.
- Johnson, L., Welsh, T. H. J., & Wilker, C. E. (1997). Anatomy and physiology of the male reproductive system and potential targets of toxicants. In K. Boekleheide, R. E. Chapin, P. B. Hoyer, & C. Harris (Eds.), *Comprehensive toxicology* (p. 5-61). New York City, NK: Pergamon.
- Jones, A. R., & Porter, L. M. (1995). Inhibition of glycolysis in boar spermatozoa by alphachlorohydrin phosphate appears to be mediated by phosphatase activity. *Reproductive, Fertility and Development*, 7(5), 1089-1094.
- Kim, S. H., Lee, I. C., Baek, H. S., Moon, C., Bae, C. S., Kim, S. H., ... Kim, J. C. (2014). Ameliorative effects of pine bark extract on spermatotoxicity by  $\alpha$ -chlorohydrin in rats. *Phytotherapy Research*, 28(3), 451-457.
- Kim, S. H., Lee, I. C., Lim, J. H., Moon, C., Bae, C. S., Kim, S. H., ... Kim, J. C. (2012). Spermatotoxic effects of  $\alpha$ -chlorohydrin in rats. *Laboratory Animal Research*, 28(1), 11-16.
- Krasnow, S. M., & Steiner, R. A. (2006). Physiological mechanisms integrating metabolism and reproduction. In E. Knobil, & J. D. Neill (Eds.), *The physiology of Reproduction* (3rd ed., p. 2559-2561). San Diego, CA: Elsevier Academic Press.



- Kwack, S. J., Kim, S. S., Choi, Y. W., Rhee, G. S., Da Lee, R., Seok, J. H., ... Lee, B. M. (2004). Mechanism of antifertility in male rats treated with 3-monochloro-1,2-propanediol (3-MCPD). *Journal of Toxicology and Environmental Health Part A*, 67(23-24), 2001-2011.
- Leblond, C. P., & Clemont, Y. (1952). Spermatogenesis of rat, mouse, hamster and guinea pig as revealed by the periodic acid-fuchsin-sulfurous acid technique. *The American Journal of Anatomy*, 90(2), 167-215.
- Li, C., Nie, S. P., Zhou, Y. Q., & Xie, M. Y. (2015). Exposure assessment of 3-monochloropropane-1, 2-diol esters from edible oils and fats in China. *Food and Chemical Toxicology*, 75(1), 8-13.
- Lynch, B. S., Bryant, D. W., Hook, G. J., Nestmann, E. R., & Munro, I. C. (1998). Carcinogenicity of monochloro-1,2-propanediol (a-chlorohydrin, 3-MCPD). *International Journal of Toxicology*, 17(1), 47-76.
- Madhu, N. R., Sarkar, B., Biswas, S. J., Behera, B. K., & Patra, A. (2011). Evaluating the anti-fertility potential of  $\alpha$ -chlorohydrin on testis and spermatozoa in the adult male wild Indian house rat (*Rattus rattus*). *Journal of Environmental Pathology, Toxicology and Oncology*, 30(2), 93-102.
- Ojeda, S. R., Andrews, W. W., Advis, J. P., & White, S. S. (1980). Recent advances in the endocrinology of puberty. *Endocrine Reviews*, 1(3), 228-257.
- Onami, S., Cho, Y. M., Toyoda, T., Horibata, K., Ishii, Y., Umemura, T., ... Ogawa, K. (2014). Absence of in vivo genotoxicity of 3-monochloropropane-1,2-diol and associated fatty acid esters in a 4-week comprehensive toxicity study using F344 gpt delta rats. *Mutagenesis*, 29(4), 295-302.
- Orth, J. M., Gunsals, G. L., & Lampert, A. A. (1988). Evidence from Sertoli cell depleted rats indicates that spermatid number in adults depends on numbers of Sertoli cells produced during perinatal development. *Endocrinology*, 122(3), 787-794.
- Perobelli, J. E. (2014). The male peripubertal phase as a developmental window for reproductive toxicology studies. *Current Pharmaceutical Design*, 20(34), 5398-5415.
- Rahn, A. K. K., & Yaylayan, V. A. (2011). What do we know about the molecular mechanism of 3-MCPD ester formation? *European Journal of Lipid Science and Technology*, 113(3), 323-329.
- Robb, G. W., Amann, R. P., & Killian, G. J. (1978). Daily sperm production and epididymal sperm reserves of pubertal and adult rats. *Journal of Reproduction and Fertility*, 54(1), 103-107.
- Robjohns, S., Marshall, R., Fellows, M., & Kowalczyk, G. (2003). *In vivo* genotoxicity studies with 3-monochloropropane-1,2-diol. *Mutagenesis*, 18(5), 401-404.
- Sawada, S., Oberemm, A., Buhrke, T., Meckert, C., Rozycki, C., Braeuning, A., & Lampen, A. (2015). Proteomic analysis of 3-MCPD and 3-MCPD dipalmitate toxicity in rat testis. *Food and Chemical Toxicology*, 83(1), 84-92.
- Seed, J., Chapin, R. E., Clegg, E. D., Dostal, L. A., Foote, R. H., Hurtt, M. E., ... Wise, L. D. (1996). Methods for assessing sperm motility, morphology, and counts in the rat, rabbit, and dog: a consensus report. ILSI risk science institute expert working group on sperm evaluation. *Reproductive Toxicology*, 10(3), 237-244.
- Sun, J., Bai, S., Bai, W., Zou, F., Zhang, L., Su, Z., ... Huang, Y. (2013). Toxic mechanisms of 3-monochloropropane-1,2-diol on progesterone production in R2C rat Leydig cells. *Journal of Agricultural and Food Chemistry*, 61(41), 9955-9960.
- Wöhrlin, F., Fry, H., Lahrssen-Wiederholt, M., & Preiß-Weigert, A. (2015). Occurrence of fatty acid esters of 3-MCPD, 2-MCPD and glycidol in infant formula. *Food Additives & Contaminants. Part A, Chemistry, Analysis, Control, Exposure & Risk Assessment*, 32(11), 1810-1822.
- Yamada, T., Inoue, T., Sato, A., Yamagishi, K., & Sato, M. (1995). Effects of short-term administration of alpha-chlorohydrin on reproductive toxicity parameters in male Sprague-Dawley rats. *Journal of Toxicological Sciences*, 20(3), 195-205.
- Zelinková, Z., Novotný, O., Schůrek, J., Velíšek, J., Hajslová, J., & Dolezal, M. (2008). Occurrence of 3-MCPD fatty acid esters in human breast milk. *Food Additives & Contaminants. Part A, Chemistry, Analysis, Control, Exposure & Risk Assessment*, 25(6), 669-676.
- Zelinkova, Z., Svejková, B., Velíšek, J., & Dolezal, M. (2006). Fatty acid esters of 3-chloropropane-1,2-diol in edible oils. *Food Additives & Contaminants. Part A, Chemistry, Analysis, Control, Exposure & Risk Assessment*, 23(12), 1290-1298.

Received on March 14, 2016.

Accepted on March 14, 2017.

License information: This is an open-access article distributed under the terms of the Creative Commons Attribution License, which permits unrestricted use, distribution, and reproduction in any medium, provided the original work is properly cited.