



Jornal Vascular Brasileiro

ISSN: 1677-5449

jvascbr.ed@gmail.com

Sociedade Brasileira de Angiologia e de
Cirurgia Vascular
Brasil

Lederman, Alex; Tavares Saliture Neto, Fernando; Mito Netto, Boulanger; Linhares Bub, Guilherme;
Lobato, Manoel Augusto; Aun, Ricardo

Inner tubing endograft: a new technique for bifurcation preservation

Jornal Vascular Brasileiro, vol. 8, núm. 3, 2009, pp. 255-258

Sociedade Brasileira de Angiologia e de Cirurgia Vascular
São Paulo, Brasil

Available in: <http://www.redalyc.org/articulo.oa?id=245016488017>

- How to cite
- Complete issue
- More information about this article
- Journal's homepage in redalyc.org

redalyc.org

Scientific Information System

Network of Scientific Journals from Latin America, the Caribbean, Spain and Portugal

Non-profit academic project, developed under the open access initiative

Inner tubing endograft: a new technique for bifurcation preservation

Inner tubing: uma nova técnica para preservação de bifurcações

Alex Lederman, Fernando Tavares Saliture Neto, Boulanger Mioto Netto, Guilherme Linhares Bub, Manoel Augusto Lobato, Ricardo Aun*

Abstract

Treating narrow arteries and their bifurcations is a major challenge to the endovascular surgeon. We describe a new endovascular technique that was used to treat a narrow aorta and that may also be used to preserve other bifurcations. Using three straight stents may enable the endovascular surgeon to treat bifurcation while maintaining flow to both distal arteries.

Keywords: Abdominal aortic aneurysms, iliac artery, vascular prosthesis.

Introduction

Endovascular management of aortic lesions has been evolving, with an increasing number of treatment options for patients. Most of the technical difficulties faced by surgeons involve aortic branches and their bifurcations, as well as iliac arteries. Preservation of the internal iliac artery is one of the main difficulties when both sides are involved and endovascular treatment is chosen.

Many authors¹⁻⁵ have described alternative ways to preserve at least one internal iliac artery. Techniques such as femorofemoral crossover bypass graft,¹ reverse-U stent grafting,² hybrid approaches and even branched grafts³ have been used to preserve internal iliac arteries. The chimney graft⁶ introduced the principle of parallel tubing to preserve side branches of the thoracic and abdominal aorta.

The inner tubing technique reported here is a simple approach that uses three straight stents to create a new bifurcation. This technique was used to create a new aortic bifurcation, but may also be used in iliac artery bifurcation so as to preserve internal iliac arteries.

Resumo

O tratamento de artérias de pequeno calibre e suas bifurcações é um grande desafio para o cirurgião endovascular. Descrevemos uma nova técnica endovascular que foi usada no tratamento de uma aorta de pequeno calibre e que também pode ser usada para preservar outras bifurcações. O uso de três stents retos pode permitir ao cirurgião endovascular o tratamento de bifurcação mantendo o fluxo em ambas as artérias distais.

Palavras-chave: Aneurismas de aorta abdominal, artéria iliaca, prótese vascular.

Technique

This technique consists of deploying a first endograft in the larger vessel, followed by two parallel endografts inside the first one, with a “kissing” technique, and distal landing zones in the distal arteries. It is important that these two inner stents are deployed near the origin of the outer stent, so that a long contact area prevents flow in between these inner stents. Both proximal and distal landing zones should be adequately sealed.

For aortic bifurcation, guidewires and endografts should be placed via femoral access. When preservation of the internal iliac artery is intended and a crossover technique is not feasible (due to acute angle, aortic endoprosthesis), left axillary artery is the access of choice to deliver the internal iliac endograft.

Case report

We report the case of a 64-year-old female patient with chronic obstructive pulmonary disease and no previous history of any vascular disease. During CT scan for a lower back pain, an aortic aneurysm was discovered. She was referred to our vascular surgery team.

* Hospital Israelita Albert Einstein, São Paulo, SP, Brazil.

No conflicts of interest declared concerning the publication of this article.
Manuscript received Dec 17 2008, accepted for publication Jun 23 2009.

J Vasc Bras. 2009;8(3):255-258.

Copyright © 2009 by Sociedade Brasileira de Angiologia e de Cirurgia Vascular

At physical examination, femoral pulses were very weak, and aortic bruit was audible. No aortic mass was palpable.

Computed tomographic angiography showed an infra-renal aortic saccular aneurysm (35 mm largest diameter) associated with a severe stenosis at the bifurcation and origins of common iliac arteries (Figure 1).

The aortic diameter (12 mm) was too small for a usual aortic endoprosthesis, and the patient did not accept an open procedure due to her lung condition.

The patient was operated under general anesthesia with bilateral femoral exposure. Intraoperative angiogram was obtained. The aortic lesion was treated with a conical Excluder® 16 x 14 x 70 mm endograft, placed below the origins of renal arteries (Figure 2). Next, bilateral guidewires were placed and a “kissing” procedure was performed to treat stenosis at the iliac arteries. Two 8 x 100 mm Hemobahn® stent grafts were placed through the aortic endograft into the iliac arteries and, then, were dilated with

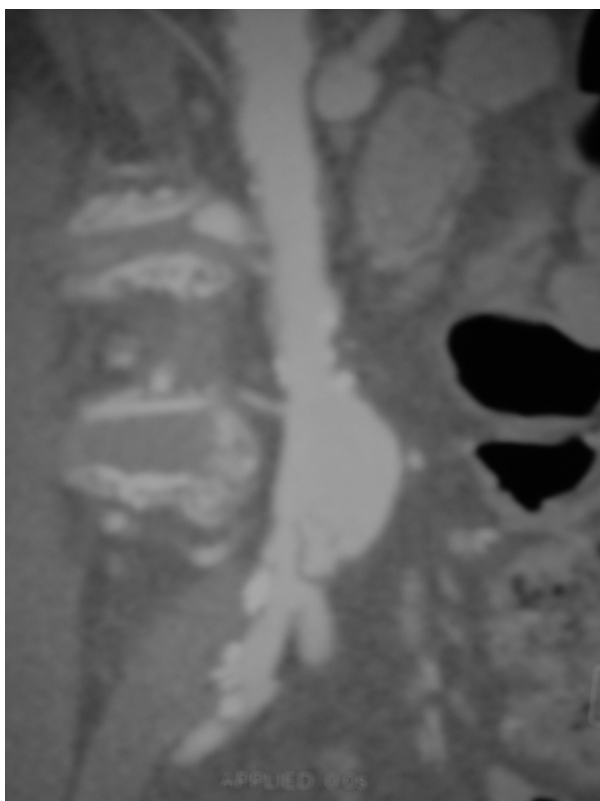


Figure 1 - Preoperative computed tomographic angiography: note the aortic ulcer associated with a saccular aneurysm and bifurcation stenosis

7 x 60 mm balloons. Control angiography showed that all lesions were treated and no leaks were identified (Figure 3).

After recovery from anesthesia, the patient presented one episode of hematemesis. During endoscopy, a small laryngeal lesion was diagnosed. There was no vascular instability, and no blood transfusion was required.

The patient was discharged with all distal pulses palpable and no abdominal bruit.

Discussion

Endovascular options to treat vascular diseases are becoming increasingly frequent. New materials as well as greater understanding of graft behavior and deployment have allowed many surgeons to adapt existing materials to

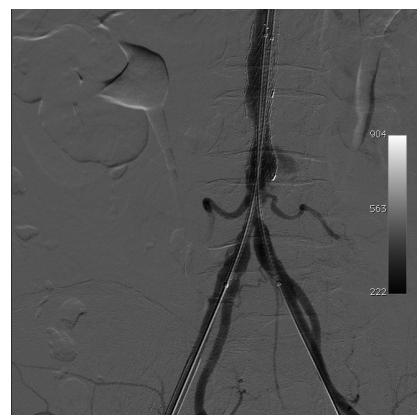


Figure 2 - Intraoperative arteriogram: a straight endograft is placed below the renal arteries. A small endoleak from the distal landing zone is still seen, before the iliac stents are placed

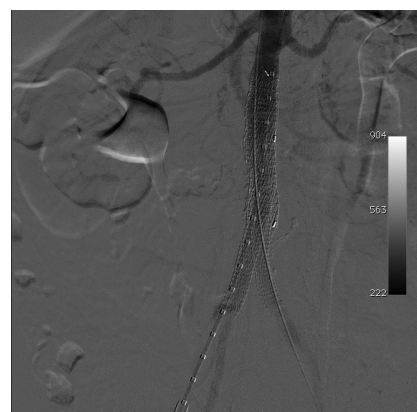


Figure 3 - Intraoperative angiography: after iliac branches were deployed, renal arteries are seen, the saccular aneurysm and iliac stenosis have been treated

special off-label situations.¹⁻⁶ We described a new technique using simple, “old”, easily available grafts to recreate a compromised bifurcation. However, this technique has the potential to treat any arterial bifurcation, as long as there is an accessible landing zone.

In conclusion, aortoiliac complex lesions in patients with narrow aortas may be treated with this newly described association of multiple endovascular techniques. The use of a large-diameter endograft in the aorta with two small-diameter grafts in a “kissing” maneuver is a good alternative to create a new bifurcation when it is not fit for a conventional bifurcated endograft (Figures 4, 5, and 6). This technique may also be used to treat isolated iliac artery aneurysms as well as in association with regular endovascular aneurysms so as to preserve internal iliac arteries. To our knowledge, treatment of a narrow aorta or treatment preserving internal iliac arteries with this technique have not been published before. A larger experience and longer follow-up are needed before the benefits of this method can be determined.

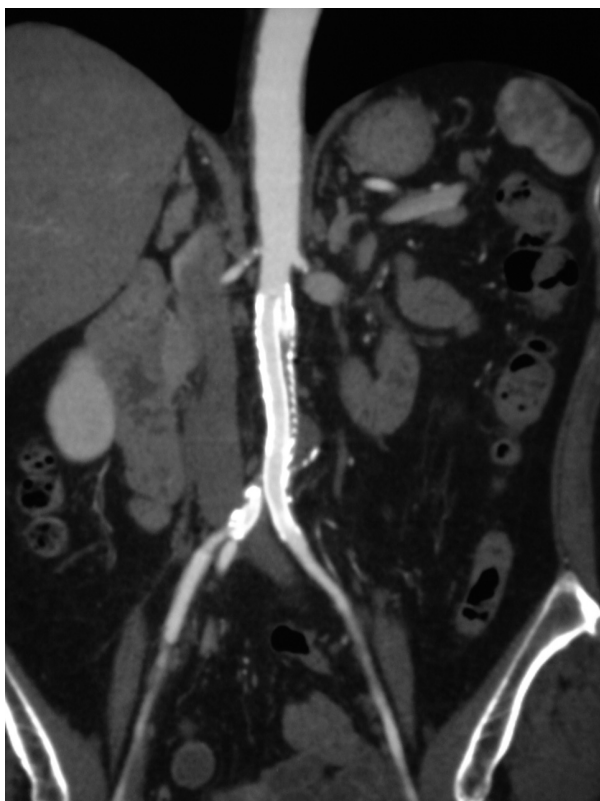


Figure 4 - Postoperative CT scan: a good view of the inner tubing technique. The saccular aneurysm can be seen, and has been excluded

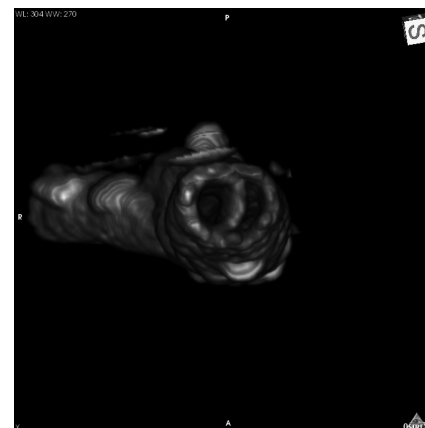


Figure 5 - Osirix® reconstruction showing the interior aspect of the inner tubing technique

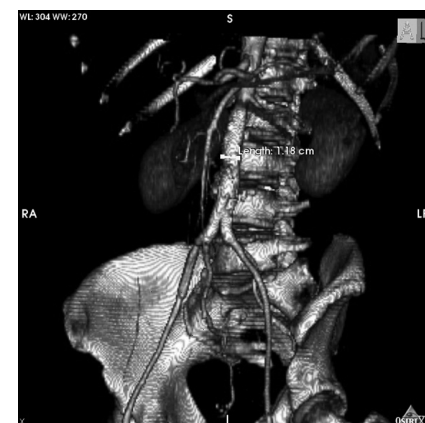


Figure 6 - Postoperative control computed tomographic angiography

References

1. Krupski WC, Selzman CH, Florida R, Strecker PK, Nehler MR, Whitehill TA. Contemporary management of isolated iliac aneurysms. *J Vasc Surg.* 1998;28:1-11.
2. Kotsis T, Tsanis A, Sfyroeras G, Lioupis C, Moulakakis K, Georgakis P. Endovascular exclusion of symptomatic bilateral common iliac artery aneurysms with preservation of aneurismal internal iliac artery via a reverse-u stent-graft. *J Endovasc Ther.* 2006;13:158-63.
3. Ferreira MM, Capotorto LF, Rondon GA, Monteiro WM, Soares CM, Azevedo LL. Branched stent-graft to the internal iliac artery for treatment of aortic aneurysm associated with bilateral common iliac artery aneurysm. *J Vasc Bras.* 2006;5:220-3.
4. Leon LR, Mills JL, Psalms SB, Goshima K, Duong ST, Ukatu C. A novel hybrid approach to the treatment of common iliac aneurysms: antegrade endovascular hypogastric stent grafting and femorofemoral bypass grafting. *J Vasc Surg.* 2007;45:1244-8.

5. Ziegler P, Avgerinus ED, Umscheid T, Perdikides T, Erz K, Stelter WF. Branched iliac bifurcation: 6 years experience with endovascular preservation of internal iliac artery flow. J Vasc Surg. 2007;46:204-10.
6. Ohlander T, Sonesson B, Ivancev K, Resch T, Dias N, Malina M. The chimney graft: a technique for preserving or rescuing aortic branch vessels in stent-graft sealing zones. J Endovasc Ther. 2008;15:427-32.

Correspondence:

Alex Lederman

Rua Capote Valente, 439/125

CEP 05409-001 – São Paulo, SP, Brazil

E-mail: alex@lederman.com.br