



Surgical & Cosmetic Dermatology

ISSN: 1984-5510

revista@sbd.org.br

Sociedade Brasileira de Dermatologia
Brasil

Campos, Valeria B.; Gontijo, Gabriel
Fractional CO2 laser: a personal experience
Surgical & Cosmetic Dermatology, vol. 2, núm. 4, octubre-diciembre, 2010, pp. 326-332
Sociedade Brasileira de Dermatologia

Available in: <http://www.redalyc.org/articulo.oa?id=265519558016>

- How to cite
- Complete issue
- More information about this article
- Journal's homepage in redalyc.org

redalyc.org

Scientific Information System
Network of Scientific Journals from Latin America, the Caribbean, Spain and Portugal
Non-profit academic project, developed under the open access initiative

How do I do

Authors:

Valeria B. Campos¹
Gabriel Gontijo²

¹ Dermatology and Laser Fellow, Harvard Medical School, Boston (MA), US

² Dermatology Instructor, Faculdade de Medicina da Universidade Federal de Minas Gerais (UFMG) and Dermatologic Surgery Preceptor, Hospital das Clínicas da Universidade de Medicina da Universidade Federal de Minas Gerais (UFMG), Belo Horizonte (MG), Brazil

Correspondence:

Dra. Valéria B. Campos
Av. 9 Julho / 1677 – 3 andar - Jundiaí
13201-798 – São Paulo - SP
email: clinicavcampos@hotmail.com

Received on: 01/10/2010
Approved on: 20/10/2010

This study was carried out at the authors' private practice.

Conflicts of interest: none
Financial support: none

Fractional CO₂ laser: a personal experience

Laser fracionado de CO₂: uma experiência pessoal

ABSTRACT

Over the last 20 years, a number of methods have been used for facial rejuvenation; there is currently a search for new technologies that can overcome flaws inherent in the procedure. With the fractioning of the CO₂ laser, the technique has gained renewed prominence. Nevertheless, the expectation of an improved procedure that is as effective as traditional ablative resurfacing and 100% safe has not been met. Although fractional ablative resurfacing has proven to be a considerably valuable procedure, results do not match those of the traditional procedure. And while the fractioning of the laser decreases side effects, they must not be overlooked. In this article we describe in detail our personal experience, including possible side effects and how to avoid and treat them.

Keywords: lasers, carbon dioxide; carbon dioxide/adverse effects.

RESUMO

Diversos métodos têm sido utilizados para rejuvenescimento facial. O resurfacing facial, após mais de 20 anos de existência, passou por fase de amadurecimento e busca de novas tecnologias que viessem complementar as falhas inerentes ao procedimento e atualmente, após seu fracionamento volta a ter o destaque que já teve no passado. Essa fase, porém, iniciou-se com a expectativa de um procedimento com a mesma eficácia do resurfacing ablativo tradicional e 100% seguro, infelizmente isso não aconteceu. O resurfacing fracionado ablativo tem-se mostrado um procedimento muito valioso porém os resultados não são os mesmos do resurfacing tradicional; o fracionamento realmente diminuiu os efeitos colaterais, mas esses não devem ser desprezados. Nesse artigo falamos sobre a nossa experiência pessoal, falamos detalhadamente sobre os possíveis efeitos colaterais, como evitá-los e tratá-los.

Palavras-chave: lasers; dióxido de carbono; dióxido de carbono/efeitos adversos.

INTRODUCTION

Facial rejuvenation has been a concern for a long time. Several methods are used, and treatment using carbon dioxide (CO₂) laser is currently the object of discussion and expectation. After more than 20 years of existence, facial resurfacing went through a maturation process that included the search for new technologies that could complement the procedure's inherent flaws. The established ablative resurfacing technique thus experienced a fractioning of its rays. While this was an extremely positive development, expectations that this method would be as efficient as traditional resurfacing and 100% safe were not confirmed by practical experience. Ablative resurfacing has proven to be a very valuable method, however in-depth knowledge about the procedure is required in order to obtain the best results for patients.

CO₂ LASER PHYSICS

CO₂ laser, conceived by Kumar Patel in 1964, was one of the first to use a gas as refraction medium.¹ It is still one of the most widely used lasers worldwide, as much as in medicine as in industry in general.

CO₂ laser emits 10,600 nm wavelength rays, which are strongly absorbed by tissular water (Figures 1A and 1B). The depth of penetration depends on the content of the water rather than on the melanin and hemoglobin. On average, with a pulse duration less than one millisecond, the light of CO₂ laser penetrates 20–30 μ into the tissue.²

Heat production is its action mechanism. Small temperature elevations produce tissular biostimulation; temperatures between 600° C and 850° C cause coagulation; temperatures above 850°C result in carbonization, while temperatures close to 1,000° C lead to vaporization.³

In CO₂ lasers, vaporization happens when the ray reaches the skin, resulting from the super-fast heating, ebullition and vaporization of the water, which generates the ablation responsible for the ablative resurfacing. This transfer of heat is probably responsible for the denaturation of collagen.⁴ Denaturation is a process that takes place in biological molecules – mainly in proteins – exposed to conditions different from those in which they were produced (e.g., temperature variations). The protein loses its three-dimensional structure and, therefore, its properties. This reaction is exothermic: it liberates heat that then dissipates to

adjacent cells and causes the “residual thermal effect,” which stimulates collagen production. Collagen denaturation contributes to the contraction of tissues visible to the naked eye during the procedure, and afterwards to the improvement of wrinkles and sagging. In addition, this phenomenon also induces a tissular reaction that generates neocollagenesis during the six months following the procedure.⁵ In short, CO₂ laser rejuvenates the skin by causing the collagen to contract, ablating (removing) photodamaged skin, provoking a peripheral thermal lesion and stimulating neocollagenesis.

CO₂ LASER HISTORY

CO₂ laser was among the first lasers to be developed, and is also one of the most useful, not only in medicine.⁴ The first versions were used in the lips for the treatment of actinic cheilitis.⁶ Extending this technique to the whole face became known as ablative resurfacing, which proved to be extremely effective.⁴ Nevertheless, the procedure was very painful, demanding a long post-operative period and intensive care that could last for months, as well as the suspension of personal activities. In addition, the percentage of adverse side effects – including infection, erythema, long-duration hyper and hypopigmentations, and scars – was considerable.

From 1990, the equipment was developed based on Rox Anderson's selective photothermolysis theory⁷ and a new category of devices with short pulses (ultrapulse), high energies and scanners was launched to minimize the above mentioned problems. Fortunately, the incidence of side effects decreased. Nonetheless, the procedure remained quite aggressive and painful, and had long recovery periods and a considerable rate of side effects.

FRACTIONING

The fractional photothermolysis method was conceived at Harvard University by Dieter Manstein and Rox Anderson in 2004.⁸ It was developed to offer results as effective as traditional resurfacing without its disadvantages. The basic idea was to reach the skin deeply (dermally), however punctually, in microscopic fractions. Those micro-fractions coagulated by laser are known as "Micro Thermal Zones" (MTZs). Since this technique does not remove the epidermis, it is known as non-ablative resurfacing. Between the MTZs there are islands of untreated, intact skin that promote healing (Figure 2). Thus the laser has a deep action without breaking the skin. There is an progressive change of tissue, with a faster and easier recovery period. MTZs are not visible to the naked eye.

The first equipment to employ this technique was the Fraxel® (Reliant City, US). Other devices were launched soon after, each with its unique advantages and disadvantages. Although the safety of the technique improved considerably, less aggressive non-ablative procedures do not remodel the surface of the skin significantly and can be insufficient to improve severe solar elastosis. Non-ablative lasers do not penetrate as deeply or promote as much new collagen formation as ablative

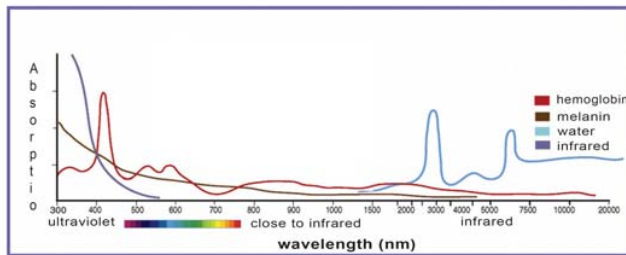


Figure 1- A: Skin main chromophores' absorption curve

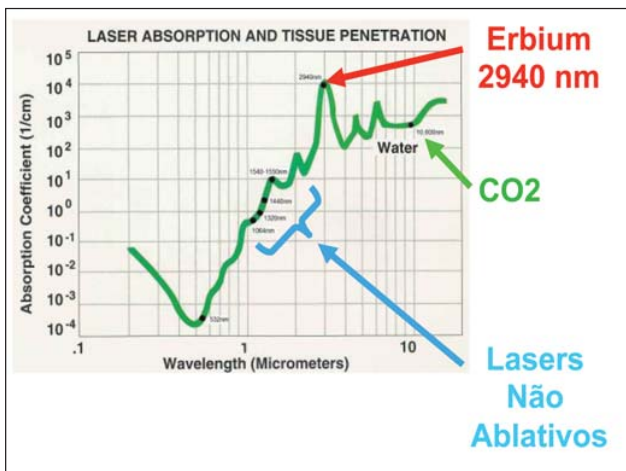


Figura 1 - B: Water's absorption curve

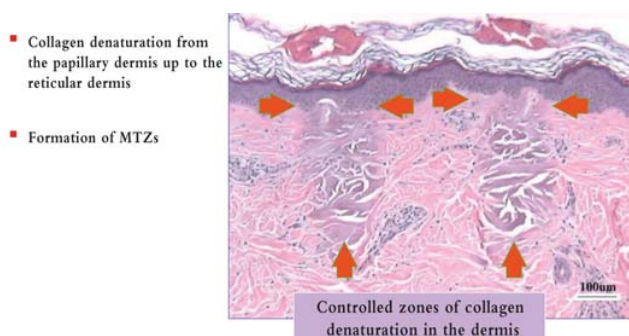


Figure 2 - Non-ablative fractional lasers' mechanism of action

Courtesy: D. Manstein

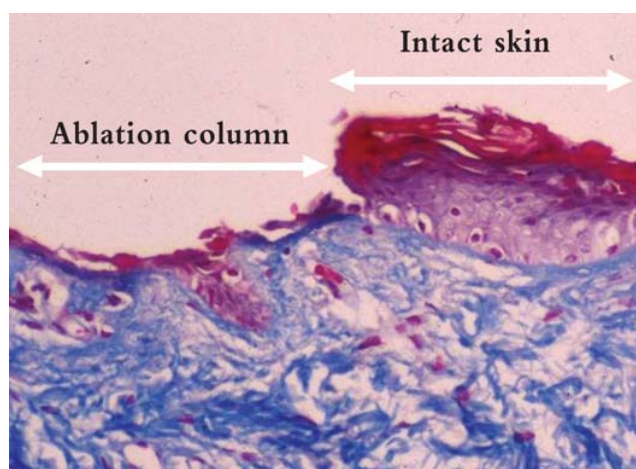


Figure 3 - Skin column removed in area without adjacent lesion

procedures. In addition, high costs for both the patient and the physician (expensive equipment and consumption materials), and the need for multiple applications, led the industry to launch other equipments.³

FRACTIONAL ABLATIVE LASERS

Fractional ablative lasers were introduced in 2006; the goal was to develop a technique as efficient in removing wrinkles as traditional CO₂ lasers, and as safe as non-ablative resurfacing. Fractional ablative resurfacing generates ruptures in the epider-

mis that are surrounded by intact skin (Figure 3). The lesion depth is determined by the amount of energy supplied (Figure 4).⁹ The fractioning of the laser allows it to reach much deeper layers (up to 1,500 µm) than non-fractional ablative resurfacing (10–300 µm).¹⁰ Although the laser fractioning made the technique less efficient for treating facial wrinkles, photoaging and scars, it greatly improved its safety.¹¹

INDICATIONS

Fractional CO₂ lasers are mostly indicated for cutaneous rejuvenation (Figure 5). It is a good option for treating facial aging, since it causes collagen to contract. It is also an option to treat pigmented lesions and improve actinic keratoses.¹⁰ The fractioning of the laser allows the treatment of extra-facial areas as such the neck, chest, arms and legs.¹¹ Modern equipment allows more intense performances, therefore with more difficult (Figure 6) or easier (Figure 7) post-operative conditions, as recommended in each case.

Other indications are: acne, chicken-pox and surgical scars. The same indications for traditional CO₂ laser are valid, for it is possible to operate the equipment on the non-fractional method. The therapeutic indications are: seborrheic and actinic keratoses, warts, nevi, acrochordons, rhinophyma, sebaceous hyperplasias, xanthelasma, syringomas, actinic cheilitis, angiofibromas, keloids (adjuvating) and neurofibromas. CO₂ laser is not recommended for the removal of tattoos and permanent makeup.

SIDE EFFECTS

Although the very frequent incidence of side effects with traditional CO₂ laser decreased considerably with the new fractional technology, the effects of the new technique may have been initially underestimated.^{10,11}

POST-OPERATIVE EDEMA

Edema varies from light to moderate. In the periorbital region, it reaches its peak the morning after the procedure. In the rest of the face, the worst phase occurs between the second and third day after the procedure. It does not usually cause intense discomfort, and improves with daily sessions of infrared light emitting diodes (LEDs). In the most intense cases, oral (pred-

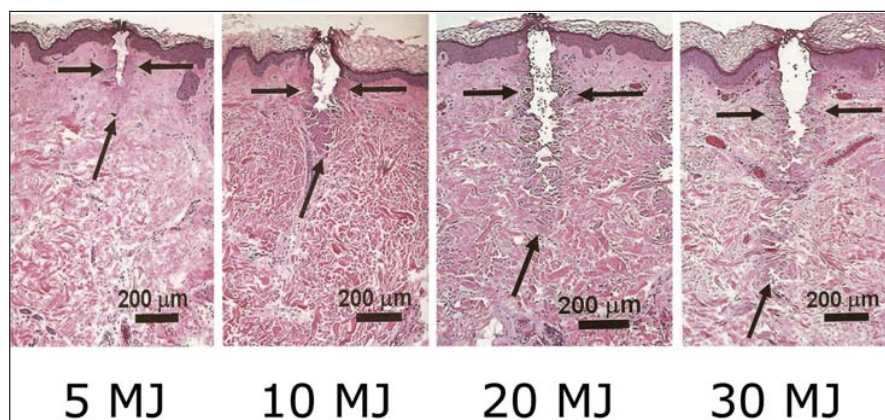


Figure 4 - In vivo fractional CO₂, immediately after procedure

Courtesy: Hantash et al.⁶

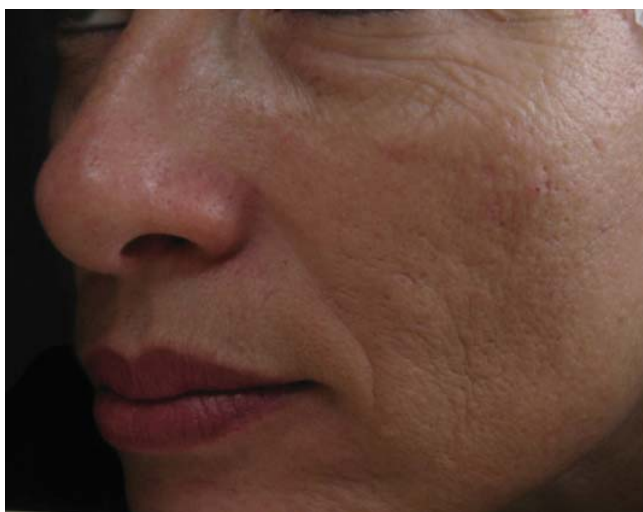
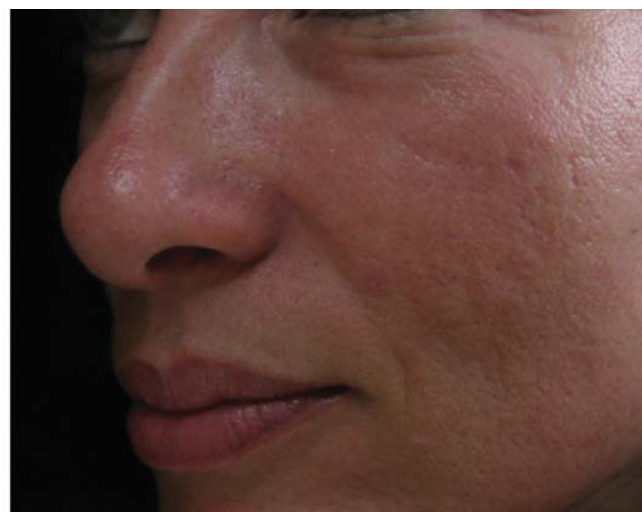
Figure 5 - Before



1 year after single session

nisone 40–60 mg/day, for 2 to 4 days) or intramuscular corticotherapy can be used. Cool chamomile tea compresses, thermal bags or thermal water spray can also relieve the discomfort.

ERYTHEMA

All patients experience temporary erythema after treatment with fractional CO₂ laser. The intensity and persistence of the redness are proportional to the depth of the resurfacing (the higher the energy used, the deeper the action) and the number of passes (Figure 4).¹⁵ Persistent erythema is extremely rare with fractional lasers, and can be treated with dye laser or intense pulsed light (IPL).

HYPOPIGMENTATION

Hypopigmentation is extremely rare after the use of fractional CO₂ laser, and normally appears six months after treatment. There are two hypopigmentation types: true hypopigmentation and the pseudo-hypopigmentation. In the first, loss of

melanin happens after very aggressive resurfacing, local infection or contact dermatitis. Abuse of hydroquinone before treatment may be another cause. Treatment is complex and can be carried out with non-ablative lasers, Excimer laser, melanocytes micrografts, or micropigmentation with permanent makeup. Pseudo-hypopigmentation means a lighter appearance of the treated skin compared to the adjacent skin. This condition can be minimized by avoiding the treatment of isolated facial aesthetic units and gradually reducing the density and energy in the transition areas (i.e., between the face and neck or the chest and neck).

HYPERPIGMENTATION

Hyperpigmentation is a very common side effect of traditional CO₂ laser, which has decreased with fractioning (Figure 8). It mainly affects Fitzpatrick phototypes IV and V. The use of topical prophylactic medication before treatment to prevent post-inflammatory hyperchromia is controversial.⁷ Hyperpigmentation occurs after the first month of the treatment, and is often triggered by exposure to the sun or heat. It can be treated with whitening creams containing hydroquinone or another whitening substance. IPL and non-ablative resurfacing are alternative treatments.

PRURITUS

Although it is extremely common, usually secondary to the healing process, pruritus can be a sign of secondary infection caused by the patient scratching his/her own skin, and can cause hypertrophic scars.^{10,11} After an infection is ruled out, treatment is carried out with compresses of cooled boiled water or thermal water spray. Antihistamines, including those that cause drowsiness (dexchlorpheniramine), can also be indicated.

SCARS

Scars can be hypertrophic or atrophic. They are less common with fractioned lasers, however they still occur sponta-

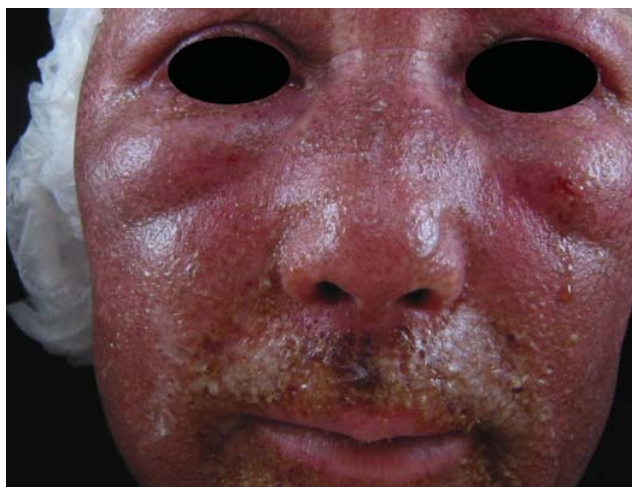

Figure 6 - Patient 3 days after UltraPulse Encore CO₂ Laser Active FX Deep FX (Lumenis) session

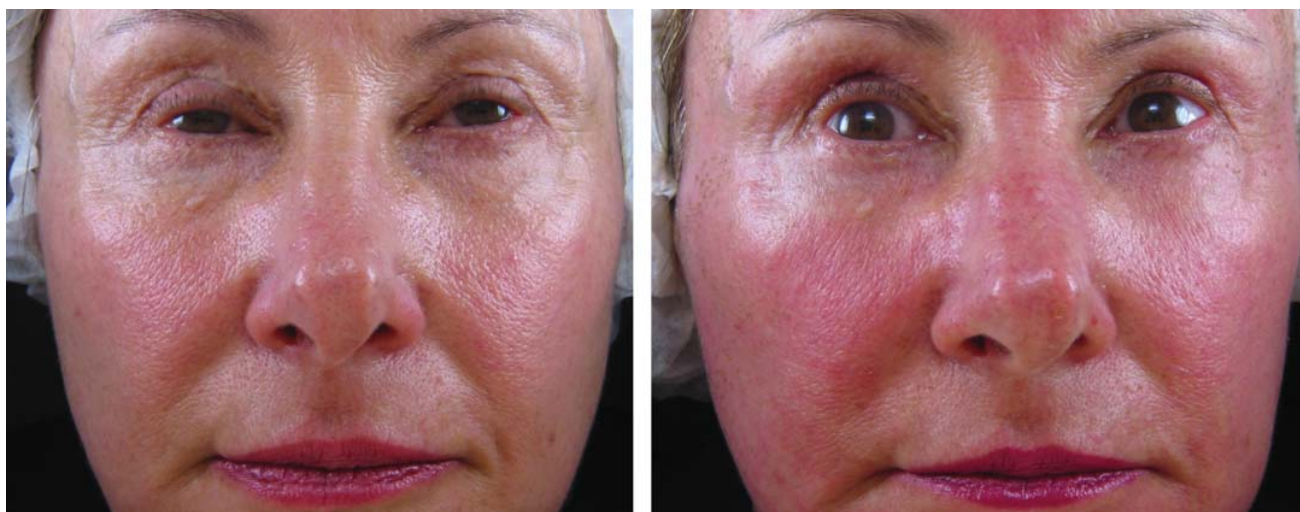

Figure 7 - Patient before and 3 days after UltraPulse Encore CO Laser Active (Lumenis) session

neously or following very aggressive procedures.^{10,11} Scars are more common in areas where the skin is thinner (e.g., neck and periocular regions). Atrophic scars must be treated with multiple sessions of non-ablative fractional resurfacing (1540 or 1550 nm). Dye laser is indicated for both types, and intralesional corticotherapy is recommended for hypertrophic scars.

CONCLUSION

The fractioning of CO₂ lasers undoubtedly brought enormous benefits – and also a false sense of security regarding side effects. Complications can occur even under the supervision of very well-trained physicians, and the popularization of lasers has encouraged the emergence of a new generation of physicians who are not sufficiently concerned with extensive training. The new devices perform deeper treatment (up to 1500 µm), which increases the probability of side effects. Resurfacing is a procedure that is here to stay; fractional CO₂ laser continues to be an efficient and aggressive treatment, and should be treated as such.

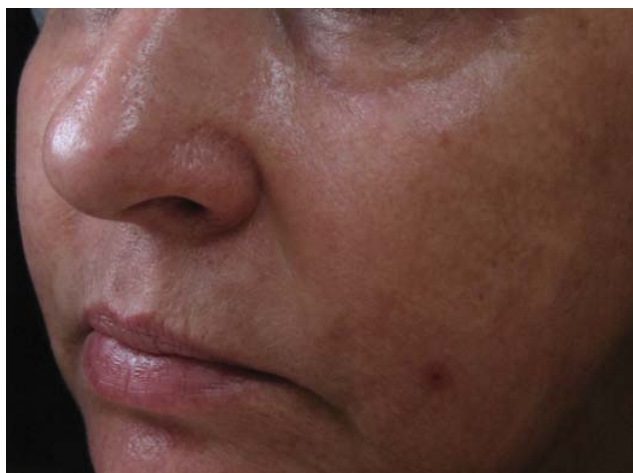

Figure 8 - Patient with hyperchromia 1 month after UltraPulse Encore CO₂ Laser Active FX Deep FX (Lumenis) session

TECHNIQUE

The procedure must be planned at least 30 days in advance. The time of the year is important – especially for patients with darker skin; an extended holiday is an excellent option. Modern fractional CO₂ equipments are very versatile, allowing the planning of lighter procedures in repeated sessions, or more aggressive ones, with a reduced number of sessions, if the phototype allows. It is important to obtaining a very detailed clinical history on a visit prior to the procedure, with a physical examination and laboratorial tests when necessary. Pictures should preferably be taken in advance, so that they are not forgotten on the day of the procedure. Pre-treatment use of topical medication such as sunscreen, vitamin C, tretinoin and/or glycolic acid can be useful to accelerate the healing process. Previous use of hydroquinone is quite debatable.¹²

The patient should have prescriptions for all products to be used after the procedure in hand, as well as written instructions. When palpebral region treatment is planned, intraocular protection should be put in place before starting the session. The skin should be carefully cleansed and dried so that no trace of anesthetic cream or water impairs the penetration and performance of the laser rays. The use of an aspirator is mandatory, and all people present in the room must wear protection glasses.

Parameters must be in place before the beginning of the session, and adjusted according to the patient's pain sensation. Each device has specific parameters and users must be qualified in advance to operate the equipment.

PERSONAL EXPERIENCE WITH THE ACTIVE FX® DEVICE (LUMENIS, YOKNEAM, ISRAEL)

Patients with altered pigmentation must receive less aggressive treatment, with sub-ablative parameters – fluence below 30 mj, squared pattern, and density 5 – that lead to a recovery time of 1 or 2 days. In patients with mild photoaging and non-facial areas to be treated, a slightly more aggressive approach is used, with a single pass at a fluence between 40 and 90 mj, squared

**Table 1: Active XL® device features Active XL®
(Lumenis, Yokneam, Israel)**

<i>Device specifications</i>	<i>Active Encore® (Lumenis, Yokneam, Israel)</i>
<i>Wavelength</i>	10,600 nm
<i>Laser type</i>	Ultrapulsed or continuous
<i>Spot size</i>	2,000 mm, 1,300 mm, 1,000 mm, 200 mm, 120 mm
<i>Available densities</i>	1-9
<i>Energy</i>	60 Watt
<i>% of coverage per pass</i>	5-100%
<i>Penetration depth</i>	up to 2,000 mm per pulse
<i>Options available</i>	Fractional, incisional, excisional
<i>Estimated time to treat the hemi-face</i>	10-20 minutes

pattern and density 3. Moderate and intense photoaged patients receive more aggressive treatment, if allowed by the phototype: fluence between 90 and 125 mj, squared pattern, and density 4 or 5. The periorbital region's thin skin must be treated with a maximum energy of 90 j. Multiple passes are not used in rejuvenation treatments: for the coverage of larger areas, the density is changed; the "cool scan" feature or non-sequential and non-adjacent scanning patterns are used to reduce excessive heating and possible side effects. In localized lesions (e.g., seborrheic keratoses), where greater destruction is necessary, continuous laser is used with multiple passes.

The heat sensation lingers for hours after the session. It is important to keep the patient in a ventilated place during that period, preferably with gusts of cool air from cooling devices, air conditioning and/or fans. Cool compresses are also recommended. Topical anesthetics are not used following the procedure due to the risk of toxicity, related to the increased penetration.

Biostimulation is the use of low intensity laser, or other sources of light such as LEDs, to reduce inflammation and stimulate healing.^{13,14} It must be started immediately after the session and repeated on alternate days until the skin is completely healed. In a standard treatment, each session is aimed at stimulating the renewal of 5-100% of the skin. From one to five sessions can be planned. More aggressive treatments require less repetition and longer intervals between sessions (1-3 months). Treatment is not limited to the face: skin areas with fewer annexes, such as the superior region of the thorax, neck, and back of the hands, can be treated with the proper care.^{10,11}

LESSONS LEARNED IN FRACTIONAL CO₂ LASER TREATMENT

- Average time to treat one side of the face: 20 minutes; neck or hands: 5 minutes. Preparation time before the session (cleaning and anesthesia of the face) and cooling time afterwards – which can be carried out in another room – must be added.
- Despite the use of topical anesthesia and/or nerve blocks, pain is considerable; a blast of cool air following the session relieves the discomfort.
- Since the cutaneous barrier will be removed, secretions and crusts are expected (special attention should be given to post-operative care).
- Patients can shave or use makeup 3 days after the session.
- Patients will need to abstain from everyday activities for 3-7 days. If the edema persists for longer than 1-5 days, a secondary infection must be excluded. The erythema lasts from 3-30 days, depending on the intensity of the parameters used.
- Sunscreen combined with healing creams or ointments, and cool compresses of saline solution or thermal water, are recommended in the post-operative period.
- Oral and topical corticosteroids help reduce erythema and the probability of post-inflammatory residual hyperpigmentation. Oral anti-herpetic therapy is necessary whenever there is a previous history of herpes simplex in the treated area or if the procedure is more aggressive. The use of prophylactic antibiotic is not recommended. The physician must, however, follow up with the patient daily to identify infections in their initial stage.
- One of the greatest difficulties in performing fractional CO₂ resurfacing is choosing the parameters. In case of doubt, one should test small areas and/or choose a less aggressive treatment, with the option of repeating it if results are less than expected.
- Non-facial regions are more susceptible to side effects.

REFERENCES

1. Patel CKN. Continuous-Wave Laser Action on Vibrational-Rotational Transitions of CO₂. *Physical Review*. 1964; 136 (5A): A1187–A1193.
2. Kirsch K, Zelickson B, Zachary C, Tope W. Ultrastructure of collagen thermally denatured by microsecond domain pulsed carbon dioxide laser. *Arch Dermatol*. 1998;134(10):1255-9.
3. Campos V, Mattos R, Fillipo A, Torezan LA. Laser no rejuvenescimento facial. *Surg Cosmet Dermatol*. 2009; 1(1): 29-35.
4. Ratner D, Tse Y, Marchell N, Goldman M, Fitzpatrick R, Fader D. Cutaneous laser resurfacing. *J Am Acad Dermatol*. 1999;41(3 pt 1):365-89.
5. Ross E, McKinlay J, Anderson R. Why does carbon dioxide resurfacing work? *Arch Dermatol*. 1999;135(4):444-54.
6. David L, Lask G, Glassberg E, Jacoby R, Abergel R. Laser abrasion for cosmetic and medical treatment of facial actinic damage. *Cutis*. 1989;43(4):583-7.
7. Anderson RR, Parrish J. Selective photothermolysis: precise microsurgery by selective absorption of the pulsed radiation. *Science*. 1983;220(4596):524–6.
8. Manstein D, Herron GS, Sink RK, Tanner H, Anderson RR. Fractional photothermolysis: a new concept for cutaneous remodeling using microscopic patterns of thermal injury. *Lasers Surg Med*. 2004;34(5):426-38.
9. Hantash BM, Bedi VP, Chan KF, Zachary CB. Ex vivo histological characterization of a novel ablative fractional resurfacing device. *Lasers Surg Med*. 2007;39(2):87-95.
10. Fife DJ; Fitzpatrick RE; Zachary CB. Complications of fractional CO₂ laser resurfacing: four cases. *Lasers Surg Med*. 2009;41(3):179-84.
11. Avram MM; Tope WD; Yu T; Szachowicz E; Nelson JS. Hypertrophic scarring of the neck following ablative fractional carbon dioxide laser resurfacing.. *Lasers Surg Med*. 2009;41(3):185-8.
12. West TB, Alster TS. Effect of pretreatment on the incidence of hyperpigmentation following cutaneous CO₂ laser resurfacing. *Dermatol Surg*. 1999;25(1):15-7.
13. Oliveira PC, Meireles GC, dos Santos NR, de Carvalho CM, de Souza AP, dos Santos JN, Pinheiro AL. The use of light photobiomodulation on the treatment of second-degree burns: a histological study of a rodent model. *Photomed Laser Surg*. 2008;26(4):289-99.
14. Erdle BJ, Brouxhon S, Kaplan M, Vanbuskirk J, Pentland AP. Effects of continuous-wave (670-nm) red light on wound healing. *Dermatol Surg*. 2008;34(3):320-5.
15. Saluja R, Khoury J, Detwiler SP, Goldman MP. Histologic and clinical response to varying density settings with a fractionally scanned carbon dioxide laser. *J Drugs Dermatol*. 2009;8(1):17-20.