



Acta Scientiae Veterinariae

ISSN: 1678-0345

ActaSciVet@ufrgs.br

Universidade Federal do Rio Grande do Sul
Brasil

Howes, Flávia; Schafer Da Silva, Aleksandro; de Lima Athayde, Cristiane; Machado Costa, Marcio;
Matoso Burgo Corrêa, Marcos; Simiano Tavares, Kaio Cesar; Miletti, Luiz Claudio; dos Anjos Lopes,
Sonia Terezinha; Santos do Amaral, Anne; Schmidt, Claudete
A New Therapeutic Protocol for Dogs Infected with *Trypanosoma evansi*
Acta Scientiae Veterinariae, vol. 39, núm. 3, 2011, pp. 1-4
Universidade Federal do Rio Grande do Sul
Porto Alegre, Brasil

Available in: <http://www.redalyc.org/articulo.oa?id=289022038017>

- How to cite
- Complete issue
- More information about this article
- Journal's homepage in redalyc.org

redalyc.org

Scientific Information System

Network of Scientific Journals from Latin America, the Caribbean, Spain and Portugal

Non-profit academic project, developed under the open access initiative

A New Therapeutic Protocol for Dogs Infected with *Trypanosoma evansi*

Flávia Howes¹, Aleksandro Schafer Da Silva¹, Cristiane de Lima Athayde¹, Marcio Machado Costa¹, Marcos Matoso Burgo Corrêa¹, Kaio Cesar Simiano Tavares², Luiz Claudio Miletto², Sonia Terezinha dos Anjos Lopes¹, Anne Santos do Amaral¹ & Claudete Schmidt¹

ABSTRACT

Background: Trypanosomosis is a disease caused by a flagellate protozoan known as *Trypanosoma evansi*, transmitted by hematophagous insects. It parasites showed a large diversity of mammalian hosts. Dogs may show clinical changes such as weight loss, progressive weakness, anorexia, anemia, intermittent fever, conjunctivitis, swelling of limbs and increased of superficial lymph nodes. Treatment of trypanosomosis relies on the use of diminazene aceturate which is effective for the treatment of disease in infected animals. However, a single dose of drug are not effective for horses, mules and dogs, since drug neither cross the blood-brain barrier or has insufficient doses to control the *T. evansi* infection. Therefore, the present study aimed to report the curative efficacy of a new therapeutic protocol, based on diminazene aceturate, for dogs infected with *T. evansi*.

Case: The treatment against trypanosomosis was performed in a dog, male, two years old, from the municipality of Uruguaiana, RS, Brazil. The animal showing clinical signs such as apathy, vomit, increase of left submandibular lymph node, edema of the left face and change of gait in the hind limbs when it was evaluated by veterinarians. The hematological and biochemical parameters revealed normocytic-hypochromic anemia, thrombocytopenia, hyperglobulinemia and hypoalbuminemia. Trypomastigotes of *T. evansi* were identified in blood smears stained by panoptic method. The parasitism by *T. evansi* was confirmed by blood inoculation in two rats (xenodiagnosis) and by PCR *T. evansi*-specific. The canine was treated with diminazene aceturate (intramuscular injection) using a dose of 3.5 mg kg⁻¹ for 5 days at 24h of intervals. After treatment the dog showed clinical signs of health improvement, and clinical signs disappeared after the seventh day of treatment. The parasite was not found in blood smears after the third day of treatment and PCR was negative on days 30 and 50 post-treatment. During the treatment signs of drug intoxication were not observed, as well as hepatic and renal functions were not affected. The animal showed normal biochemical and hematological parameters after 30 days of treatment.

Discussion: In this study, the treatment tested was effective, leading to the cure of the disease. Previously, the same protocol was used for cats experimentally infected with *T. evansi*, obtaining 85.7% (6/7) of curative efficacy. In a comparative study of doses of diminazene aceturate in rats infected with *T. evansi*, inefficiency and death of rats treated with a single dose of 3.5 and 7.0 mg kg⁻¹ were observed. In contrast, the cure in rats occurred when animals received a dose of 3.5 and 7.0 mg kg⁻¹ during five consecutive days. The return of the parasitemia after treatment may be related to the impossibility of the medicament pass through the blood-brain barrier or the doses is insufficient. Our data reveal that five-dose protocol obtained higher efficiency because it provided greater passage of drug molecules through blood-brain barrier, which could eliminate the parasite from brain. After treatment, all clinical signs disappeared, biochemical and hematological parameters returned to normal levels, allowing us to conclude that this new protocol tested was effective to cure of this disease in dogs.

Keywords: Trypanosomes, dog, treatment, natural infection, *T. evansi*.

INTRODUCTION

Trypanosomosis is a disease caused by a flagellate protozoan known as *Trypanosoma evansi*, transmitted by hematophagous insects of the genus *Stomoxys* and *Tabanus* [10]. It parasites showed a large diversity of mammalian hosts and is an important disease producing agent throughout the tropical and subtropical areas of the world [9,10]. Dogs may show clinical changes such as weight loss, progressive weakness, anorexia, anemia, intermittent fever, conjunctivitis, swelling of limbs and increased of superficial lymph nodes [2,3,8].

Treatment of trypanosomosis relies on the use of diminazene aceturate which is effective for the treatment of disease in cattle, buffalo, sheep, pigs and camels [13,14]. However, a single dose of drug are not effective for horses, mules and dogs [2,3,17], since diminazene aceturate neither cross the blood-brain barrier or has insufficient doses to control the *T. evansi* infection [11,15]. Therefore, the present study aimed to report the curative efficacy of a new therapeutic protocol, based on diminazene aceturate, for dogs infected with *T. evansi*.

CASE REPORT

The treatment against trypanosomosis was performed in a dog, male, two years old, from the municipality of Uruguaiana, RS, Brazil. The animal was received and examined in the Veterinary Hospital of Federal University of Santa Maria, in October 2010, showing clinical signs such as apathy, vomit, increase of left submandibular lymph node, edema of the left face and change of gait in the hind limbs when it was evaluated by veterinarians. The hematological and biochemical parameters revealed normocytic-hypochromic anemia (hematocrit 26%), thrombocytopenia (44000 / μ L), hyperglobulinemia and hypoalbuminemia when it was compared with references values [7]. The hepatic and renal function was not altered. Trypomastigotes of *T. evansi* were identified in blood smears stained by panoptic method (Figure 1).

The parasitism by *T. evansi* was confirmed by blood inoculation in two rats (xenodiagnosis), when in an average of six days post inoculation (PI) trypomastigotes were observed in blood smear of both rats. Another sample of dog's blood was preserved in ethanol (v/v) for DNA extraction and

confirmed (Figure 2) by PCR *T. evansi*-specific analysis [18]. The canine was treated with diminazene

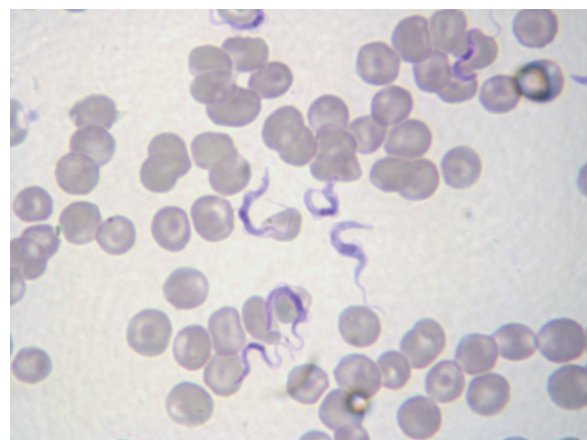


Figure 1. Trypomastigotes forms of *Trypanosoma evansi* observed in blood smears of dog, stained with Panoptic method. (Obj. 100x)

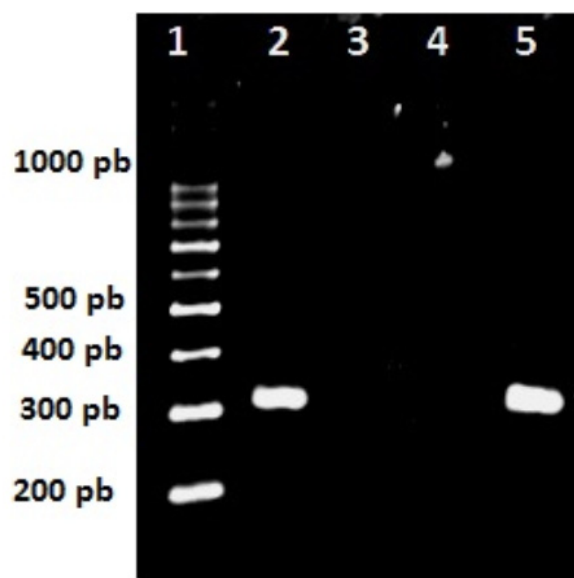


Figure 2. Diagnosis of *Trypanosoma evansi* in blood samples of a dog naturally infected using the PCR. (1) 100 pb ladder (Ludwig Biotec®), PCR result before treatment (2), PCR results on days 30 (3) and 50(4) days post treatment. Positive control DNA of *T. evansi* was used (5).

aceturate (intramuscular injection) using a dose of 3.5 mg kg⁻¹ for 5 days at 24h of intervals [4,5]. Fluid (physiological solution) was given for a period of 12 h after drug administration. Post-treatment, the parasitemia was estimated by microscopic examination of blood in stained smears. Alanine aminotransferase, alkaline phosphatase, urea, and creatinine were daily measured to assess toxicity of the drug. To prove the efficacy of the treatment PCR

T. evansi specific was carried out and repeated 30 and 50 days post-infection.

After treatment the dog showed clinical signs of health improvement, and clinical signs disappeared after the seventh day of treatment. The parasite was not found in blood smears after the third day of treatment and PCR was negative on days 30 and 50 post-treatment. During the treatment signs of drug intoxication were not observed, as well as hepatic and renal functions were not affected, since hepatic enzymes, urea and creatinine remained within normal limits. The animal showed normal biochemical and hematological parameters after 30 days of treatment.

DISCUSSION

Similar to the present study, the first record of canine trypanosomosis in southern of Brazil occurred in the municipality of Uruguaiana [2]. Subsequently, the disease was reported in dogs in different towns in the same State [3,8]. These animals were treated with a single dose of 3.5 mg kg⁻¹ of diminazene aceturate, however without curative efficacy and death of some animals treated. Ineffectiveness of diminazene aceturate already had been observed in bovines, horses and mules infected with *T. evansi* and *T. vivax* [6,16,17], and therefore, new treatment protocols are needed.

In this study, the treatment tested was effective, leading to the cure of the disease. Previously, the same protocol was used for cats experimentally infected with *T. evansi*, obtaining 85.7% (6/7) of curative efficacy [5]. In a comparative study of doses of diminazene aceturate in rats infected with *T. evansi*, inefficiency and death of rats treated with a single dose of 3.5 and 7.0 mg kg⁻¹ were observed. In contrast, the cure in rats occurred when animals

received a dose of 3.5 and 7.0 mg kg⁻¹ during 5 consecutive days [4]. The return of the parasitemia after treatment may be related to the impossibility of the medicament pass through the blood-brain barrier or the doses is insufficient, what thereby may creates a possible refuge for the trypanosomes during the systemic phase of the drug [12]. We believe that our five-dose protocol obtained higher efficiency because it provided greater passage of drug molecules through blood-brain barrier, which could eliminate the parasite from brain.

A relevant aspect to be considered is the absence of toxic effects of the treatment to the dog. The hepatic and renal functions remained normal during therapy, similar results were observed in a study with cats treated with five doses of diminazene aceturate [5]. Therefore, nothing prevents the use of this drug in treatment of dogs infected with *T. evansi*, though it is advisable to have a close monitoring of the animal during the therapy, as was done in this study.

The clinical signs and hematological findings initially presented by the dog in this study are usually observed in natural and experimental infection by *T. evansi* in dogs, cats, and horses [1-3,5,8,16,17]. However, the motor disturbance presented by that dog, a clinical sign already observed in cats [5], has been not previously reported in canine.

After treatment, all clinical signs disappeared, biochemical and hematological parameters returned to normal levels, allowing us to conclude that this new protocol tested was effective to cure of this disease in dogs.

Declaration of interest. The authors report no conflicts of interest. The authors alone are responsible for the content and writing of the paper.

REFERENCES

- 1 Brandão L.P., Larsson M.H.M.A., Birgel E.H., Hagiwara M.K., Ventura R.M. & Teixeira M.M.A. 2002. Infecção natural por *Trypanosoma evansi* em cão - relato de caso. *Clinica Veterinária*. 36(1): 23-26.
- 2 Colpo C.B., Monteiro S.G. & Stainki D.R. 2005. Infecção natural por *Trypanosoma evansi* em cão. *Ciência Rural*. 35(3): 717-719.
- 3 Da Silva A.S., Zanette R.A., Colpo C., Santurio J.M. & Monteiro S.G. 2008. Sinais clínicos em cães naturalmente infectados com *Trypanosoma evansi* (Kitenoplastida: Trypanosomatidae) no RS. *Clinica Veterinária*. 72(1): 66-68.
- 4 Da Silva A.S., Tochetto C., Zanette R.A., Pierezan F., Rissi D.R., Santurio J.M. & Monteiro S.G. 2008. Aceturato de diminazeno e dipropionato de imidocarb no controle de infecção por *Trypanosoma evansi* em *Rattus norvegicus* infectados experimentalmente. *Ciência Rural*. 38(5): 1357-1362.

- 5 Da Silva A.S., Zanette R.A., Lopes S.T.A., Santurio J.M. & Monteiro S.G. 2009.** Diminazene aceturate in the control of *Trypanosoma evansi* infection in cats. *Veterinary Parasitology*. 165: 47-50.
- 6 Da Silva A.S., Garcia H.A., Costa M.M., França R.T., Gasperi D., Zanette R.A., Teixeira M.G. & Monteiro S.G. 2011.** Horses naturally infected by *Trypanosoma vivax* in southern Brazil. *Parasitology Research*. 108(1): 23-30.
- 7 Feldman B.F., Zinkl J.G. & Jain N.C. 2000.** *Schalm's Veterinary Hematology*. 5th edn. Philadelphia: Lippincott/Williams & Wilkins, 1344p.
- 8 Franciscato C. Lopes S.T.A., Teixeira M.G. Monteiro S.G. & Paim C.B. 2007.** Cão naturalmente infectado por *Trypanosoma evansi* em Santa Maria, RS. *Ciência Rural*. 37(1): 288-229.
- 9 Herrera H.M., Davila A.M., Norek A., Abreu U.G., Souza S.S., Andréa O.S. & Jansen A.M. 2004.** Enzootiology of *Trypanosoma evansi* in Pantanal, Brazil. *Veterinary Parasitology*. 125(3-4): 263-275.
- 10 Hoare C.A. 1972.** *The Trypanosomes of Mammals: A Zoological Monograph*. Oxford: Blackwell, 560p.
- 11 Jenings F.W., Whitelaw D.D. & Urquhart G.M. 1977.** The relationship between duration of infection with *T. brucei* in mice and the efficacy of chemotherapy. *Parasitology*. 75(1): 145-153.
- 12 Kaminsky R. & Brun R. 1998.** *In vivo* and *In vitro* activities of trybazine hydrochloride against various pathogenic trypanosome species. *Antimicrobial Agents and Chemotherapy*. 42(11): 2858-2863.
- 13 Peregrine A.S. & Mamman M. 1993.** Pharmacology of diminazine: a review. *Acta Tropica*. 54(1): 185-203.
- 14 Sirivan C., Pramoolsinsap T. & Pemayodhin P. 1994.** Effect of diminazene aceturate and isometamidium chloride on the control of *Trypanosoma evansi* in naturally infected sow. *Thailand Journal Health Research*. 8(1): 101-109.
- 15 Spinosa H.S., Górnica S.L. & Bernardi M.M. 1999.** *Farmacologia aplicada à medicina veterinária*. Rio de Janeiro: Guanabara koogan, 646p.
- 16 Silva R.A.M.S., Seidl A., Ramirez L. & Dávila A.M.R. 2002.** *Trypanosoma evansi* e *Trypanosoma vivax*: *biologia, diagnóstico e controle*. Corumbá: Embrapa Pantanal, 162p.
- 17 Tuntasuvan D., Jarabrum W., Viseshakul N., Mohkaew K., Borisutsuwan S., Theeraphan A. & Kongkanjana N. 2003.** Chemotherapy of surra in horses and mules with diminazene aceturate. *Veterinary Parasitology*. 110(3): 227-233.
- 18 Ventura R.M., Takeda G.F., Silva R.A.M.S., Nunes V.L.B., Buck G.A. & Teixeira M.M.G. 2002.** Genetic relatedness among *Trypanosoma evansi* stocks by random amplification of polymorphic DNA and evaluation of a synapomorphic DNA fragment for species-specific diagnosis. *International Journal for Parasitology*. 32(1): 53-63.