



Acta Scientiae Veterinariae

ISSN: 1678-0345

ActaSciVet@ufrgs.br

Universidade Federal do Rio Grande do  
Sul  
Brasil

Morata Raposo-Ferreira, Talita Mariana; Jark, Paulo Cesar; Rossi Varallo, Giovanna;  
Borin-Crivellenti, Sofia; Tinucci-Costa, Mirela; Laufer-Amorim, Renée; Barboza De Nardi,  
Andrigo

T-Cell Lymphoma in the Tongue of a Dog with Cutaneous and Striated Forelimb Muscle  
Involvement

Acta Scientiae Veterinariae, vol. 42, 2014, pp. 1-6

Universidade Federal do Rio Grande do Sul

Porto Alegre, Brasil

Available in: <http://www.redalyc.org/articulo.oa?id=289039188023>

- How to cite
- Complete issue
- More information about this article
- Journal's homepage in redalyc.org

redalyc.org

Scientific Information System

Network of Scientific Journals from Latin America, the Caribbean, Spain and Portugal

Non-profit academic project, developed under the open access initiative

## T-Cell Lymphoma in the Tongue of a Dog with Cutaneous and Striated Forelimb Muscle Involvement

Linfoma de células T em língua de cão com envolvimento cutâneo e de musculatura estriada de membro torácico

Talita Mariana Morata Raposo-Ferreira<sup>1</sup>, Paulo Cesar Jark<sup>1</sup>, Giovanna Rossi Varallo<sup>1</sup>, Sofia Borin-Crivellenti<sup>1</sup>, Mirela Tinucci-Costa<sup>1</sup>, Renée Laufer-Amorim<sup>2</sup> & Andriago Barboza De Nardi<sup>1</sup>

### ABSTRACT

**Background:** Primary tongue tumors rarely affect dogs and correspond to 4% of tumors involving the oropharynx. Until now, primary tongue lymphoma had not been reported. However, lymphoma involvement in the skeletal muscle, although quite unusual, was described in the literature in four cases. Cutaneous lymphoma is another rare extranodal manifestation. The objective of this report is to describe a case of T immunophenotype lymphoma occurrence, whose manifestation is atypical, not only because it is situated in the tongue muscle but also because of the subsequent involvement of the striated musculature of the left forelimb and the skin, which showed unfavorable evolution.

**Case:** A female seven-year-old mongrel was seen showing a regular lump in the base of the tongue, 3 cm in diameter, not ulcerated and of firm consistency, with halitosis as the only clinical sign of the disease. Incisional biopsy of the lump was performed and histopathology verified that it was large cell lymphoma. The material was sent for immunohistochemical evaluation and was characterized as T immunophenotype lymphoma by positive CD3 and negative CD79a marking. The CHOP (cyclophosphamide, doxorubicin, vincristine and prednisone) chemotherapy protocol was established as treatment and after the first chemotherapy session there was partial remission of the mass, measuring 2 cm in diameter. The lump, however, remained stable in the following sessions. Thirty days after the diagnosis of lymphoma, the animal began to show lameness of the left forelimb and swelling near the head of the left humerus. A muscle mass, firm in consistency, progressing fast, presented a significant increase, just three weeks after its appearance. Two skin lesions, arcuate, erythematous and pruritic also appeared in the dorsocervical and ventral-abdominal region. Incisional biopsy of these lesions was performed and the histopathological diagnosis confirmed muscle and cutaneous large cell lymphoma and immunophenotype compatible with T cells (positive CD3 and negative CD79a). Due to disease advance, even during chemotherapy, a rescue protocol of L-asparaginase administration followed by lomustine and prednisone was proposed. Even with the rescue protocol there was no remission of the tumors and the case was classified as progressive. The animal of this report died after completing the first cycle of chemotherapy protocol, with a survival of 92 days.

**Discussion:** Despite the fact that clinical behavior of primary lymphoma in dogs' skeletal muscle is unknown, it is believed that, as in humans, it can be associated with chronic inflammation or neoplastic cell invasion by proximity of the tumor or metastasis, which could justify the dissemination of the lymphoma reported here from the tongue to other tissues. However, appearance of concurrent independent lymphomas cannot be ruled out. As observed in the three cases of primary muscular lymphoma, the dog of this report had low response to therapy and short survival. This report presents the first case of lymphoma in tongue with subsequent skin and left forelimb skeletal muscle involvement described in the literature. The clinical outcome corroborates the aggressiveness of muscular lymphoma observed in the other reports and also suggests that both tongue and other skeletal muscle tumors should be included in the differential diagnosis of canine lymphoma.

**Keywords:** dog, lymphoma, tongue, skeletal muscle.

**Descritores:** cão, linfoma, língua, músculo esquelético.

## INTRODUCTION

Primary neoplasms of the tongue are extremely rare, accounting for about 4% of all tumors that involve the oropharynx, the most commonly found in the tongue being the squamous cell carcinoma [2], followed by melanoma [4].

Other tumors have been described, although less often, like papilloma, rhabdomyoma, rhabdomyosarcoma, hemangioma, hemangiosarcoma, granular cell tumors, histiocytoma, plasmacytoma, mast cell tumor, fibrosarcoma, chondrosarcoma and liposarcoma [2,3,5,6,10,12,13].

Despite the occurrence of lymphoma in the tongue having already been described as a possible oral cavity extranodal manifestation [11], we found no reported case on this primary involvement. In general, the involvement of striated skeletal muscle by lymphoma is quite unusual, both in humans and in dogs, probably because typical skeletal muscle does not contain lymphoid tissue [8,16].

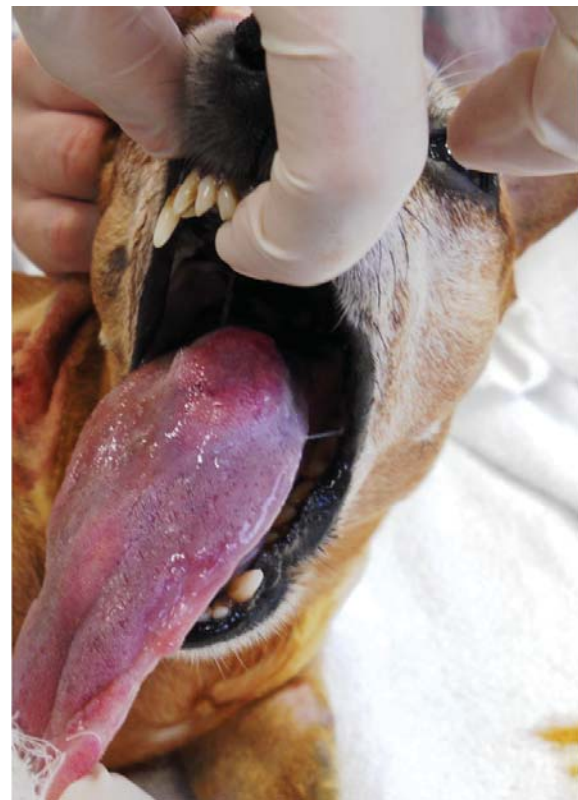
Four cases of lymphoma in skeletal muscle have been reported to this date [1,8,14,15]. The association of cutaneous lymphoma with skeletal muscle tissue has also been described [1]. Cutaneous lymphoma is another, rather uncommon, extranodal manifestation, accounting for approximately 3-8% of lymphoma cases affecting dogs [18].

The aim of this study was to report a case of lymphoma with atypical manifestations, in the skeletal muscle of the tongue and involving the striated muscle of the left forelimb and the skin, and with a very aggressive course and little responsive to antineoplastic chemotherapy. From the reviewed literature, this is the first case of primary tongue lymphoma with subsequent involvement of the forelimb skeletal muscle and skin.

## CASE

A female, seven years old mongrel, weighing 4 kg was seen. The animal showed a volume increase at the base of the tongue, during a periodontal disease treatment a week earlier. Upon inspection of the patient's oral cavity, the mass was found to be regular, 3 cm in diameter, not ulcerated and of firm consistency (Figure 1). The only clinical sign of the patient was halitosis.

Complete blood count and serum biochemistry (creatinine, urea, alanine aminotransferase and alkaline phosphatase) analyses results were within the normal range for the species, and imaging tests (chest radiography and abdominal ultrasonography) revealed no changes in other organs.



**Figure 1.** Female mongrel, seven years old, with a nodule in the tongue base, regular, non-ulcerated, 3 cm in diameter.

Subsequently, the patient underwent incisional biopsy for histopathological analysis, and large cell lymphoma was diagnosed (Figure 2). Immunohistochemical analysis of the lingual nodule was performed using anti-human CD3 polyclonal antibody<sup>1</sup> and anti-human CD79a monoclonal antibody<sup>1</sup>. Antigen retrieval was performed using citrate buffer, pH 6.0, in pressure cooker (Pascal®)<sup>1</sup> for 20 min. The blocking of endogenous peroxidase was performed in methyl alcohol solution of 8% hydrogen peroxide. The primary antibody was incubated for 18 hours at 4°C, followed by incubation with Advance HRP polymer and application of the chromogen 3,3'-diaminobenzidine<sup>1</sup> for 5 min. The sections were counterstained with Harris hematoxylin for 40 s. The marking was positive for CD3 and negative for CD79a, confirming the diagnosis of T-cell lymphoma (Figure 3).

Once lymphoma was diagnosed, the CHOP protocol began. After the first treatment session, with administration of vincristine<sup>2</sup> (0.7 mg/m<sup>2</sup>/IV), partial remission was noted and the lump in the tongue decreased to 2 cm in diameter. The animal remained stable during subsequent sessions, and no hematological changes were observed during the evaluation before chemotherapy. Returning for the fourth treatment session, 30 days after diagno-

sis, the patient presented lameness of the left forelimb and soreness next to the humeral head, without having trauma history or reports of previous illness. Limb lateral and cranial ventral radiography showed no bone or joint involvement, only a slight increase of adjacent soft tissue.

When the patient returned three weeks later, we found a significant increase in the forelimb muscle mass, of firm consistency (Figure 4), and two arcuate, erythematous, and pruritic skin lesions, on the right dorsocervical and ventral abdominal area (Figure 5). Thus, incisional biopsy of the muscles and the skin lesions was performed. The histopathological diagnosis

of the lesions revealed a large cell lymphoma, and immunohistochemical analysis was positive for T cells (CD3 positive, CD79a negative).

Therefore, the first chemotherapy protocol was replaced by combination treatment of L-asparaginase<sup>3</sup> (400 IU/kg, subcutaneously, weeks 1 and 4), lomustine<sup>4</sup> (70 mg/m<sup>2</sup> via orally, week 1) and prednisone<sup>5</sup> (2 mg/kg, every 24 h, orally, with weekly dose reduction up to 1 mg/kg). However, until the patient's natural death after the first treatment cycle, no remission of cancer was observed. The patient had a survival of 92 days.

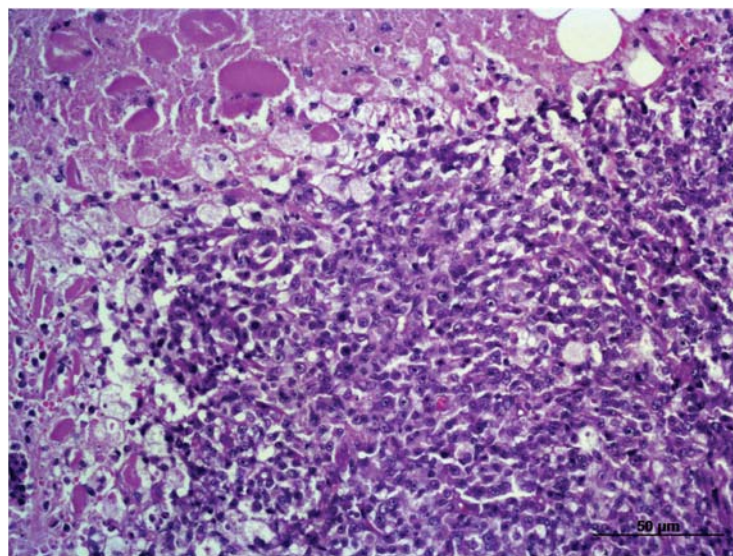


Figure 2. Large cell Lymphoma in the base of the dog's tongue (HE, x200).

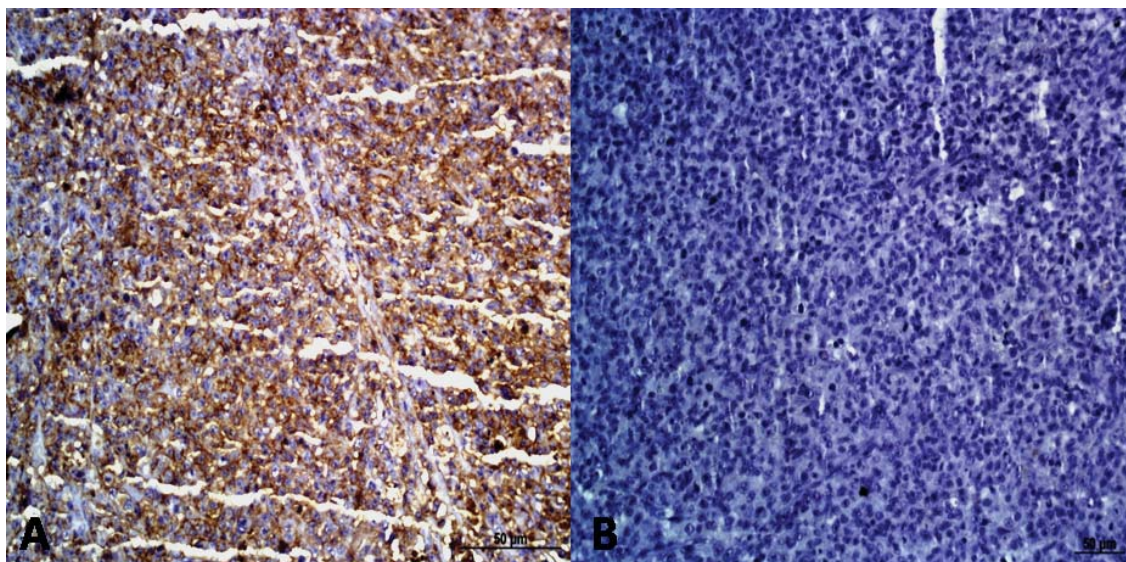
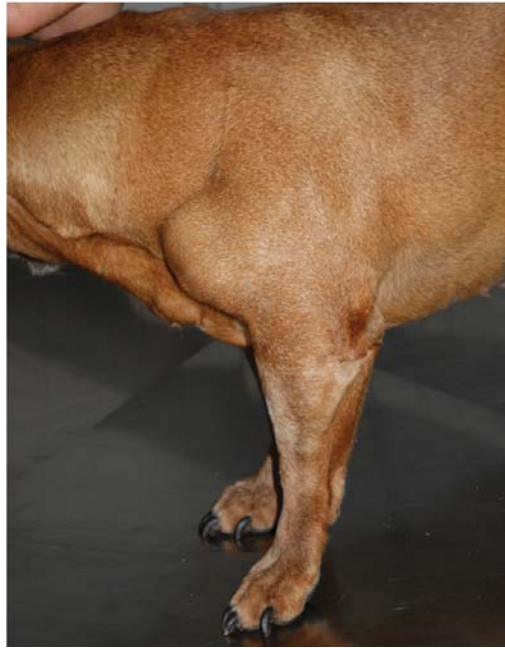
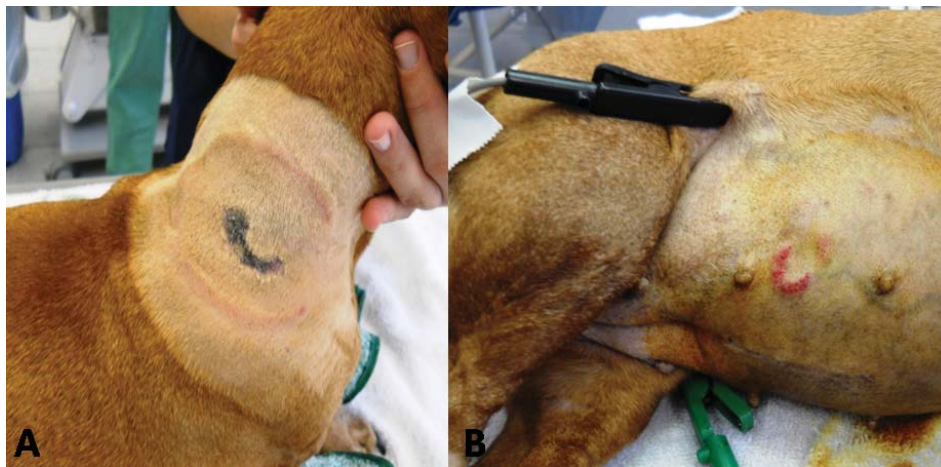


Figure 3. A. Positive T lymphocyte immunophenotyping (CD3+) [x200]. B. Negative marking of B cells (CD79a-).



**Figure 4.** Muscle mass of the left forelimb, with rapid progression.



**Figure 5.** Arcuate, erythematous cutaneous lesions. A. Dorsocervical region. B. Ventral abdominal region.

#### DISCUSSION

The clinical behavior of skeletal muscle primary lymphoma in dogs is unknown [14]. In humans, it is believed that chronic inflammation is related to the carcinogenic process [9]. Another suspected mechanism could be through the invasion of cancer cells from a pre-existing site, by proximity or metastasis [15]. This is the first case of lymphoma manifestation in the tongue, possibly primary, which also culminated with cutaneous and left forelimb skeletal muscle involvement.

The other four cases of muscular lymphoma described in the literature involved forelimbs and hindlimbs, cervical muscles and one was a diffuse

manifestation associated to polymyopathy [1,8,14,15]. In one of them a previous appearance of cutaneous lymphoma was also observed [1], whereas in this case it developed after the muscle lymphoma.

Lymphoma muscle involvement may manifest as a single mass or in diffuse form, the latter being rather unusual, and may even be related to a polymyopathy [1,15].

Thuilliez *et al.* [15] showed, during necropsy, that the mass previously manifested in the cervical muscles had invaded other structures, such as the left forelimb, tongue and laryngeal muscles, suggesting a progression of the disease by proximity. The case described had no previous history of trauma or an illness

to justify a possible inflammation as a predisposing factor for the development of lymphoma, suggesting the involvement by metastatic neoplastic cell invasion, even more so, since all masses have been characterized as large cell T-lymphoma. However, one cannot rule out the concomitant emergence of independent lymphomas [1].

The muscle lymphoma cases reported were mostly males, aged between 16 months and eight years. Three animals were large and one midsize [1,8,14,15]. The dog of this report, however, was female, seven years old and small breed.

Surgical resection is the best treatment for lingual tumors [5]. However, once lymphoma is considered a systemic disease and responsive to chemotherapy, it is treated conservatively through the combination of multiple anticancer agents for better response and disease control [17]. However, T-cell tends to be more aggressive than B-cell lymphoma with a poorer prognosis [7].

As in cutaneous lymphoma [11], low survival was observed in most muscular lymphoma cases, being related mainly to high-grade and T-cell lymphomas [1,15]. Only the case described by Takeuchi *et al.* [14]

presented a low grade T lymphoma with a survival of 713 days. The case at hand also had a short survival, since it demonstrated rapid progression and the chemotherapy treatments were ineffective.

This case illustrates an atypical case of lingual lymphoma, which culminated with cutaneous and left forelimb skeletal muscle involvement, and which showed aggressive behavior, corroborating other reports of lymphoma cases with muscle involvement. Tongue and skeletal muscle masses should be considered in lymphoma differential diagnosis. New forms of treatment must be explored to improve survival of these patients with an atypical presentation of the disease.

#### SOURCES AND MANUFACTURERS

<sup>1</sup>DakoCytomation, Manchester, UK.

<sup>2</sup>Oncovin®, ABL, Cosmópolis, SP, Brazil.

<sup>3</sup>Elspar®, Lundbeck, Rio de Janeiro, RJ, Brazil.

<sup>4</sup>CeeNU®, Bristol-Mayers Squibb, Santo Amaro, SP, Brazil.

<sup>5</sup>Prednisona®, Legend, São Paulo, SP, Brazil.

**Declaration of interest.** The authors report no conflicts of interest. The authors alone are responsible for the content and writing of the paper.

#### REFERENCES

- 1 Bennett S.L., Slocombe R.F., Holloway S.A., Charles J.A. & Sandy J.R. 2005.** Lymphoma(s) showing epitheliotropism and diffuse skeletal muscle involvement presenting as a polymyopathy in a young dog. *Australian Veterinary Journal*. 83(10): 612-615.
- 2 Brockus C.W. & Myers R.K. 2004.** Multifocal rhabdomyosarcomas within the tongue and oral cavity of a dog. *Veterinary Pathology*. 41(3): 273-274.
- 3 Burton J.H., Powers B.E. & Biller B.J. 2012.** Clinical outcome in 20 cases of lingual hemangiosarcoma in dogs: 1996-2011. *Veterinary Comparative Oncology*. doi: 10.1111/j.1476-5829.2012.00351.x.
- 4 Culp W.T., Ehrhart N., Withrow S.J., Rebhun R.B., Boston S., Buracco P., Reiter A.M., Schallberger S.P., Aldridge C.F., Kent M.S., Mayhew P.D. & Brown D.C. 2013.** Results of surgical excision and evaluation of factors associated with survival time in dogs with lingual neoplasia: 97 cases (1995-2008). *Journal of the American Veterinary Medical Association*. 242(10): 1392-1397.
- 5 Daleck C.R., De Nardi A.B., Silva V.M.C., Eurides D. & Silva L.A.F. 2007.** Neoplasias de língua em cinco cães. *Ciência Rural*. 37(2): 578-582.
- 6 Dennis M.M., Ehrhart N., Duncan C.G., Barnes A.B. & Ehrhart E.J. 2006.** Frequency of and risk factors associated with lingual lesions in dogs: 1,196 cases (1995-2004). *Journal of the American Veterinary Medical Association*. 228(10): 1533-1537.
- 7 Fan T.M. 2003.** Lymphoma updates. *Veterinary Clinics of North America-Small Animal*. 33(3): 455-471.
- 8 Harkin K.R., Kennedy G.A., Moore W.E. & Schoning P. 2000.** Skeletal muscle lymphoma in a bullmastiff. *Journal of the American Animal Hospital Association*. 36(1): 63-66.
- 9 Masaoka S. & Fu T. 2002.** Malignant lymphoma in skeletal muscle with rhabdomyolysis: a report of two cases. *Journal of Orthopaedic Science*. 7(6): 688-693.
- 10 Megid J., Dias Junior J.G., Aguiar D.M., Nardi Júnior G., Silva W.B. & Ribeiro M.G. 2001.** Tratamento da papilomatose canina com *Propionibacterium acnes*. *Arquivo Brasileiro de Medicina Veterinária e Zootecnia*. 53(5):

574-576.

- 11 Moore P.F., Affolter V.K., Graham P.S. & Hirt B. 2009.** Canine epitheliotropic cutaneous T-cell lymphoma: an investigation of T-cell receptor immunophenotype, lesion topography and molecular clonality. *Veterinary Dermatology*. 20(5/6): 569-576.
- 12 Piseddu E., De Lorenzi D., Freeman K. & Masserdotti C. 2011.** Cytologic, histologic, and immunohistochemical features of lingual liposarcoma in a dog. *Veterinary Clinical Pathology*. 40(3): 393-397.
- 13 Silva A.E., Moreira E.L.T., Ocarino N.M., Franco A.L., Santos A.P., Souza T.S. & Serakides R. 2007.** Condrosarcoma primário de língua em cão. *Arquivo Brasileiro de Medicina Veterinária e Zootecnia*. 59(2): 530-532.
- 14 Takeuchi Y., Fujino Y., Goto-koshino Y., Ohno K., Uchida K., Nakayama H. & Tsujimoto H. 2010.** Long term survival of primary skeletal muscle lymphoma in a miniature dachshund. *Journal of Veterinary Medical Science*. 72(5): 673-677.
- 15 Thuilliez C., Watrelot-Virieux D., Chanut F., Fournel-Fleury C., Ponce F. & Marchal T. 2008.** Presumed primary muscular lymphoma in a dog. *Journal of Veterinary Diagnostic Investigation*. 20(6): 824-826.
- 16 Travis W.D., Banks P.M. & Reiman H.M. 1987.** Primary extranodal soft tissue lymphoma of the extremities. *American Journal of Surgical Pathology*. 11(5): 359-366.
- 17 Vail D.M., Pinkerton M.E. & Young K.M. 2012.** Hematopoietic Tumours. In: Withrow S.J., Vail D.M. & Page R.L. (Eds). *Small Animal Clinical Oncology*. 5th edn. St Louis: Elsevier, pp.622-627.
- 18 Vonderhaar M.A. & Morrison W.B. 2002.** Lymphosarcoma. In: Morrison W.B. (Ed). *Cancer in Dogs and Cats: Medical and Surgical Management*. 2nd edn. Jackson Hole: Teton NewMedia, pp.641-670.