



Revista Brasileira de Cirurgia
Cardiovascular/Brazilian Journal of
Cardiovascular Surgery

ISSN: 0102-7638

revista@sbccv.org.br

Sociedade Brasileira de Cirurgia
Cardiovascular

Yuan, Shi-Min

Anomalous origin of coronary artery: taxonomy and clinical implication

Revista Brasileira de Cirurgia Cardiovascular/Brazilian Journal of Cardiovascular Surgery,

vol. 29, núm. 4, octubre-diciembre, 2014, pp. 622-629

Sociedade Brasileira de Cirurgia Cardiovascular

São José do Rio Preto, Brasil

Available in: <http://www.redalyc.org/articulo.oa?id=398941895021>

- How to cite
- Complete issue
- More information about this article
- Journal's homepage in redalyc.org

redalyc.org

Scientific Information System

Network of Scientific Journals from Latin America, the Caribbean, Spain and Portugal

Non-profit academic project, developed under the open access initiative

Anomalous origin of coronary artery: taxonomy and clinical implication

Origem anômala da artéria coronária: taxonomia e implicação clínica

Shi-Min Yuan¹, MMed, PhD

DOI: 10.5935/1678-9741.20140109

RBCCV 44205-1597

Abstract

Objective: Anomalous origin of coronary artery is uncommon. The taxonomies of anomalous origin of coronary artery are inconsistent and complex. Conceptual and therapeutic debates remain. The aim of the present study is to reappraise the concept of anomalous origin of coronary artery and to discuss the potential hazards and treatment rationale of this anomaly on basis of literature review.

Methods: A comprehensive literature review was made in terms of the taxonomies including “simple”, “multiple” and “complex” types of anomalous origin of coronary artery.

Results: Anomalous origin of coronary artery can be simply categorized according to the ectopically originated coronary artery. There are a couple of complex anatomical variants: “multiple” type, involving more than one coronary artery or branch, which can be subdivided into 2 subtypes, A) more than one coronary arteries or branches arising from one place; and B) two coronary arteries/branches arising from separate ectopic sites; and “complex” type, associated with acquired heart disease, or congenital heart defects.

Conclusion: Sudden cardiac death in anomalous origin of coronary artery is associated with the anatomical features including abnormal coursing, acute angle take-off and ostial abnormalities. Atherosclerosis is prone to be in the right-sided ectopic and retroaortic coursing coronary artery. Surgical treatment is a definitive therapy. Simple coronary artery bypass grafting is not recommended due to the potential hazards of coronary steal phenomenon and poor patency of mammary arterial grafts, and modified maneuvers such as coronary ostial reimplantation, impinged coronary segment unroofing and coronary stent deployment are advocated instead.

Descriptors: Classification. Coronary Artery Disease. Coronary Vessels. Death, Sudden, Cardiac.

Resumo

Objetivo: A origem anômala da artéria coronária é incomum. As taxonomias de origem anômala da artéria coronária são inconsistentes e complexas. Os debates conceituais e terapêuticos permanecem. O objetivo do presente estudo é reavaliar o conceito de origem anômala da artéria coronária e discutir os riscos potenciais e fundamentos para o tratamento desta anomalia, com base em revisão de literatura.

Métodos: A revisão da literatura foi feita com termos das taxonomias, incluindo origem anômala da artéria coronária “simples”, “múltipla” e “complexa”.

Resultados: A origem anômala da artéria coronária pode ser simplesmente classificada de acordo com a origem ectópica da artéria coronária. Há um par de variações anatômicas complexas: “múltipla”, envolvendo mais de uma artéria coronária ou ramo, que podem ser subdivididos em dois subtipos: A) mais de uma das artérias coronárias ou ramos decorrentes de um lugar; e B) duas artérias coronárias/ramos decorrentes de sítios ectópicos separados; e tipo “complexo”, associado à doença cardíaca adquirida ou defeitos cardíacos congênitos.

Conclusão: A morte súbita cardíaca de origem anômala da artéria coronária está associada com as características anatômicas incluindo curso anormal, descolamento de ângulo agudo e anormalidades ostiais. A aterosclerose é propensa a ocorrer na artéria coronária ectópica e retroaórtica, do lado direito. O tratamento cirúrgico é uma terapia definitiva. Revascularização do miocárdio simples não é recomendada devido aos riscos potenciais do fenômeno de “roubo” do fluxo coronário e patência ruim dos enxertos com a artéria torácica interna. Manobras modificadas como reimplante ostial coronário, destelhamento do segmento coronário impingido e implantação de stent coronário são defendidas em seu lugar.

Descritores: Classificação. Doença da Artéria Coronariana. Vasos Coronários. Morte Súbita Cardíaca.

¹The First Hospital of Putian, Teaching Hospital, Fujian Medical University, Putian, Fujian Province, People's Republic of China.

This study was carried out at First Hospital of Putian, Teaching Hospital, Fujian Medical University, Putian, Fujian Province, People's Republic of China.

No financial support.

Correspondence address:

Shi-Min Yuan

Longdejing Street, 389 - Chengxian District, Putian, Fujian Province, People's Republic of China

E-mail: shi_min_yuan@yahoo.com

Article received on July 14th, 2014

Article accepted on September 14th, 2014

Abbreviations, acronyms & symbols	
LAD	Left anterior descending artery
LCA	Left coronary artery
LCx	Left circumflex artery
LM	Left main coronary artery
LVOT	Left ventricular outflow tract
RCA	Right coronary artery

INTRODUCTION

Coronary artery anomalies are uncommon but potentially lethal with an incidence of about 1% in patients for coronary angiography^[1]. Anomalous origin of coronary artery is a common type of congenital coronary artery anomaly. However, the taxonomies of anomalous origin of coronary artery are inconsistent and complex without any homogeneity in terms of the conceptual extensions. Different classifications of anomalous origin of coronary artery have been proposed by different authors, including single coronary artery, split coronary ostium, absent left main coronary artery, hypoplastic coronary artery, anomalous location of coronary ostia and anomalies of intrinsic coronary arterial anatomy^[2]. In addition, distinctions between anomalous origin and normal variant of coronary artery have not been well described^[3]. A taxonomy, which elaborates the anomalous origin of coronary artery in detail, is scanty. Moreover, the anomalous origin of coronary artery has significant clinical implications due to its association with myocardial ischemia^[4,5], lethal arrhythmia^[6] and even sudden cardiac death^[7]. In some patients, atherosclerotic coronary artery disease or valvular heart disease can be associated with anomalous origin of coronary artery^[8]. Accordingly, this lesion is often called a “malignant” coronary artery anomaly^[9]. The clinical implications of anomalous origin of coronary artery in relation to the anatomic features remain to be elaborated. Detailed knowledge of the anatomies of the coronary artery variations would be necessary for the diagnosis and treatment of the underlying heart diseases^[10]. The aim of the present study is to reappraise the concept of anomalous origin of coronary artery and to discuss the potential hazards and treatment rationale of this anomaly on basis of literature review.

DEFINITIONS

The right coronary artery (RCA), left coronary artery (LCA), left anterior descending (LAD) and left circumflex (LCx) arteries are defined as “arteries”, while the more distal coronary vessels are defined as “branches”^[3]. Moreover, before talking about anomaly, it is necessary to make clear the concepts of “normal” and “normal variants”. Normal is defined as a morphologic finding >1%, normal variant is an

unusual morphologic finding >1%, and anomaly is a morphologic finding <1% of the general population^[11].

Both LAD and LCx separately originating from the left coronary cusp with an absence of a left main coronary artery (LM) and the conal branch arising from the right coronary cusp are regarded as normal variants^[3]. However, a septal branch arising from the aorta is an anomaly^[12]. Based on these definitions, some classifications of anomalous origin of coronary artery that involving absence of the left main stem are wrong^[13].

Taxonomies

There have been many ways of taxonomies of anomalous origin of coronary artery. Firstly, it can be simply categorized according to the ectopically originated coronary artery. Based on large patient population studies, it has been recognized that the LCx is the most common to be ectopically originated followed by single coronary artery, and ectopic LCA, LAD and RCA accounting for 58.3%, 12.5%, 10.4%, 10.4% and 8.5%, respectively^[14]. In a total of 23,300 coronary angiograms, the incidence of the anomalous coronary arteries was 0.4%: LCx (46, 47%), RCA (25, 25.5%), LM (10, 10.2%), LAD (3, 3.1%), single coronary arteries (3, 6.1%) and other anomalies (8, 8.2%)^[15]. In another series with 24,959 patients with coronary angiograms, 73 (0.3%) had major coronary artery anomalies: 70 (95.9%) had one coronary anomaly and 3 (4.1%) had two coronary anomalies. The most common anomaly involved the LCx (60%), 69% of which arose from a separate ostium in the right coronary sinus and 31% as a branch of the RCA^[16].

The most frequent categorical method is that of the ectopic origin site, which involves ectopic origin of coronary artery from, 1) the aorta, either from a wrong sinus or beyond the sinuses; 2) the pulmonary artery; 3) as a branch of another coronary artery; 4) other arteries; and 5) the ventricular chamber (Table 1). Ectopic aortic origin is the most common type, of which an anomalous origin from a wrong sinus of Valsalva predominates (Figures 1-3)^[17,18].

There are a couple of complex anatomical variants with regard to the categories of the ectopic origin of coronary artery: “multiple” type, involving more than one coronary artery or branch, which can be subdivided into 2 subtypes: A) more than one coronary artery or branch arising from one place; and B) two coronary arteries/branches arising from separate ectopic sites^[19]; and “complex” type, associated with acquired heart disease (coronary artery disease or valve disorder), or congenital heart defects (common or uncommon).

Clinical Implications

The most frequent indication for coronary angiography is angina (43.9%)^[15]. As a branch of another coronary artery, anomalous origin of LCA from the proximal RCA may cause severe angina even at rest, which can be an indication for coronary artery bypass grafting^[20].

Table 1. Categories of the ectopic origin of coronary artery.

Ectopic origin site
From the aorta
<ul style="list-style-type: none"> • Left main coronary artery arising from the right anterior sinus • Right coronary artery originating from the left coronary sinus • Left circumflex or left anterior descending coronary artery arising from the right coronary sinus • A single coronary artery arising from the right, left and/or non-coronary sinus • Ascending aorta (high aortic origin) • Descending aorta
From the pulmonary artery
<ul style="list-style-type: none"> • Left coronary artery arising from the pulmonary artery (Bland-White-Garland syndrome) • Right coronary artery arising from the pulmonary artery • Left anterior descending coronary artery arising from the pulmonary artery • Both left and right coronary arteries arising from the pulmonary artery
As a branch of another coronary artery
<ul style="list-style-type: none"> • Left coronary artery from the proximal right coronary artery • Left circumflex coronary artery from a right coronary artery • Right coronary artery as a branch of the left circumflex coronary artery • Right coronary artery arising from the left anterior descending artery
From other arteries
<ul style="list-style-type: none"> • Innominate artery • Branchiocephalic trunk • Left mammary artery • Left subclavian artery • Carotid artery • Bronchial artery
From the left ventricle

Origin of coronary artery arising from the innominate artery can be the cause of syncope^[21] or chest pain in adults^[22,23]. Origin of the right coronary artery from the descending thoracic aorta may be associated with atypical and striking elastotic changes and wall thickening of the coronary artery as the underlying pathogenesis of severe consequences^[24]. The circulatory symptoms may also derived from ectopic coronary arterial course between the pulmonary trunk and aorta in spite of the lack of the atherosclerotic plaques in the coronary artery^[25]. Anomalous origin of coronary artery can be associated with common congenital heart defect^[26], or with rare congenital heart defect like cervical aortic arch^[27]. Robiseck^[28] reported such a case in a 4-year-old boy associated with tetralogy of Fallot which was successfully repaired without any postoperative complications. Anomalous origin of coronary artery from other arteries other than coronary is often associated with more complex congenital heart defects and the treatment is more challenging and the prognosis is poorer^[29]. Total anomalous origin of coronary arteries from the pulmonary artery can be isolated or combined with other congenital heart defects. It is often considered a cause of neonatal and infantile death with congenital coronary anomalies as a result of hypoxia due to the insufficient flow to the myocardium under lower pressure. Hoganson et al.^[30] reported a neonatal death due to a single coronary artery arising from the pulmonary artery died at 10 day of life. Bharati et al.^[31] reported an infant with total anomalous origin of coronary artery from the pulmonary artery associated with hypoplastic left heart syndrome died of congestive heart failure on hospital day 3 in spite of prostaglandin administration. Lloyd et al.^[32] reported total anomalous origin of coronary artery from the pulmonary artery was found during the operation for ventricular septal defect and aorticopulmonary septal defect in a 7-week old baby. Finally the baby was failed to be resuscitated from the operation and died. Davis and Lie^[33] reported a case of the origin of a single coronary artery arising from the innominate artery (brachiocephalic trunk). Associated cardiovascular malformations were truncus arteriosus and a single ventricle and died 12 hours after birth. Heart failure

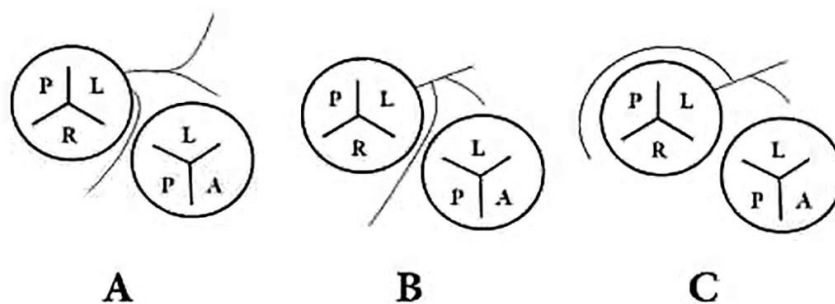


Fig. 1 - Right coronary artery arising from the left coronary sinus^[10]: (A) from a separate ostia with the left coronary artery; (B) from the left main stem coursing between the aorta and pulmonary artery; and (C) from the left main stem with a retroaortic course.

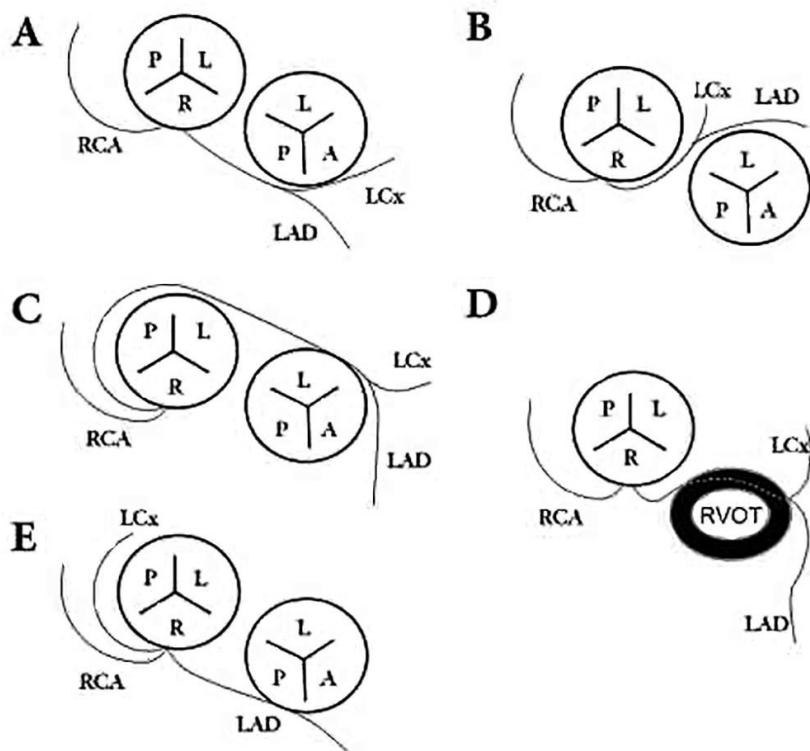


Fig. 2 - Left coronary artery arising from the right coronary sinus^[12,13]: (A) from a separate ostia with the right coronary artery; (B) sharing a same ostia with the right coronary artery coursing between the aorta and pulmonary artery; (C) sharing a same ostia with the right coronary artery with a retroaortic course; (D) coursing via the right ventricular outflow tract; and (E) with an anterior course of the left anterior descending coronary artery and a retroaortic course of the left circumflex artery.

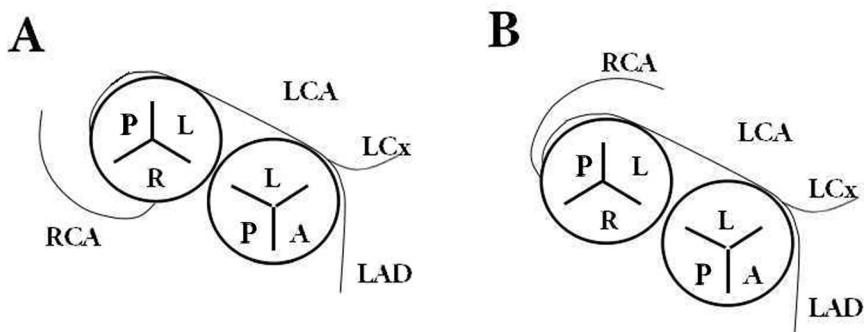


Fig. 3 - Coronary artery arising from the noncoronary sinus: (A) left coronary artery arising from the noncoronary sinus; and (B) both left and right coronary arteries arising from the noncoronary sinus.

evidenced by severe pulmonary and hepatic congestion was the probable cause of death. However, when associated with a lesion that may enhance the oxygen content or right heart pressure, a longer survival can be expected.

Anomalous origin of coronary artery can sometimes be associated with acquired heart disease including coronary artery disease or heart valve disorders. Acute myocardial infarction has been reported in a patient with anomalous origin of coronary artery with diffuse coronary stenotic lesions^[18]. Kalyani et al.^[34] discovered well-formed atherosclerotic plaques in both the aorta and coronary artery by autopsy in a young male with anomalous origin of RCA as a branch of the LCx. Anomalous origin of RCA as a branch of LAD was reported in a 54-year-old male patient presenting with acute myocardial infarction in the LAD and RCA territories^[35]. Concurrent severe stenosis, occlusion and ectasia of coronary artery may present^[36]. A 48-year-old man presented with acute myocardial infarction. On aortography, the LAD, LCx and RCA were seen to arise separately from the right coronary sinus and there was a diffuse stenotic lesion in the distal LCx. He was successfully treated with coronary stenting^[18]. Coronary artery disease of the RCA in the normal location with two consecutive 95% stenosis in the proximal section was once reported in a patient with anomalous origin of LM from the innominate artery^[37]. Modi et al.^[38] reported a 62-year-old male patient with RCA originating from the LAD and LCx and severe mitral regurgitation. The patient underwent surgery for reimplantation of the anomalous RCA to an anterior aortic sinus and mitral valve repair by ring anuloplasty with no complications.

PREDISPOSING RISK FACTORS

Approximately 5% of the patients with acute myocardial infarction do not have atherosclerotic coronary artery disease but have other causes for their luminal narrowing. The nonatherosclerotic narrowing coronary arteries focus on congenital coronary artery anomalies, coronary fistula and high take-off position of coronary ostia^[39]. The risk of ischemia is probably exacerbated by the associated anatomical factors, A) flap closure of the slit-like deformation of the coronary ostium; B) acute (non-orthogonal) angle of take-off and kinking of the coronary artery as it exits from the aorta; and C) hypoplasia and/or stenosis of the intramural segment, particularly at the level of the valvar commissure. In addition, cumulative episodes of myocardial ischemia may lead to patchy myocardial necrosis and fibrosis responsible for ventricular arrhythmias^[40].

The blood supply to the first portion of the ventricular septum is provided by 1 or 2 descending septal branches from the anomalous LM when it courses between the aorta and pulmonary trunk. When the anomalous LM courses posteriorly to the aorta, it does not provide any septal branches.

In an anomaly as such, the blood supply to the first portion of the septum is usually provided by the descending septal branches originating from the right sinus of Valsalva or from the proximal RCA^[41].

Anomalous origin of LCx from the aorta is generally viewed as a benign coronary arterial anomaly^[42]. However, two patients had myocardial infarction in the distribution of the aberrant vessel^[42]. The atherosclerotic predilection is evident only in anomalous coronary artery arising from the right side and pursuing a retroaortic course, and the anomalous artery is likely to be responsible for myocardial infarction in patients 60 years or older^[43].

Sudden death (28/49, 57%) and exercise-related death (18/28, 64%) are most common with anomalous origin of LM from the right coronary sinus. Anomalous origin of RCA from the left coronary sinus is also frequently associated with exercise-related sudden death (6/13, 46%). The high risk anatomies responsible for the sudden death are coronary artery segment coursing between the pulmonary artery and aorta^[44], acute angle take-off of the left coronary artery^[45] and ostial abnormalities including ostial valve-like ridge^[46], slit-like orifice^[47] and fluted beak-shaped ostium^[48]. The anomalous origin of coronary artery may have various degree of left-to-right shunting, which may lead to steal phenomenon worsening myocardial hypoxia and predispose cardiac sudden death^[17]. Other predisposing risk factors leading to sudden death are intramural course, interarterial course, vessel spasm and intussusception of the anomalous artery^[3]. A 3-6 folds higher sudden cardiac death rate was noted in military and athletes with increased physical activities with anomalous origin of coronary artery than in general population with the lesion^[49].

DIAGNOSIS

The diagnosis of anomalous origin of coronary artery from other arteries can be challenging. Most of the coronary anomalies are asymptomatic and benign but may cause myocardial ischemia and sudden death^[50]. Anomalous origin of coronary artery is often associated with a pathophysiologic state of inadequate tissue perfusion and subsequent hypoxia^[51].

Transthoracic echocardiography may offer indirect diagnostic signs like abnormal biphasic flows in the left ventricular outflow tract (LVOT), i.e., systolic flow from the LVOT and diastolic flow toward the LVOT. The origin of the RCA in the LVOT may be visualized by computed tomographic angiography and by transthoracic echocardiography^[52]. Combined coronary angiography and computed tomographic angiography are reliable for the diagnosis of origin of RCA from the left ventricle^[53]. Anomalous origin of left coronary artery from the pulmonary artery is a rare congenital anomaly and one of the causes of myocardial ischemia. Due to atypical signs and symptoms in childhood, it can be misdiagnosed

as dilated cardiomyopathy^[54]. The definitive diagnosis can be reached by multislice computed tomography and coronary angiography^[55]. Conventional angiography and magnetic resonance imaging depict the origin and proximal courses of these arteries^[56].

Kim et al.^[57] reported during the coronary angiography the LCA could not be catheterized and was thus unable to be demonstrated on right coronary angiography or root aortography in a patient who was eventually diagnosed with anomalous origin of LCA from the innominate artery.

Management Policies

The management of anomalous origin of coronary artery remains debating. Surgical treatment is a definitive therapy that is recommended even for asymptomatic patients. Only a few patients were treated medically with no follow-up available. Simple ligation of the coronary system is less traumatic and is the simplest alternative, but the risk of a single ostium coronary system still persists. Some authors suggested a simple coronary artery bypass grafting. However, others objected due to the potential hazards of coronary steal phenomenon and poor patency of internal mammary arterial bypasses, and modified maneuvers such as coronary ostial reimplantation, impinged coronary segment unroofing and coronary stent deployment were advocated^[58].

It was therefore concluded that internal mammary arterial bypass is not an appropriate approach for this lesion^[59]. In some cases, reimplantation was tried initially but could not be performed due to the fragility of the anomalous coronary artery. As a result, the patients required ligation of the anomalous coronary artery. Heart valve repair or replacement is recommended at the time of coronary surgery for those who are associated with an acquired heart valve disorder. Although successful reimplantation of the anomalous coronary artery to the aorta, persistent symptoms and myocardial ischemia may still be present in some patients. Due to the debates of outcomes and limited information of long-term follow-up, large series of patients for the evaluations of their ventricular function and the patency of the reimplanted vessel are necessary.

CONCLUSION

Sudden cardiac death in anomalous origin of coronary artery is associated with the anatomical features including abnormal coursing, acute angle take-off and ostial abnormalities. Atherosclerosis is prone to be in the right-sided ectopic and retroaortic coursing coronary artery. Surgical treatment is a definitive therapy. Simple coronary artery bypass grafting is not recommended due to the potential hazards of coronary steal phenomenon and poor patency of the internal mammary arterial grafts, and modified maneuvers such as coronary ostial reimplanta-

tion, impinged coronary segment unroofing and coronary stent deployment are advocated instead.

Authors' roles & responsibilities	
SMY	Main Author

REFERENCES

1. Yamanaka O, Hobbs RE. Coronary artery anomalies in 126,595 patients undergoing coronary angiography. *Cathet Cardiovasc Diagn.* 1990;21(1):28-40.
2. Radswiki. Congenital coronary artery anomalies [citado em 1 de dezembro de 2014]. Disponível em: <http://radiopaedia.org/articles/congenital-coronary-artery-anomalies>
3. Angelini P. Normal and anomalous coronary arteries: definitions and classification. *Am Heart J.* 1989;117(2):418-34.
4. Aydin M, Ozeren A, Peksoy I, Cabuk M, Bilge M, Dursun A, et al. Myocardial ischemia caused by a coronary anomaly: left circumflex coronary artery arising from right sinus of valsalva. *Tex Heart Inst J.* 2004;31(3):273-5.
5. Dogan SM, Gursurer M, Aydin M, Gocer H, Cabuk M, Dursun A. Myocardial ischemia caused by a coronary anomaly left anterior descending coronary artery arising from right sinus of Valsalva. *Int J Cardiol.* 2006;112(3):e57-9.
6. Cheitlin MD, De Castro CM, McAllister HA. Sudden death as a complication of anomalous left coronary origin from the anterior sinus of Valsalva: a not-so-minor congenital anomaly. *Circulation.* 1974;50(4):780-7.
7. Greet B, Quinones A, Srichai M, Bangalore S, Roswell RO. Anomalous right coronary artery and sudden cardiac death. *Circ Arrhythm Electrophysiol.* 2012;5(6):e111-2.
8. Kimbiris D, Iskandrian AS, Segal BL, Bemis CE. Anomalous aortic origin of coronary arteries. *Circulation.* 1978;58(4):606-15.
9. Golubickas D, Motiejūnaitė J, Jankauskas A, Slapikas R, Basevičius A. Incidentally diagnosed malignant coronary artery anomaly: a clinical case. *Medicina (Kaunas).* 2013;49(10):462-5.
10. Ortale JR, Meciano Filho J, Paccola AM, Leal JG, Scaranari CA. Anatomia dos ramos lateral, diagonal e ântero-superior no ventrículo esquerdo do coração humano. *Rev Bras Cir Cardiovasc.* 2005;20(2):149-58.

11. Pursnani A, Jacobs JE, Saremi F, Levisman J, Makaryus AN, Capuñay C, et al. Coronary CTA assessment of coronary anomalies. *J Cardiovasc Comput Tomogr*. 2012;6(1):48-59.
12. Palomo AR, Schrage BR, Chahine RA. Anomalous separate origin of the septal perforator coronary artery from the left sinus of Valsalva. *Cathet Cardiovasc Diagn*. 1984;10(4):385-8.
13. Li JM, Zhu L. Advances of research of anomalous origin of coronary artery. *Chin J Clin*. 2013;7(3):1205-8.
14. Yüksel S, Meriç M, Soyulu K, Gülel O, Zengin H, Demircan S, et al. The coronary angiographic analysis of 16573 patients for coronary artery origination and course anomalies [Cited 2014 Dec 1]. Available at: <http://spo.escardio.org/eslides/view.aspx?eevtid=48&fp=P4221>
15. Barriales-Villa R, Moris C, Sanmartín JC, Fernández E, Pajín F, Ruiz Nodar JM. Anomalous coronary arteries originating in the contralateral sinus of Valsalva: registry of thirteen Spanish hospitals (RACES). *Rev Esp Cardiol*. 2006;59(6):620-3.
16. Click RL, Holmes DR Jr, Vlietstra RE, Kosinski AS, Kronmal RA. Anomalous coronary arteries: location, degree of atherosclerosis and effect on survival: a report from the Coronary Artery Surgery Study. *J Am Coll Cardiol*. 1989;13(3):531-7.
17. Byard RW. Vascular condition. In: Byard RW, ed. *Sudden death in the young*. 3rd ed. Cambridge: University Press; 2010. p.273-343.
18. Cho HO, Cho KH, Jeong YS, Ahn SG, Choi SJ, Yoo JY, et al. Anomalous origin of the left coronary artery from the right sinus of Valsalva, which presented as acute myocardial infarction. *Korean Circ J*. 2006;36(12):817-9.
19. Chaitman BR, Bourassa MG, Lespérance J, Dominguez JL, Saltiel J. Aberrant course of the left anterior descending coronary artery associated with anomalous left circumflex origin from the pulmonary artery. *Circulation*. 1975;52(5):955-8.
20. Liberthson RR, Zaman L, Weyman A, Kiger R, Dinsmore RE, Leinbach RC, et al. Aberrant origin of the left coronary artery from the proximal right coronary artery: diagnostic features and pre- and postoperative course. *Clin Cardiol*. 1982;5(6):377-81.
21. Santucci PA, Bredikis AJ, Kavinsky CJ, Klein LW. Congenital origin of the left main coronary artery from the innominate artery in a 37-year-old man with syncope and right ventricular dysplasia. *Catheter Cardiovasc Interv*. 2001;52(3):378-81.
22. Duran NE, Duran I, Aykan AC. Congenital anomalous origin of the left main coronary artery from the innominate artery in a 73-year-old woman. *Can J Cardiol*. 2008;24(12):e108.
23. Kim YM, Choi RK, Lee CK. Anomalous origin of left coronary artery from innominate artery. *J Am Coll Cardiol*. 2009;54(2):176.
24. Cheatham JP, Ruyle NA, McManus BM, Gammel GE. Origin of the right coronary artery from the descending thoracic aorta: angiographic diagnosis and unique coronary artery anatomy at autopsy. *Cathet Cardiovasc Diagn*. 1987;13(5):321-4.
25. Mahajan D, Agnihotri G, Brar R. Anomalous origin of right coronary artery: an anatomico-clinical perspective of 2 cases. *Acta Inform Med*. 2012;20(1):56-7.
26. McMahon CJ, DiBardino DJ, Undar A, Fraser CD Jr. Anomalous origin of left coronary artery from the right pulmonary artery in association with type III aortopulmonary window and interrupted aortic arch. *Ann Thorac Surg*. 2002;74(3):919-21.
27. Charrot F, Tarniz A, Glock Y, Léobon B. Diagnosis and surgical treatment of an aneurysm on a cervical aortic arch associated with an anomalous origin of the left main coronary artery. *Interact Cardiovasc Thorac Surg*. 2010;10(2):346-7.
28. Robicsek F. Origin of the left anterior descending coronary artery from the left mammary artery. *Am Heart J*. 1984;108(5):1377-8.
29. Liu F, Huang G, Zhang J. Anomalous origin of a coronary artery from the right branchiocephalic trunk associated with complex congenital heart disease. *Pediatr Cardiol*. 2010;31(1):163-5.
30. Hoganson G, McPherson E, Piper P, Gilbert EF. Single coronary artery arising anomalously from the pulmonary trunk. *Arch Pathol Lab Med*. 1983;107(4):199-201.
31. Bharati S, Szarnicki RJ, Popper R, Fryer A, Lev M. Origin of both coronary arteries from the pulmonary trunk associated with hypoplasia of the aortic tract complex: a new entity. *J Am Coll Cardiol*. 1984;3(2 Pt 1):437-41.
32. Lloyd TR, Marvin WJ Jr, Lee J. Total anomalous origin of the coronary arteries from the pulmonary artery in an infant with aorticopulmonary septal defect. *Pediatr Cardiol*. 1987;8(2):153-4.
33. Davis JS, Lie JT. Anomalous origin of a single coronary artery from the innominate artery. *Angiology*. 1977;28(11):775-8.
34. Kalyani R, Thej MJ, Prabhakar K, Kiran J. Right coronary artery originating from left circumflex artery: an unusual coronary anomaly at autopsy. *J Clin Biomed Sci*. 2011;1(2):77-80.
35. Sreenivas Kumar ML, Rajasekhar D, Vanajakshamma V, Shashanka C. Anomalous right coronary artery arising from left anterior descending artery. *J Clin Sci Res*. 2012;3:144-7.
36. Li CB, Bi YW, Sun WY, Li RJ, Li GS, You BA, et al. Images in cardiology. Aberrant origin of circumflex coronary artery from left subclavian artery. *J Am Coll Cardiol*. 2011;57(1):e1.
37. Santucci PA, Bredikis AJ, Kavinsky CJ, Klein LW. Congenital origin of the left main coronary artery from the innominate artery in a 37-year-old man with syncope and right ventricular dysplasia. *Catheter Cardiovasc Interv*. 2001;52(3):378-81.

38. Modi H, Ariyachaipanich A, Dia M. Anomalous origin of right coronary artery from pulmonary artery and severe mitral regurgitation due to myxomatous mitral valve disease: a case report and literature review. *J Invasive Cardiol.* 2010;22(4):E49-55.
39. Waller BF, Fry ET, Hermiller JB, Peters T, Slack JD. Nonatherosclerotic causes of coronary artery narrowing: Part I. *Clin Cardiol.* 1996;19(6):509-12.
40. Gaudin R, Raisky O, Vouhé PR. Anomalous aortic origin of coronary arteries: 'anatomical' surgical repair. *Multimed Man Cardiothorac Surg.* 2014;2014:mmt022.
41. Kimbiris D. Anomalous origin of the left main coronary artery from the right sinus of Valsalva. *Am J Cardiol.* 1985;55(6):765-9.
42. Silverman KJ, Bulkley BH, Hutchins GM. Anomalous left circumflex coronary artery: "normal" variant of uncertain clinical and pathologic significance. *Am J Cardiol.* 1978;41(7):1311-4.
43. Samarendra P, Kumari S, Hafeez M, Vasavada BC, Sacchi TJ. Anomalous circumflex coronary artery: benign or predisposed to selective atherosclerosis. *Angiology.* 2001;52(8):521-6.
44. Taylor AJ, Rogan KM, Virmani R. Sudden cardiac death associated with isolated congenital coronary artery anomalies. *J Am Coll Cardiol.* 1992;20(3):640-7.
45. Catanzaro JN, Makaryus AN, Catanese C. Sudden cardiac death associated with an extremely rare coronary anomaly of the left and right coronary arteries arising exclusively from the posterior (noncoronary) sinus of Valsalva. *Clin Cardiol.* 2005;28(11):542-4.
46. Virmani R, Chun PK, Goldstein RE, Robinowitz M, McAllister HA. Acute takeoffs of the coronary arteries along the aortic wall and congenital coronary ostial valve-like ridges: association with sudden death. *J Am Coll Cardiol.* 1984;3(3):766-71.
47. Kron IL. The best approach to repair anomalous origin of the right coronary artery. *Eur J Cardiothorac Surg.* 2012;41(2):290.
48. Maresi EA, Argo AM, Spanò GP, Novo GM, Cabibi DR, Procaccianti PG. Images in cardiovascular medicine. Anomalous origin and course of the right coronary artery. *Circulation.* 2006;114(22):e609-11.
49. Corrado D, Basso C, Pavei A, Michieli P, Schiavon M, Thiene G. Trends in sudden cardiovascular death in young competitive athletes after implementation of a preparticipation screening program. *JAMA.* 2006;296(13):1593-601.
50. Bayat P, Masoud F, Ghanbari A, Gannnnji-Harsini S. Anomalous origin of the circumflex branch from the right coronary artery. *Int J Morphol.* 2013;31(1):169-71.
51. Lin Y, Cornish S, Lim R. A case of an anomalous origin of left main coronary artery from right sinus of Valsalva leading to sudden death. *UWOMJ.* 2012;81(1):41-2.
52. Ciarka A, Lens V, Beissel J, Wagner DR. Right coronary artery originating in the left ventricle. *J Am Coll Cardiol.* 2010;56(16):1351.
53. Kang N, Tan SY, Ding ZP, Chua YL. Abnormal origin of right coronary artery from left ventricle with bicuspid aortic stenosis. *Ann Thorac Surg.* 2013;96(2):e43-5.
54. Bakiler AR, Eliaçık K, Köse S, Atay Y. Anomalous origin of the left coronary artery from the pulmonary artery presenting as dilated cardiomyopathy. *Turk Kardiyol Dern Ars.* 2013;41(5):448-50.
55. Gribaa R, Slim M, Ben Salem H, Neffati E, Boughzela E. Anomalous origin of the left coronary artery from the pulmonary artery presenting as dilated cardiomyopathy: a case report. *J Med Case Rep.* 2014;8:170.
56. Patel KB, Gupta H, Nath H, Aqel RA, Zoghbi GJ, Soto B, et al. Origin of all three major coronary arteries from the right sinus of Valsalva: clinical, angiographic, and magnetic resonance imaging findings and incidence in a select referral population. *Catheter Cardiovasc Interv.* 2007;69(5):711-8.
57. Kim YM, Choi RK, Lee CK. Anomalous origin of left coronary artery from innominate artery. *J Am Coll Cardiol.* 2009;54(2):176.
58. Elhmidi Y, Nöbauer C, Hörer J, Schreiber C, Lange R. Surgical unroofing of an anomalous right coronary artery arising from the posterior left sinus of Valsalva. *World J Pediatr Congenit Heart Surg.* 2013;4(4):433-5.
59. Kron IL. The best approach to repair anomalous origin of the right coronary artery. *Eur J Cardiothorac Surg.* 2012;41(2):290.