



Revista Brasileira de Cirurgia
Cardiovascular/Brazilian Journal of
Cardiovascular Surgery

ISSN: 0102-7638

revista@sbccv.org.br

Sociedade Brasileira de Cirurgia
Cardiovascular

Barboza de Oliveira, Marcos Aurélio; Tieco da Rocha Sabbag, Amália; Brandi, Antônio
Carlos; dos Santos, Carlos Alberto; Husseni Botelho, Paulo Henrique; Patriarcha, Franz
Andrei; Braile, Domingo M.

Surgical Treatment for Thrombus Straddling a Patent Foramen Ovale
Revista Brasileira de Cirurgia Cardiovascular/Brazilian Journal of Cardiovascular Surgery,
vol. 31, núm. 5, 2016, pp. 406-408
Sociedade Brasileira de Cirurgia Cardiovascular
São José do Rio Preto, Brasil

Available in: <http://www.redalyc.org/articulo.oa?id=398948359013>

- How to cite
- Complete issue
- More information about this article
- Journal's homepage in redalyc.org

redalyc.org

Scientific Information System

Network of Scientific Journals from Latin America, the Caribbean, Spain and Portugal

Non-profit academic project, developed under the open access initiative

Surgical Treatment for Thrombus Straddling a Patent Foramen Ovale

Marcos Aurélio Barboza de Oliveira¹, MD, PhD; Amália Tieco da Rocha Sabbag², MD; Antônio Carlos Brandi³, MD, PhD; Carlos Alberto dos Santos³, MD, PhD; Paulo Henrique Husseni Botelho³, MD; Franz Andrei Patriarcha², MD; Domingo M. Braile⁴, MD, MSc, PhD



DOI: 10.5935/1678-9741.20160082

Abstract

We present a case of a 41-year-old female with deep vein thrombosis after abdominal surgery. The patient quickly developed severe pulmonary embolism and stroke representative of paradoxical embolism. Echocardiography showed a thrombus straddling a patent foramen ovale, which was confirmed

intraoperatively. An accurate diagnosis and rapid treatment decisions are crucial for preventing patient deterioration in the form of new pulmonary embolisms or stroke.

Keywords: Embolism, Paradoxical. Venous Thrombosis. Stroke. Pulmonary Embolism.

Abbreviations, acronyms & symbols

AP	=Arterial pressure
CT	=Computed tomography
CVP	=Central venous pressure
DVT	=Deep vein thrombosis
ETCO ₂	=End-tidal CO ₂
ICU	=Intensive care unit
FiO ₂	=Fraction of inspired oxygen
PE	=Pulmonary embolism
PFO	=Patent foramen ovale

INTRODUCTION

The identification of a thrombus in a patent foramen ovale (PFO) is a relatively rare event^[1-4], despite the relative frequency of this anatomical anomaly of the atrial septum, which can be found in almost 20% of the normal population^[1]. Generally, thrombus straddling a PFO is a complication of severe thromboembolic disease and is a consequence of thrombus migration into the left heart chambers, which itself is due to pulmonary hypertension.

Its association with massive pulmonary embolism (PE) leads to worse prognosis^[1].

Treatment options for thrombus in PFO include thrombolysis, heparin therapy, or surgery. Fauveau et al.^[2] reported a list of 88 cases in the literature; they found a mortality rate of 36% when thrombolysis was used, 14% when heparin was administered, and 13% when surgical treatment was employed. We report a case of a straddling thrombus in a patient with a PFO that was associated with massive PE and treated surgically.

CASE REPORT

A 41-year-old female patient who was previously healthy had undergone a laparoscopic cholecystectomy ten days prior. Nine days after the procedure, the patient developed dysarthria and acute respiratory distress, requiring supplementary oxygen therapy via oxygen mask. Clinically, the patient presented left calf tenderness. Doppler ultrasound revealed lower limb venous thrombosis. Brain computed tomography (CT) showed no significant change; a chest CT confirmed the existence of an atrial thrombus straddling a PFO.

Transthoracic echocardiogram revealed systolic pressure of the right ventricle to be 56 mmHg, as well as moderate tricuspid

¹Faculdade de Medicina de São José do Rio Preto (FAMERP), São José do Rio Preto, SP, Brazil; Centro Universitário de Votuporanga (UNIFEV), Votuporanga, SP, Brazil.

²Hospital de Base (HB), São José do Rio Preto, SP, Brazil.

³Faculdade de Medicina de São José do Rio Preto (FAMERP), São José do Rio Preto, SP, Brazil.

⁴Faculdade de Medicina de São José do Rio Preto (FAMERP), São José do Rio Preto, SP, Brazil and Universidade de Campinas (UNICAMP), Campinas, SP, Brazil.

No financial support.
No conflict of interest.

Correspondence Address:
Marcos Aurélio Barboza de Oliveira
Faculdade de Medicina de São José do Rio Preto (FAMERP)
Av. Brigadeiro Faria Lima, 5416 – Vila São Pedro – São José do Rio Preto, SP, Brazil
– Zip code: 15090-000
E-mail: maboliveira@gmail.com

This study was carried out at Faculdade de Medicina de São José do Rio Preto (FAMERP), São José do Rio Preto, SP, Brazil and Hospital de Base (HB), São José do Rio Preto, SP, Brazil.

Article received on April 26th, 2015
Article accepted on August 9th, 2016

regurgitation secondary to pulmonary hypertension and a thrombus straddling a PFO (Figure 1A). Surgical treatment was indicated to remove the thrombus from the heart and for PFO closure. Figure 1B shows the thrombus removed from the atrium during the surgical intervention.

During the surgery, the manipulation of the heart was avoided in order to minimize the risk of another PE. The thrombus was found in the right atrium and it went through the PFO into the left atrium (Figures 2A and 2B). The thrombus was resected and PFO was closed using a 4-0 Prolene running suture.

Cardiopulmonary bypass weaning failed twice. Left atrial pressure was 30 mmHg, end-tidal CO₂ (ETCO₂) was 10-12 mmHg, and oxygen saturation was 89% (a value likely due to the PE). Norepinephrine (0.2 mcg/kg/min) and milrinone (0.75 mcg/kg/min) were useful for successfully weaning the patient off ventricular assistance.

The patient was admitted to the intensive care unit (ICU) under mechanical ventilation with a fraction of inspired oxygen (FiO₂) of 60%, saturation at 89%, central venous pressure (CVP) of 24 mmHg, arterial pressure (AP) of 80x40, norepinephrine at 0.7 mcg/kg/min, and milrinone 0.75 mcg/kg/min. She remained unstable overnight but gradually exhibited improvements in hemodynamic stability, CVP reduction, and improved oxygen saturation in the days following. She was extubated on the sixth postoperative day and discharged from the ICU on the eighth postoperative day.

The present study was approved by Ethics Committee under number 1.401.186.

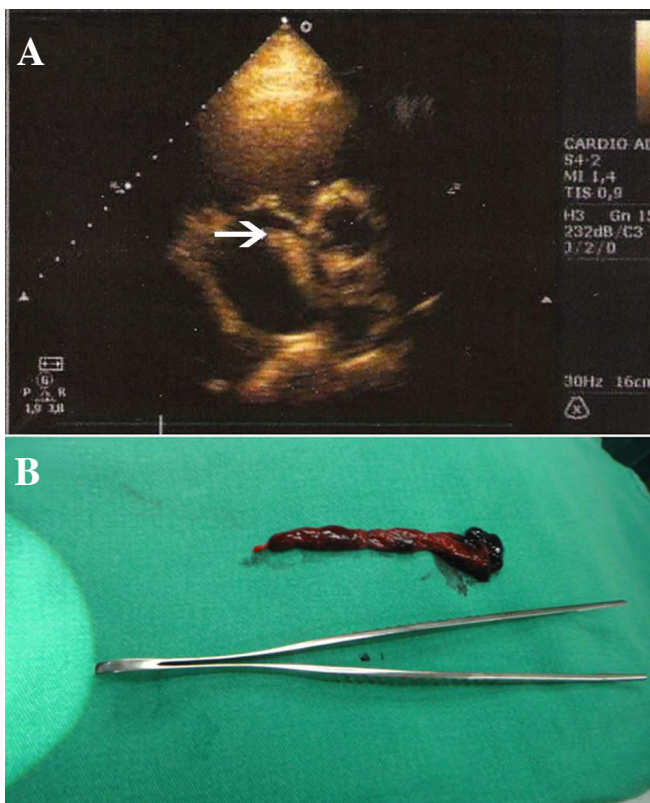


Fig. 1 - (A) Transthoracic echocardiogram showing thrombus straddling the patent foramen ovale (white arrow). (B) Thrombus approximately 5 cm in size removed from the foramen ovale.

DISCUSSION

Deep vein thrombosis (DVT) is the third largest cardiovascular disease in developed countries, followed by myocardial infarction and stroke. The risk factors for developing DVT include recent surgery and hormonal contraceptive therapy; DVT is also more common in women. These risk factors increase the likelihood of clot formation in the pelvis and lower limbs, which can eventually cause PE¹⁵.

The foramen ovale is closed by a flap-like valve on the left side of the left atrium. In patients with acute cor pulmonale, higher right-sided pressure may induce a reopening of the foramen ovale and a right-to-left atrial shunt or an increase in the shunt in patients with a

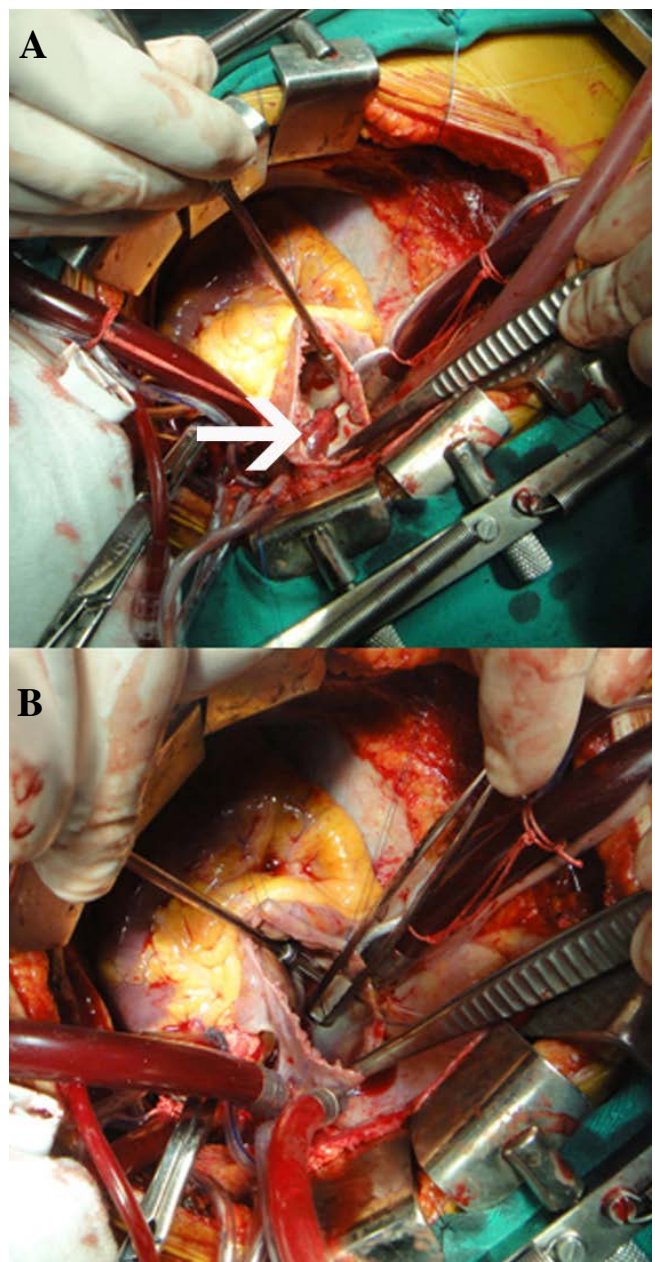


Fig. 2 - (A) Surgical picture showing open right atrium and thrombus in the patent foramen ovale (white arrow). (B) Tissue forceps through the patent foramen ovale, now without thrombus.

PFO^[1]. Most venous thrombi pass through the inferior vena cava and flow directly through the PFO, subsequently reaching the left atrium.

Reports of thrombus straddling the PFO are rare^[1-4]. Guffi^[6] demonstrated the efficacy of the surgical closure of PFO as prophylaxis to prevent cryptogenic strokes. However, in Guffi's study, no patients were found to have thrombosis on the edges of the PFO, as was the case in our patient.

Generally, the diagnosis of paradoxical embolism is presumed^[6]. Tests such as D-dimer, venous Doppler of lower limbs, and chest CTs are useful for the study of DVT and PE^[5], but when stroke is concurrent, brain CT and echocardiogram are mandatory^[2]. In our patient, D-dimer was not performed because the initial symptoms were dyspnea and dysarthria. Therefore, chest and brain CTs were selected.

Although heparin therapy has been associated with the same mortality rate as surgical treatment^[2], and though PFO closure has not been associated with a reduction in cases of late recurrent stroke^[7], the presence of an intracardiac thrombus increases the

risk of another acute PE and stroke, risks which justify emergency surgery for the intracardiac thrombus^[1,8].

Aggressive treatment should not be delayed. Surgical outcomes are more promising in stable patients without cardiogenic shock or massive systemic embolism. It should also be pointed out that most paradoxical embolisms occur early; they typically occur at the time of PE, as in our patient, and are likely caused by the increase in right atrial pressure^[1].

We have presented the case of a patient with PE and stroke in the early postoperative period following abdominal surgery. It is important to emphasize the need for full diagnostic investigations and swift decisions regarding treatment in order to avoid the worsening of symptoms in the form of new pulmonary embolisms or stroke.

Authors' roles & responsibilities

MABO	Analysis and/or data interpretation; conception and design study; manuscript redaction or critical review of its content; realization of operations and/or trials; final manuscript approval
ATRS	Manuscript redaction or critical review of its content; final manuscript approval
ACB	Conception and design study; realization of operations and/or trials; final manuscript approval
CAS	Manuscript redaction or critical review of its content; final manuscript approval
PHHB	Conception and design study; final manuscript approval
FAP	Manuscript redaction or critical review of its content; final manuscript approval
DMB	Analysis and/or data interpretation; final manuscript approval

REFERENCES

1. Cabanes L. The straddling atrial thrombus: from image to treatment. *Arch Cardiovasc Dis.* 2008;101(10):601-3.
2. Fauveau E, Cohen A, Bonnet N, Gacem K, Lardoux H. Surgical or medical treatment for thrombus straddling the patent foramen ovale: impending paradoxical embolism? Report of four clinical cases and literature review. *Arch Cardiovasc Dis.* 2008;101(10):637-44.
3. Nam SB, Kim CM, Cho SA, Chung S, Shim YH. Thrombus entrapped by patent foramen ovale in a patient with pulmonary embolism: a case report. *Korean J Anesthesiol.* 2015;68(1):70-3.
4. Ruiz NL. Impending paradoxical embolism across the interatrial septum. *J Bras Pneumol.* 2013;39(2):245-7.
5. Labropoulos N, Spentzouris G, Gasparis AP, Meissner M. Impact and clinical significance of recurrent venous thromboembolism. *Br J Surg.* 2010;97(7):989-99.
6. Guffi MEA. Surgical prophylaxis secondary to cryptogenic stroke or transient ischemic attack in patients with patent foramen ovale. *Rev Bras Cir Cardiovasc.* 2003;18(3):242-52.
7. Kent DM, Thaler DE. Is patent foramen ovale a modifiable risk factor for stroke recurrence? *Stroke.* 2010;41(10 Suppl):S26-30.
8. Shah DK, Ritter MJ, Sinak LJ, Miller JA, Sundt TM 3rd. Paradoxical embolus caught in transit through a patent foramen ovale. *J Card Surg.* 2011;26(2):151-3.