



Semina: Ciências Agrárias

ISSN: 1676-546X

semina.agrarias@uel.br

Universidade Estadual de Londrina  
Brasil

Cioato da Silva, Cristine; Albuquerque de Oliveira Cavalcanti, Guilherme; de Vargas Arigony Braga, Fabricio; Normanton Guim, Thomas; Salgado Gomes, Luiz Guilherme; da Silva Rappeti, Josaine Cristina

Dioctophyme renale parasitism in domestic cat in Rio Grande do Sul, Brazil – first reported case

Semina: Ciências Agrárias, vol. 38, núm. 4, julio-agosto, 2017, pp. 2215-2219

Universidade Estadual de Londrina

Londrina, Brasil

Available in: <http://www.redalyc.org/articulo.oa?id=445752269048>

- How to cite
- Complete issue
- More information about this article
- Journal's homepage in redalyc.org

redalyc.org

Scientific Information System

Network of Scientific Journals from Latin America, the Caribbean, Spain and Portugal

Non-profit academic project, developed under the open access initiative

## ***Diocotophyme renale* parasitism in domestic cat in Rio Grande do Sul, Brazil – first reported case**

### ***Diocotophyme renale* em gato doméstico: primeiro relato de caso no Rio Grande do Sul, Brasil**

Cristine Cioato da Silva<sup>1\*</sup>; Guilherme Albuquerque de Oliveira Cavalcanti<sup>2</sup>;  
Fabricio de Vargas Arigony Braga<sup>2</sup>; Thomas Normanton Guim<sup>3</sup>;  
Luiz Guilherme Salgado Gomes<sup>4</sup>; Josaine Cristina da Silva Rappeti<sup>2</sup>

#### **Abstract**

*Diocotophyme renale* is a worldwide known nematode of dogs and other domestic and wild species, being uncommon in cats. Some findings of *D. renale* parasitism in dogs and other wild species are reported in Brazil; but only two cases were recorded in domestic cats. This study aimed to report renal parasitism of *D. renale* in domestic cat assisted at the Hospital of Veterinary Clinics from the Universidade Federal de Pelotas, in Pelotas city, Rio Grande do Sul State, Brazil; which were the first successfully diagnosed and treated case in this species. The patient had signs of urethral obstruction. *D. renale* eggs were detected through urinalysis, and parasite location was categorized as being in the entire medullary area of the right kidney by ultrasound exam. Right nephrectomy was established as therapy, once this organ was destroyed. A 20-cm long female and a 12-cm long male were removed with the right kidney, besides another 16-cm long male from left perirenal region. After 10 days of surgery, the patient was completely recovered from urinary dysfunction, being ready for hospital discharge.

**Key words:** Domestic cat. Urethral obstruction. Renal parasitism. Kidney worm. Nephrectomy.

#### **Resumo**

*Diocotophyme renale* é um nematódeo conhecido mundialmente que parasita cães e outras espécies domésticas bem como espécies selvagens, sendo incomum em gatos. No Brasil, existem alguns relatos do parasitismo em cães e espécies domésticas, mas somente dois casos foram relatados em gatos domésticos. Este trabalho teve como objetivo o relato de um gato doméstico que foi acometido pelo parasitismo de *D. renale*, na cidade de Pelotas, Rio Grande do Sul, Brasil e foi o primeiro animal diagnosticado e tratado com sucesso nesta espécie. O paciente foi apresentado para atendimento após sinais clínicos de obstrução uretral. Ao exame comum de urina, foram detectados ovos de *D. renale*. Com o uso do exame de ultrassonografia, foi detectada a localização renal do parasito com destruição total do parênquima deste órgão. O tratamento efetivado foi a realização de uma nefrectomia total unilateral. Uma fêmea e um macho de 20 cm e 12 cm de comprimento, respectivamente, foram removidos do rim excisado e um macho de 16 cm removido da região perirenal esquerda. Após 10 dias do procedimento, o paciente estava completamente recuperado das alterações urinárias.

**Palavras-chave:** Gato doméstico. Obstrução uretral. Parasitismo renal. Verme do rim. Nefrectomia.

<sup>1</sup> Discente de Doutorado, Programa de Pós-Graduação em Veterinária, Universidade Federal de Pelotas, UFPel, Capão do Leão, RS, Brasil. E-mail: criscioato@hotmail.com\*

<sup>2</sup> Profs. Drs., Departamento de Clínicas Veterinária, UFPel, Capão do Leão, RS, Brasil. E-mail: guialbuquerque@yahoo.com; bragafa@hotmail.com; josainerappeti@yahoo.com.br

<sup>3</sup> Dr., Médico Veterinário do Hospital de Clínicas Veterinária, UFPel, Capão do Leão, RS, Brasil. E-mail: thomasguim@hotmail.com

<sup>4</sup> Discente de Medicina Veterinária, UFPel, Capão do Leão, RS, Brasil. E-mail: guisalgado@live.com

\* Author for correspondence

## Introduction

*Dioctophyme renale* (Goeze, 1782) is a nematode belonging to the Order Enoplida, Family Dioctophymatidae, also known as giant kidney worm, which may reach 14 to 100 cm length and 0.4 to 1.2 cm width (COTTAR et al., 2012). It is a worldwide parasite of canids and other domestic and wild animals, but atypical in cats (PEDRASSANI et al., 2014).

Definitive host infection occurs by ingestion of parasite larvae or infected intermediate host, such as aquatic worms, fish and frogs (PEDRASSANI; NASCIMENTO, 2015). After ingestion, *D. renale* migrates to the kidneys through the stomach or duodenum walls (PEDRASSANI et al., 2014). The right kidney is most attacked due to its proximity to those organs and has its parenchyma destroyed by parasite histolytic action (OSBORNE et al., 1969). Furthermore, in dogs, the parasite can also be found (besides kidneys) in peritoneum, liver, stomach, urinary bladder and uterus (MIRANDA et al., 1992).

Parasitism is asymptomatic in cases of mild infection, when just the kidney is affected (OSBORNE et al., 1969; KOMMERS et al., 1999). However, in most severe infections, it can be noted dysuria and hematuria (COTTAR et al., 2012). Moreover, ischuria and strangury may occur from a secondary urethral obstruction, originated from bladder epithelial desquamation and cell debris raise (GRAUER, 2010; STAINKI et al., 2011).

Confirmatory prognosis can be done by observing *D. renale* eggs through urinary sediment exam, and the parasite can be located via ultrasonography scans (COTTAR et al., 2012). This illness is treated by surgery, since no drug therapy is effective (OSBORNE et al., 1969).

This study aimed to report one case of *D. renale* parasitism in a domestic cat, in Pelotas city, Rio Grande do Sul State, Brazil.

## Case report

The patient was a one-year-old, uncastrated, male, mongrel cat with unrestricted access to street. The animal had been admitted to the hospital to treat a left eyeball perforation that had happened two days ago. Nevertheless, clinical examination pointed out for a bladder repletion due to compression; and the animal had not been urinating for one day, which suggested urethral obstruction. Finally, it was not observed no more clinic signs.

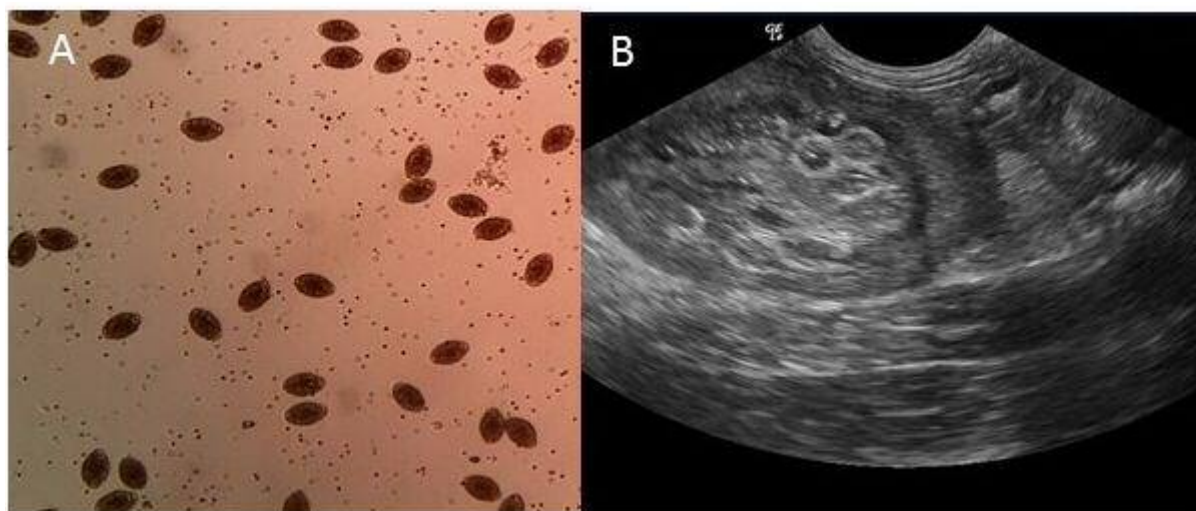
Following urethra clearance, laboratorial tests and abdominal ultrasound were performed. Full blood counting had no alterations; however, urinalysis showed proteinuria, occult blood, leukocyturia, increased bacteriuria and numerous bioperculated eggs with thick and rough shell, which are commonly found in *D. renale* (Figure 1A). Additionally, serum increase of urea (139 mg dL<sup>-1</sup>) and creatinine (3.06 mg dL<sup>-1</sup>) was observed.

Tubular structures with thin hyper-echogenic walls were found via ultrasound exam; they were on the entire spinal region and between renal capsule, right kidney cranial pole, and cortical region; this indicates *D. renale* presence (Figure 1B).

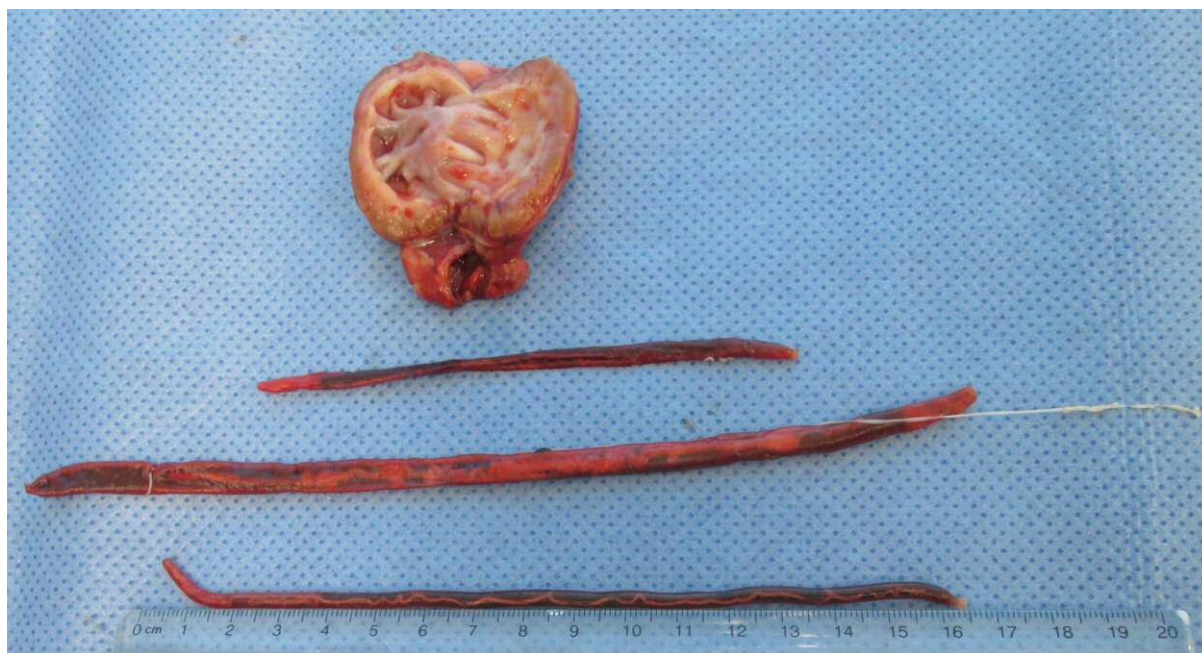After confirming diagnosis of parasitism by *D. renale*, the animal was taken to a surgical procedure of right nephrectomy, afterwards enucleation.

During the procedure, it was observed that the right kidney parenchyma was destroyed, and solely the renal capsule hosted parasites surrounded by hemorrhagic exudates, which was then removed. Furthermore, a cyst containing other parasite species surrounded the left kidney. It was removed a 20-cm long female and a 12-cm long male with the right kidney, and another 16-cm male from the perirenal region of the left kidney (Figure 2). Ten days after the procedure, the patient was already entirely recovered, and its urinary function and the serum levels of urea and creatinine were normalized.

**Figure 1.** A. Microscopic image of urine sample containing numerous eggs of *Dioctophyme renale* and, B. Ultrasound image of *D. renale* in the right kidney, of a cat from Pelotas, Rio Grande do Sul, Brazil, 2014.



**Figure 2.** Right kidney of a cat removed by nephrectomy, with total destruction of the parenchyma and their parasites. City of Pelotas, Rio Grande do Sul State, Brazil, 2014



The nematode occurrence in cats and dogs may be related to feeding habits, once both can feed on fish, mainly those with free access to the streets and/ or the homeless (VEROCAI et al., 2009; COTTAR et al., 2012). On the other side, this parasite rarely attacks domestic cats, and only two cases were reported in Brazil. Among them, one

had been diagnosed during necropsy, and the other, even though it had been checked *ante mortem* via ultrasound, the animal died during intraoperative process (VEROCAI et al., 2009; PEDRASSANI et al., 2014).

The lack of specificity in clinical signs showed in this case can be supported by several authors;



being an asymptomatic presentation, more common in unilateral parasitism of dogs (COTTAR et al., 2012).

It has been already diagnosed two cases of renal diotrophymatosis in cats, which had presented very nonspecific symptoms. One of them, in which a free parasite was found at the abdominal cavity, had complications as depletion, dehydration, jaundice and ascites. These clinical signs suggest a peritonitis case (VEROCAI et al., 2009). Yet in the other case, the cat had an abdominal size increase, persistent lateral decubitus and visible abdominal movement, giving rise to pregnancy (PEDRASSANI et al., 2014).

The patient dysuria is concerned with urethral obstruction caused by *D. renale* eggs, and cell debris buildup from renal parasitic exploitation. Likewise, azotemia evidenced by biochemical tests may be secondary to urethral obstruction and, consequently, urine inflow. This clinical scenario features a post-renal azotemia that was resolved after a urinary tract cleaning. Other authors, who reported a case of canine infected by *D. renale*, observed similar signs, starting with strangury and hematuria resulting from urethra obstruction by the front extremity of the parasite (STAINKI et al., 2011).

Because of the unspecified clinical signs, urinalysis was crucial to confirm disease diagnosis. Yet abdominal ultrasound proved to be much useful for finding the parasite, providing important information for surgical procedure, renal architecture evaluation and integrity of other organs. These additional exams had been also highlighted by other authors as essential for diagnosis of *D. renale* infection and further surgical treatment success (SILVEIRA et al., 2009; COTTAR et al., 2012).

In this case, right nephrectomy was used as treatment due to the kidney damage degree caused by the parasite. Such technique is referred by literature as an alternative for parasite removal as a therapeutic way in less severe cases, or when both kidneys are compromised (SECCHI et al.,

2010). Prognosis is favorable in these cases, since the remaining kidney is able to perform the duties normally shared by both kidneys (MESQUITA et al., 2014).

Although being an unusual in cats, renal parasitism by *D. renale* should be regarded as a differential diagnosis in cases of homeless animals from endemic regions, which presents records of urinary disorders. In this case, the complementary exams was essential to set diagnosis, enabling surgical therapy recommendation and patient life maintenance. It was the first case diagnosed and successfully treated in this animal species.

## References

- COTTAR, B. H.; DITTRICH, G.; FERREIRA, A. A.; CARVALHO, A. C. P.; ALBERNAZ, V. G. P.; LUZ, M. T.; TASQUETI, U. I. Achados ultrassonográficos de cães parasitados por *Dioctophyma renale* – estudo retrospectivo. *Veterinária e Zootecnia*, Botucatu, v. 19, n. 1, p. 8-11, 2012.
- GRAUER, F. G. Urinary tract disorders. In: NELSON, R. W.; COUTO, G. (Ed.). *Small animal internal medicine*. 3<sup>th</sup> ed. Missouri: Mosby Elsevier, 2010. p. 677-684.
- KOMMERS, G. D.; ILHA, M. R. S.; BARROS, C. S. L. Dioctofimose em cães: 16 casos. *Ciência Rural*, Santa Maria, v. 29, n. 3, p. 517-522, 1999.
- MESQUITA, L. R.; RAHAL, S. C.; FARIA, L. G.; TAKAHIRA, R. K.; ROCHA, N. S.; MAMPRIM, M. J.; OLIVEIRA, H. S. Pre- and post-operative evaluations of eight dogs following right nephrectomy due to *Dioctophyma renale*. *Veterinary Quarterly*, London, v. 34, n. 3, p. 167-71, 2014.
- MIRANDA, M. A.; BENIGNO, R. N. M.; GALVÃO, G. R.; OLIVEIRA, S. A. L. *Dioctophyma renale* (Goeze 1782): localização ectópica e alta intensidade parasitária em *Canis familiaris* do Pará – Brasil. *Arquivo Brasileiro de Medicina Veterinária e Zootecnia*, Belo Horizonte, v. 44, n. 2, p. 151-153, 1992.
- OSBORNE, C. A.; STEVENS, J. B.; HANLON, G. F.; BEMRICK, W. J. *Dioctophyma renale* in the dog. *Journal of American Veterinary Medical Association*, Schaumburg, v. 155, n. 4, p. 605-619, 1969.
- PEDRASSANI, D.; NASCIMENTO, A. A. Verme gigante renal. *Revista Portuguesa de Ciências Veterinárias*, Lisboa, v. 110, p. 30-37, 2015.

- PEDRASSANI, D.; WENDT, H.; RENNAU, E. A.; PEREIRA, S. T.; WENDT, S. B. T. *Diocotophyme renale* Goeze, 1782 in a cat with a supernumerary kidney. *Brazilian Journal of Veterinary Parasitology*, Jaboticabal, v. 23, n. 1, p. 109-117, 2014.
- SECCHI, P.; VALLE, S. F.; BRUN, M. V.; MOTTA, A. C.; RAUSCH, S. F.; MESSINA, S. A.; VIEIRA, M. I. B. Nefrectomia videolaparoscópica para tratamento da dioctofimose em um cão. *Acta Scientiae Veterinaria*, Porto Alegre, v. 38, n. 1, p. 85-89, 2010.
- SILVEIRA, L. L.; LEMOS, L. S.; FERREIRA, F. S.; FREITAS, M. V.; PEREIRA, M. A. C.; CARVALHO, C. B. Avaliação entre as técnicas de centrífugo-sedimentação e sedimentação rápida (Paratest®) na identificação de ovos de *Diocotophyme renale* em urina de cães. *Jornal Brasileiro de Ciência Animal*, Campos dos Goytacazes, v. 2, n. 3, p. 150-158, 2009.
- STAINKI, D. R.; PEDROZO, J. C. S. R.; GASPAR, L. F. J.; ZANETTE, R. A.; SILVA, A. S.; MONTEIRO, S. G. Urethral obstruction by *Diocotophyme renale* in puppy. *Comparative Clinical Pathology*, London, v. 20, n. 5, p. 535-537, 2011.
- VEROCAI, G. G.; MEASURES, L. N.; AZEVEDO, F. D.; CORREIA, T. R.; FERNANDES, J. L.; SCOTT, F. B. *Diocotophyme renale* (Goeze, 1782) in the abdominal cavity of a domestic cat from Brazil. *Veterinary Parasitology*, Amsterdam, v. 12, n. 161, p. 342-344, 2009.