



Odovtos - International Journal of Dental  
Sciences

ISSN: 1659-1046

odovtos.fo@ucr.ac.cr

Universidad de Costa Rica  
Costa Rica

Carpena Lopes, Guilherme; Ballarin, Andressa; Aguiar, José Carlos  
A New Ceramics Approach for Contact Lens  
Odovtos - International Journal of Dental Sciences, vol. 17, núm. 1, enero-abril, 2015, pp.  
14-20  
Universidad de Costa Rica  
Montes de Oca, Costa Rica

Available in: <http://www.redalyc.org/articulo.oa?id=499550301003>

- How to cite
- Complete issue
- More information about this article
- Journal's homepage in redalyc.org

redalyc.org

Scientific Information System

Network of Scientific Journals from Latin America, the Caribbean, Spain and Portugal

Non-profit academic project, developed under the open access initiative

# NEW PERSPECTIVE ARTICLE

## A New Ceramics Approach for Contact Lens Un nuevo enfoque para lente de contacto cerámico

Received: 14-IX-2015

Accepted: 05-XI-2015

Published Online First: 9-XI-2015

DOI: <http://dx.doi.org/10.15517/ijds.v0i0.22040>

### ABSTRACT

Nowadays the field of dentistry is focusing into a new aesthetic area in the light of an minimal invasive dentistry approach. Aesthetic treatments with dental porcelain veneers without any preparation (ceramic contact lenses) have gained popularity in recent years. Thus, the need for constant improvement and knowledge of innovative techniques and ceramics is fundamental. This article point out about the essential criteria to promote a clinical succeed of the technique over the years.

### KEYWORDS

Aesthetic, Contact lenses, Adhesive dentistry, Minimal invasive dentistry.

### RESUMEN

Actualmente la odontología está viviendo una nueva tendencia estética a la luz de un enfoque de odontología mínimamente invasiva . Tratamientos estéticos con carillas de porcelana dentales sin ningún tipo de preparación del sustrato dental (lentes de contacto) han ganado popularidad en los últimos años . Por lo tanto, la necesidad de constante actualización de las técnicas y materiales cerámicos es fundamental. En este artículo se enfatizan algunos criterios esenciales para promover el éxito clínico de la técnica por años.

### PALABRAS CLAVE

Estética; Lente de cerámica; Odontología adhesiva; Odontología mínimamente invasiva.

Finally, nowadays dentists are performing aesthetic treatments with dental porcelain veneers without preparation (ceramic contact lenses). Currently, we have tougher ceramics even in thin thicknesses, and more experienced dental technicians. However, it is important to point out about the essential criteria that guarantees the succeed of the technique. Ideally, contact lens have to present initial aesthetics, however the aim is to remain aesthetic and functional for decades.

Our first criteria when selecting the restorative technique have to be supported by the scientific literature. If we research in the international literature (1), we will find only four case reports of contact lenses (2-5) and only one case report was accompanied by a 3 years follow-up (2). The others case reports feature the aesthetic potential of the restorative technique after his immediate adhesive cementation (3-5). On the other hand, porcelain veneers with conservative

preparations in enamel have broad support in the international scientific literature focusing almost on clinical evaluations with a significant number of patients, highlighting a 10-year longitudinal clinical evaluation (6). Under this circumstance's, performing ceramic contact lenses is like flying a red-eye to 10.000 meters with a beautiful and brand new plane that had a sudden electrical failure on a dark night. The instruments that give information to the pilot are off. Will depend on the luck: the instruments back up, the stellar sky, Moon light, clear day. Until sunrise, is risky!.

Until solid scientific bases are not enough, contact lens still a risky procedure. In order to not rely our treatment on luck, becomes essential a clinical criteria to indicate or contraindicate this treatment, even against the patient's will.

Contact lens is a form of esthetic treatment, which is so delicate that the margin for error is minimum. Indicated criteria (Table 1) have excellent results in an increasingly expressive number of cases and brought professional satisfaction for dentists and dental technicians who have invested in this cosmetic technique.

## CRITERIA

Dental Technician (ceramist) selection – Rule #1: Do not nickel-and-dime in your ceramist (dental technician specialized in dental ceramics). Select the ceramist you know (regardless of rate) or if you are starting in this area of practice, search and listen the comment of other professionals you trust. Indeed, there's a very big chance that ceramist is not available in your city. Similarly, it is possible that the area where you work is not culturally characterized by excellence in delivery. In these cases, other criteria must be taken to consider working at long distances (7). In our opinion, the best manner to settle this aesthetic treatment is ensuring that the ceramist examines

the patient along with the dentist. While dentists often limit to the sixteen Vita color scale options, the ceramists expands to the seventy-five color options and ceramic opacities inside most systems used by them. Pay immediately, if possible in cash. In 2015, working in Brazil or in main Latin America cities, probably, he should need it.

Aesthetic proof (mock-up) – The aesthetic proof is the main step in order to place on dental position the shell we performed on the plaster model. It is recommended to transpose in image for patient assessment, this phase will become in our initial idea of the new architectural project of the patient's smile. This stage of treatment should be documented with clinical photographs, evaluated by us, by ceramicist and by the patient. The opinion of the patient is of crucial importance.

Functional Test – After the aesthetic proof, we strongly recommend the use of Protemp 4 (3M ESPE, USA) or Structur 3 (VOCO, Germany) shell for another function: check the joint movements. Evaluate if there is overload in the areas in closure with contact lenses. If necessary, this is the opportune time to make the adjustments. At the end of the set, document with new clinical photographs and mold to send to the lab.

Ceramic System - In descending order in terms of resistance, ceramic contact lenses can be made of ceramic glass reinforced with lithium dissilicate or by leucite, or even by feldspathic porcelain. All these three ceramic options can be performed by modern CAD/CAM systems or by injected systems. Due to its low resistance and large contraction during heating and cooling, the feldspathic porcelain should be avoided in thin thicknesses. CAD/CAM systems can be used, but by far are no better than injected ceramic systems. The degree of resistance and adaptation of ceramic to the tooth with injected systems is still superior to CAD/CAM systems. In addition, the suggested

minimum thickness for CAD/CAM milled ceramic is 0,5 mm. On the other hand, 0.2 mm thickness is acceptable with injectable ceramic.

Contact lenses and resin cement selection – The final result of the aesthetic treatment is the sum of the patient's tooth colour, the resin cement shade and ceramics characteristics. Remember that contact lenses especially those thin ceramics are translucent. The color of the resin cement becomes of huge importance. Select light-cured resin cements that: displays several color options, have folders trial (try-in) to select the shade, flowable (easy to compress) and with a noble polishing technique. Avoid the cements that can't be polish (see the comparison between the photomicrographs in Figure 1). At the moment of the proof of lenses, let the patient willingness to opine on this final evaluation regarding the aesthetic treatment. If the patient is not 100% satisfied, understand his criteria, transmit this information to the ceramist, and evaluate the possibility of correction. However, in most cases, the require adjustment is only possible by performing another ceramic contact lenses. Until 100% patient satisfaction, did not perform the final cementation of the contact lenses.


Polishing – Be sure to have the appropriate tools for the polishing procedure of ceramic lenses and for the marginal seal. Ideally, the ceramic lens comes perfectly finished. However in thin thickness the finishing performed by the ceramist is more challenging. In thin contact lenses, ceramics tends to cracks in the edges. Compare in Figure 2 the different ceramic samples. Thick ceramic lenses require a finishing procedure on superior

marginal seal. Even minor ceramic excesses may cause gingival inflammation (Figure 3A), thus is fundamental its removal with fine-grained diamond tips (Figure 3B). Rubber points specially design for these types of materials are indispensable to provide a polished surface to the ceramic (Figure 3D and 3E).

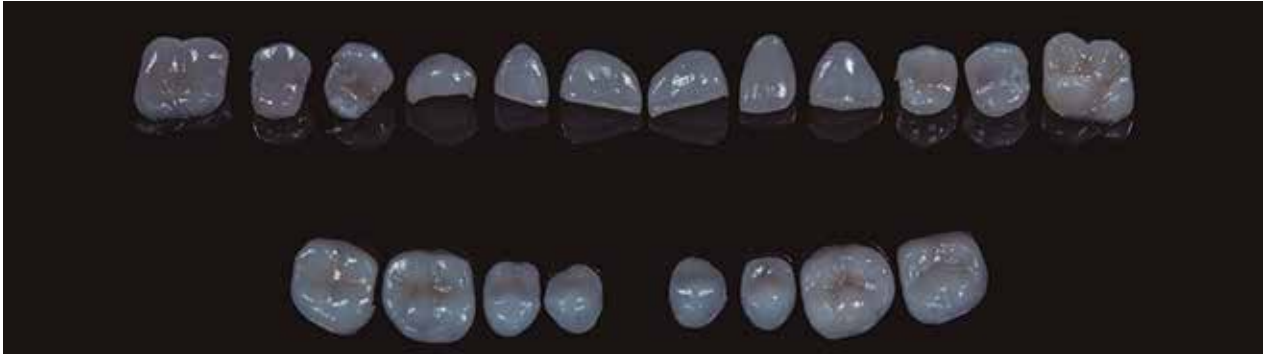Follow up- Strict periodontal examination of patients with contact lenses is fundamental in order to achieved clinical success. Remember the patient's periodontal health is your responsibility. Review twice a year, the marginal seal and integrity of the adhesive cement and ceramic interface of the contact lens (Figure 3 c). Gingival retractors are suitable instruments to examine these areas.

**Table 1.** Recommended Criterion to Indicate Contact Lenses

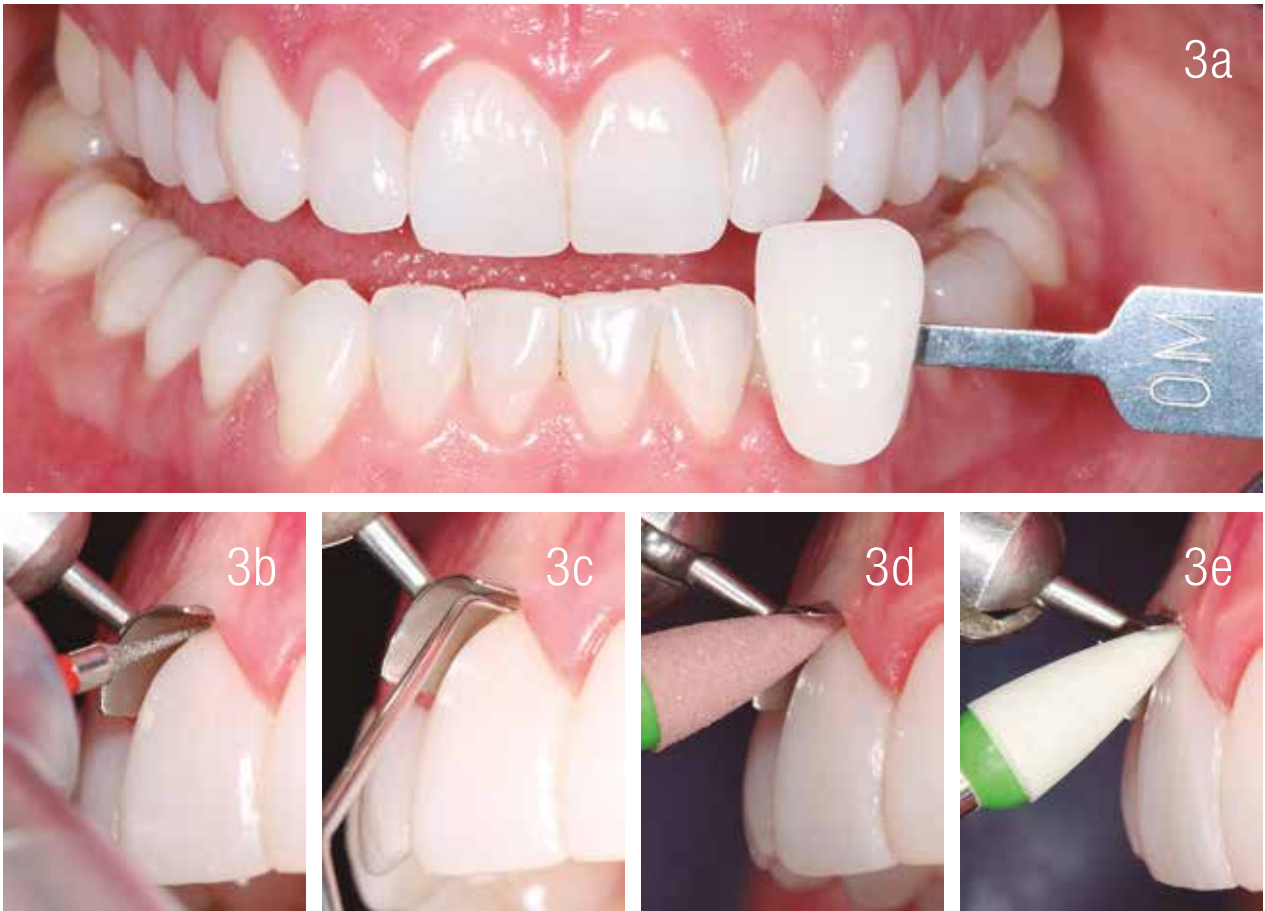- 
- A minimum amplitude of 0,2mm in the labial surface.
  - Absence of dentin darkening and/or discoloration, also no presence of colour contrast in remaining dental restorations.
  - Absence of dental surfaces with indentations, nor concavities or proximal retentions that could avoid the correct settlement of contact lenses.
  - Absence of hypoplasia stains on labial surfaces.
  - Is desirable that the 100% of dental substrate in direct contact with the ceramic remains on enamel.
  - Optimal oral hygiene condition.
  - Absence of incisal and occlusal wear surfaces.
  - Absence of Incisal dental fractures, nor fractures in anterior or posterior teeth restorations.
  - Anterior and canine occlusion/closure guide must be at sound tooth, never in ceramic.
  - Stable occlusion: bilateral contacts distributed in all posterior teeth with no edentulous area.
  - Absence of bruxism.
-



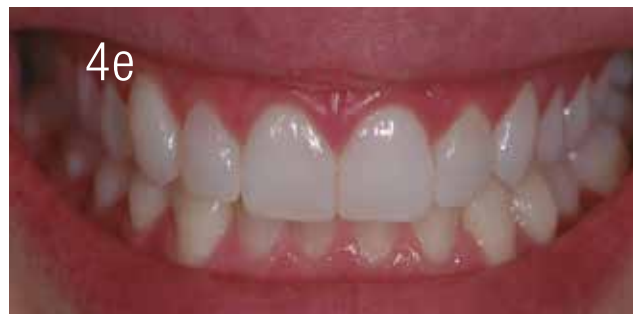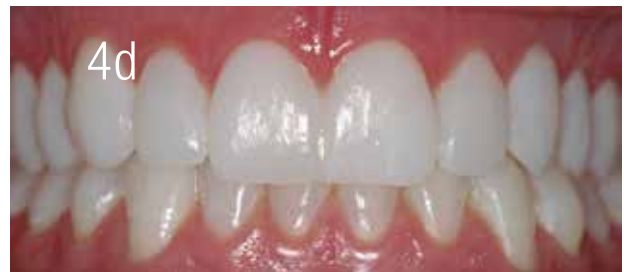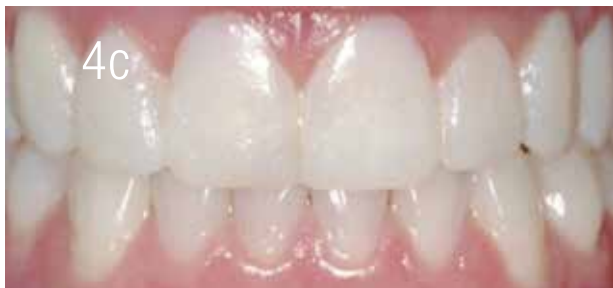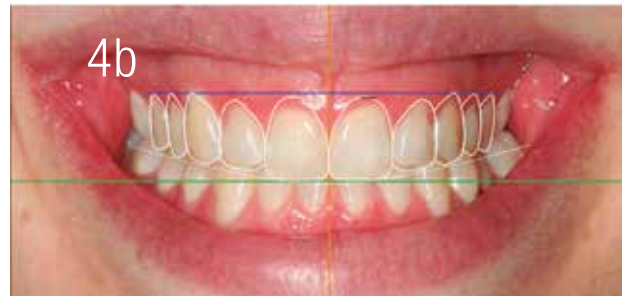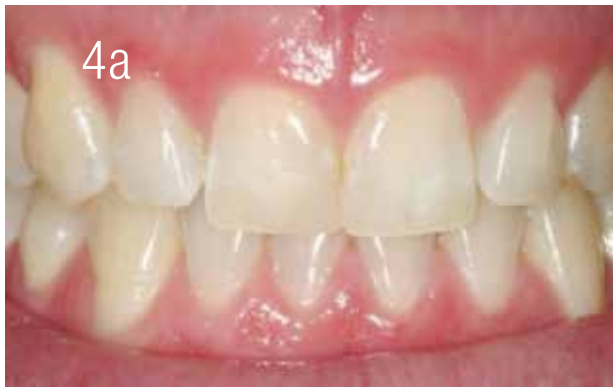**Figure 1.** SEM images of the surface of different light-cured resin cements (4500X). Some resin cements presents macro-particles in its composition, which difficulties polishing procedures. (A) AllCem Veneer (FGM, Brasil); (B) Choice 2 (Bisco, USA); (C) NX 3 (Kerr, USA); (D) RelyXVeneer (3M ESPE, USA); (E) VariolinkVeneer (IvoclarVivadent, Liechtenstein).



**Figure 2.** Contact Lenses before adhesive cementation. Observe the difference in thickness that influence in the polishing procedure of superior marginal seal. Image from Dr. Oséias Evangelista (OdontoDesign, Brazil).



**Figure 3.** Clinical follow-up of 3 years. (A) Vita Colour guide shows colour follow up in comparison with inferior incisors. A minor gingival inflammation is perceived in cervical area of the right superior central incisive. (B) Fine-grained diamond tips are used for finishing and polishing with the aid of a Gingival Protector Zekrya # 260 (Dentsply Maillefer, Switzerland). (C) evaluation of marginal seal after polishing procedure. Special polishing rubbers for lithium disilicate (LS Gloss # 1435, Jota, Switzerland) are applied to pre-polish area (D) and (E) high-gloss polishing.



**Figure 4.** (A) Clinical photographs before treatment. (B) Digital Smile Design. (C) Aesthetics trial performed by the mock-up technique. (D) Contact lenses trial. (E) Final treatment.

## REFERENCES

1. [Internet]. 2015 [cited 30 July 2015]. Available from: <http://://www.ncbi.nlm.nih.gov/pubmed/?term=ceramic+veneers+contact+lens>
2. Okida RC, Filho AJ, Barao VA, Dos Santos DM, Goiato MC. The use of fragments of thin veneers as a restorative therapy for anterior teeth disharmony: a case report with 3 years of follow-up. *J Contemp Dent Pract.* 2012;13(3):416-20.
3. Shuman I. Simplified restorative correction of the dentition using contact lens-thin porcelain veneers: a report of three cases. *Dent Today.* 2006;25(1):88-92.
4. Nash RW. The contact lens porcelain veneer. *Dent Today.* 2003;22(5):56-9.
5. Materdomini D, Friedman MJ. The contact lens effect: enhancing porcelain veneer esthetics. *J Esthet Dent.* 1995;7(3):99-103.
6. Peumans M, De Mnck J, Fieuws S, Lambrechts P, Vanherle G, Van Meerbeek B. A prospective ten-year clinical trial of porcelain veneers. *J Adhes Dent.* 2004;6(1):65-76.
7. Cardoso P, Decurcio R. *FACETAS, Lentes de contatos e fragmentos cerâmicos.* Editora Ponto. 568p. 2015.

**Guilherme Carpena Lopes DDS, MS, PhD<sup>1</sup>; Andressa Ballarin DDS<sup>2</sup>;  
José Carlos Aguiar<sup>3</sup>**

1. Associated Professor, School of Dentistry, Federal University of Santa Catarina, Brasil.
2. Director, MUDE Odontologia, Brasil.
3. OT Prótese, Recife, Brasil.

Prof. Dr. Guilherme Carpena Lopes, Rua Laurindo Januário da Silveira no 947, apto 34A, Lagoa da Conceição, 88062-200 Florianópolis, SC, Brasil. Tel: +55-48-3232-1816. Fax: +55-48-3222-0734. E-mail: guilhermelopes@ccs.ufsc.br

