



Revista de Epidemiologia e Controle de  
Infecção

E-ISSN: 2238-3360

reciunisc@hotmail.com

Universidade de Santa Cruz do Sul  
Brasil

Domingues Costa, Gabriel; Tailla Oliveira, Daniele; Brandão Almeida, Guilherme; Cataud  
Pacheco Pereira, Hugo; Scholante da Silva, Ana Barbara; Diniz, Jaciara; Almeida Silva,  
Pedro Eduardo

Extrapulmonary TB or sarcoidosis associated with TB? Case report

Revista de Epidemiologia e Controle de Infecção, vol. 8, núm. 4, octubre-diciembre, 2018,  
pp. 1-3

Universidade de Santa Cruz do Sul  
Santa Cruz do Sul, Brasil

Available in: <http://www.redalyc.org/articulo.oa?id=570463739015>

- How to cite
- Complete issue
- More information about this article
- Journal's homepage in [redalyc.org](http://redalyc.org)

[redalyc.org](http://redalyc.org)

Scientific Information System

Network of Scientific Journals from Latin America, the Caribbean, Spain and Portugal

Non-profit academic project, developed under the open access initiative

### Extrapulmonary TB or sarcoidosis associated with TB? Case report

*Tuberculose extrapulmonar ou sarcoidose associada a tuberculose? Relato de caso*

*Tuberculosis extrapulmonar o sarcoidosis asociada a la tuberculosis? Relato de caso*

<https://doi.org/10.17058/reci.v8i4.12860>

Recebido em: 20/11/2017

Aceito em: 27/11/2018

Disponível online: 01/12/2018

**Autor Correspondente:**

\*Gabriel Domingues Costa  
gabriel Domingues@gmail.com

285, Presidente Vargas Avenue -Block G1 - Apt  
202, CEP: 96202336, Rio Grande/RS, Brazil.

\*Gabriel Domingues Costa,<sup>1</sup> <https://orcid.org/0000-0001-7435-8046>  
Daniele Tailla Oliveira,<sup>1</sup> <https://orcid.org/0000-0001-7168-8963>  
Guilherme Brandão Almeida,<sup>1</sup>  
Hugo Cataud Pacheco Pereira,<sup>1</sup>  
Ana Barbara Scholante da Silva,<sup>1</sup>  
Jacira Diniz,<sup>1</sup> <https://orcid.org/0000-0001-6210-5658>  
Pedro Eduardo Almeida Silva,<sup>1</sup> <https://orcid.org/0000-0003-1666-1295>

<sup>1</sup>Universidade Federal do Rio Grande do Sul, Rio Grande, RS, Brasil.

## RESUMO

**Objetivos:** O presente relato tem como objetivo discutir o diagnóstico diferencial entre tuberculose e sarcoidose. **Descrição do caso:** Caso de um paciente do sexo masculino, 25 anos, que desenvolveu artrite granulomatosa e osteomielite com inflamação granulomatosa não caseosa sugestiva de sarcoidose. Vinte e quatro meses antes desse relato, o paciente teve resultados laboratoriais positivos para tuberculose pulmonar, no entanto, não foi tratado. **Conclusão:** Demonstramos como é necessário o acompanhamento do paciente após a realização de um teste diagnóstico para tuberculose e o desafio de confirmar um diagnóstico de sarcoidose em um paciente com tuberculose.

**Descritores:** Tuberculose. Sarcoidose. Artrite.

## ABSTRACT

**Objectives:** The present report aims to discuss the differential diagnosis between tuberculosis and sarcoidosis. **Case description:** The case of a 25-year-old male patient who developed granulomatous arthritis and osteomyelitis with nonnecrotizing granulomatous inflammation suggesting a sarcoidosis. Twenty-four months before this report, he had positive laboratory results to pulmonary tuberculosis, however, he was not treated. **Conclusion:** This case report demonstrates how necessary is the follow-up of patient after the performance of a diagnostic testing to tuberculosis, and the challenge to confirm a diagnosis of sarcoidosis in a patient with tuberculosis.

**Keywords:** Tuberculosis. Sarcoidosis. Arthritis.

## RESUMEN

**Objetivos:** El presente relato tiene como objetivo discutir el diagnóstico diferencial entre tuberculosis y sarcoidosis. **Descripción del caso:** Caso de un paciente del sexo masculino, 25 años, que desarrolló artritis granulomatosa y osteomielitis con inflamación granulomatosa no caseosa sugestiva de sarcoidosis. Veinticuatro meses antes de ese relato, el paciente tuvo resultados de laboratorio positivos para la tuberculosis pulmonar, por lo que no fue tratado. **Conclusión:** Demostramos cómo es necesario el acompañamiento del paciente después de la realización de una prueba diagnóstica para tuberculosis y el desafío de confirmar un diagnóstico de sarcoidosis en un paciente con tuberculosis.

**Palabras Clave:** Tuberculosis. Sarcoidosis. Artritis.

## INTRODUCTION

Sarcoidosis is a multisystem disorder pathologically characterized by nonnecrotizing granulomatous inflammation. Clinical and histopathological similarities between sarcoidosis and tuberculosis (TB) suggest that *Mycobacterium tuberculosis* (*Mtb*) could be involved in its pathogenesis.<sup>1,2</sup>

The true incidence and prevalence of musculoskeletal manifestation in sarcoidosis has not been elucidated, because the diagnosis may be difficult when the patient presents only joint complaints. For this reason, the presence of sarcoidosis is established only after more commonly involved organs (i.e. lungs) are affected.<sup>3</sup>

Likewise, the diagnosis of extrapulmonary TB can be challenging. Clinical samples may be difficult to obtain while microbiological diagnosis tends to be late.<sup>4</sup> Because of this, rare cases of granulomatous arthritis are diagnosed in the chronic phase and with a slow therapeutic response.<sup>1</sup>

The present report shows a case of granulomatous arthritis and osteomyelitis with nonnecrotizing granulomatous in a patient with TB without treatment for long time.

## CASE DESCRIPTION

In June of 2015, the patient who was a 25-year-old man, drug user, and smoker, was attended in the ambulatory of HU-FURG Hospital when the clinicians decided to investigate the possibility of pulmonary TB by microscopy (BAAR), culture (MGIT) and GeneXpert (Xpert) tests. All the tests results were positive, but the patient did not return to the follow up and was not contacted by the hospital.

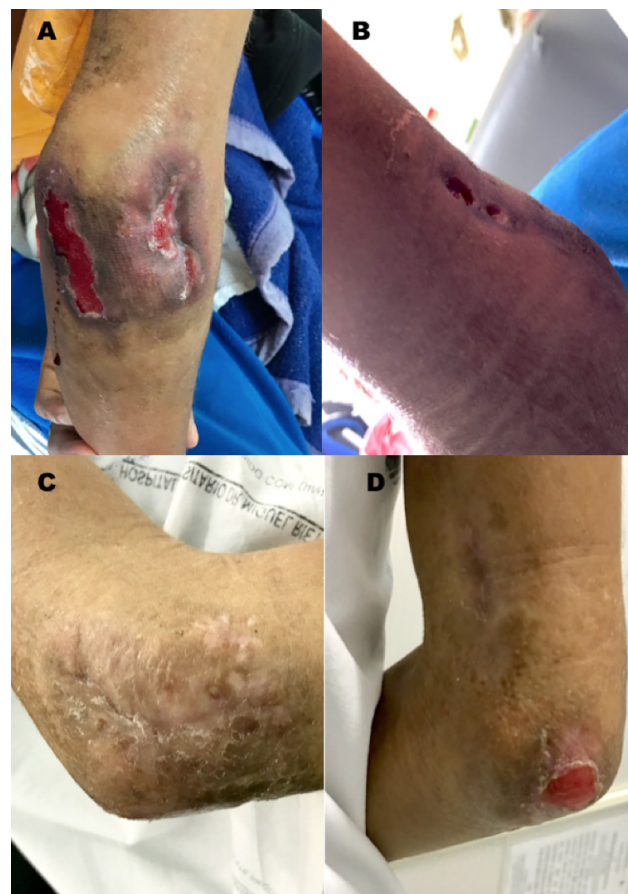Thirteen months later, the patient returned to the hospital due to dry cough, dyspnea and night sweats. He was hospitalized for 25 days for clinical investigation. On July 26<sup>th</sup>, due the clinical sample scarce, only microscopy of sputum to TB was performed. Microscopy was negative. On 07/28/2016, the microscopy, the culture and the Xpert of bronchoalveolar lavage were performed. Microscopy and Xpert's were negative. The patient was discharged from the hospital on 08/03/2016, with indication to take a biopsy of mediastinal ganglion, which was carried out on 10/03/2016. The result of the histopathology was delivered on 10/05/2016, and reported a nodule with chronic inflammatory granulomatous process, nonnecrotizing, typical of sarcoidosis. The microscopy was negative.

This result supported the diagnostic of sarcoidosis. The patient was referred to a pulmonology clinic to continue propaedeutic and it was prescribed prednisone 5mg/day. In the meantime, on 09/09/2016, the result of culture of bronchoalveolar lavage solicited on 07/28/2016 was delivered as positive to *Mtb*, but any clinician did not check it. In this time the patient was missing again.

On 07/10/2017, the patient returned to the hospital due to a sharp pain in the right elbow with insidious evolution in seven months. He also reported daily fever, night sweats, and a weight loss. The physical examination showed ulcerative lesions (Figure 1A) and fistulas (Figure 1B) in the right elbow, with purulent drainage, severe pain and limited active and passive range of motion. Laboratory

results showed white blood count normal, HIV test negative and VDRL positive 1/16. Fluid from the elbow was collected, blood cultures were performed, and the treatment was started with clindamycin and oxacillin. The treatment for syphilis was accomplished with benzathine penicillin.

Computed tomography showed the elbow joint

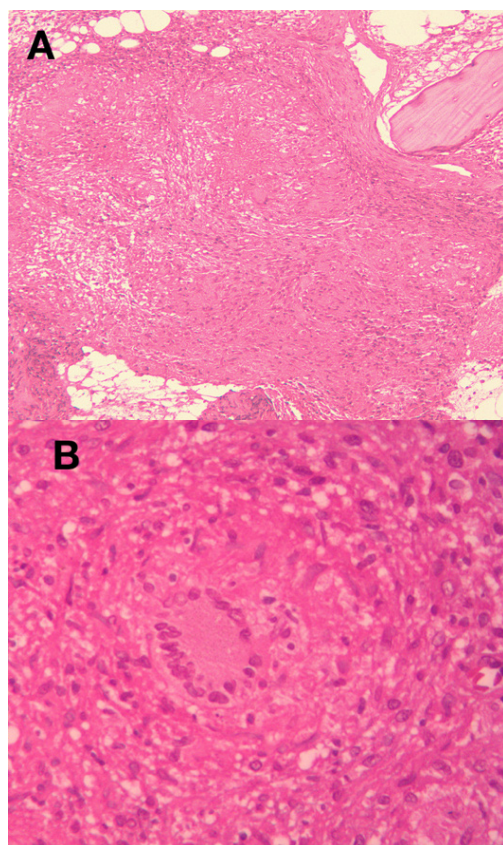


**Figure 1.** A) Right elbow posterior view with presence of two plates with irregular borders, hyper-chromic, with ulcerative center of flat erythematous bottom. B) Posteromedial region with presence of two fistulas. C) Posterolateral view with presence of residual hyperchromic macula. D) In the posterior region, there is reduction of ulceration and closure of fistulas.

space narrowed, specifically in the radiocapitellar compartment, where erosions and subchondral bone sclerosis and small adjacent aerial intraosseous collections were observed, besides a small effusion with intra articular gas. Blood cultures and culture of fluid from the elbow detected no bacterial growth.

The patient didn't show any significant improvement after fourteen days of antibiotic treatment, so he was submitted to a bone biopsy and Xpert was performed, which detected *Mtb*. The pathology test showed chronic suppurate osteomyelitis with acute exacerbation, and numerous epithelioid granulomas (Figure 2). After 15 days, the culture was positive to *Mtb*. The treatment with rifampicin, isoniazid, pyrazinamide, and ethambutol was initiated with outpatient follow-up.





**Figure 2.** **A)** Fragment of osseous tissue presented in the intertrabecular spaces, hematopoietic and fatty marrow replaced by noncaseating epithelioid granulomas (Hematoxylin-eosin, 200X). **B)** Langhans giant cells placed in the center, surrounded by a mantle, which is poor in lymphocytes and rich in epithelioid macrophages (Hematoxylin-eosin, 400X).

The patient did not appear at the first visit after being discharged from the hospital. In the second visit, he was in the seventh week of RHZE scheme with good clinical improvement. The ulcerative lesions of the elbow were practically healed (Figure 1B). There was closure of the fistulas (Figure 1D), and he denied any pain, fever, or night sweats. The patient remained with significant reduction of his elbow range of motion and he was referred for orthopedic and physiotherapy services.

## CONCLUSION

Herein, we presented a case of a patient who developed granulomatous arthritis and osteomyelitis with nonnecrotizing granulomatous inflammation suggesting a sarcoidosis. However, through the analysis of earlier records, it was found that this patient had TB-positive laboratory tests two years earlier but he has never been treated.

Sarcoidosis and TB are granulomatous and immune mediated diseases. It has been suggested that *Mtb* can be involved in the sarcoidosis pathogenesis. Some studies have reported patients with TB preceding the development of

sarcoidosis or concurrent presence of both diseases.<sup>5,6</sup>

It is often difficult to differentiate sarcoidosis from TB. Histopathologic definitions of sarcoidosis are nonspecific, because sarcoid granulomas are not pathologically distinct by simple microscopic or histochemical analysis from granulomas due to other causes.<sup>7</sup>

Although we cannot exclude the possibility of the diagnosis of sarcoidosis, it is more probable that this case was related to extrapulmonary TB as result of the long period (two years) without treatment. Molecular platforms, such as geneXpert, are an excellent approach to fast and accurate diagnostic of TB. However, it's important to highlight that these methods also have limitations (i.e. samples extrapulmonary) and almost 27% of the sarcoid tissue may show the presence of mycobacterial nucleid acids.<sup>8,9</sup>

The different diagnostics between sarcoidosis and TB is a challenge, particularly in high burden TB settings. Although the high-tech has increased the accuracy to TB detect in less time, this cannot be enough. It's necessary a proper follow-up of patient after the diagnostic to introduce correct and early treatment.

## REFERENCES

1. Yee AM. Sarcoidosis: Rheumatology perspective: Best Pract Res Clin Rheumatol. 2016 Apr;30(2):334-356. doi: 10.1016/j.berh.2016.07.001
2. Saboor SA, Johnson NM, McFadden J. Detection of mycobacterial DNA in sarcoidosis and tuberculosis with polymerase chain reaction: Lancet 1992;339(8800):1012-5. doi: 10.1016/0140-6736(92)90535-B
3. Zisman DA, Shorr AF, Lynch JP 3<sup>rd</sup>. Sarcoidosis involving the musculoskeletal system. Semin Respir Crit Care Med. 2002;23(6):555-70. doi: 10.1055/s-2002-36520
4. Blankley S, Graham CM, Turner J, et al. The Transcriptional Signature of Active Tuberculosis Reflects Symptom Status in Extra-Pulmonary and Pulmonary Tuberculosis: PLoS One 2016; 5;11(10):e0162220. doi: 10.1371/journal.pone.0162220
5. Song Z, Marzilli Z, Greenlee BM, et. al. Mycobacterial catalase- peroxidase is a tissue antigen and target of the adaptive immune response in systemic sarcoidosis: J Exp Med. 2005; 201(5):755-67. doi: 10.1084/jem.20040429
6. Mortaz E, Masjedi MR, Matroodi S, et. al. Concomitant patterns of tuberculosis and sarcoidosis. Tanaffos Journal 2013;12(4):6-9. <https://www.ncbi.nlm.nih.gov/pmc/articles/PMC4153265/>
7. Rosen Y. Pathogy of sarcoidosis: Semin Respir Crit Care Med 2007;28(1):36-52. doi: 10.1055/s-2007-970332
8. Gupta D, Agarwal R, Aggarwal AN, et al. Molecular evidence for the role of mycobacteria in sarcoidosis: a meta-analysis: Eur Respir J 2007;30(3):508-16. doi: 10.1183/09031936.00002607
9. Dhoria S, Gupta N, Bal A, et al. Role of Xpert MTB/RIF in differentiating tuberculosis from sarcoidosis in patients with mediastinal lymphadenopathy undergoing EBUS-TBNA: a study of 147 patients. Sarcoidosis Vasc Diffuse Lung Dis. 2016;33(3):258-266. <https://www.ncbi.nlm.nih.gov/pubmed/27758992>