



Tropical and Subtropical Agroecosystems

E-ISSN: 1870-0462

ccastro@uady.mx

Universidad Autónoma de Yucatán

México

Cepeda-Palacios, Ramón; González, Angélica; López, Alberto; Ramírez-Orduña, Juan M.;
Ramírez-Orduña, Rafael; Ascencio, Felipe; Dorchies, Philippe; Angulo, Carlos
IDENTIFICATION AND CHARACTERIZATION OF Eimeria spp. DURING EARLY
NATURAL INFECTION IN GOAT KIDS IN BAJA CALIFORNIA SUR, MEXICO
Tropical and Subtropical Agroecosystems, vol. 18, núm. 3, 2015, pp. 279-284
Universidad Autónoma de Yucatán
Mérida, Yucatán, México

Available in: <http://www.redalyc.org/articulo.oa?id=93944043004>

- How to cite
- Complete issue
- More information about this article
- Journal's homepage in redalyc.org

redalyc.org

Scientific Information System

Network of Scientific Journals from Latin America, the Caribbean, Spain and Portugal

Non-profit academic project, developed under the open access initiative



IDENTIFICATION AND CHARACTERIZATION OF *Eimeria* spp. DURING EARLY NATURAL INFECTION IN GOAT KIDS IN BAJA CALIFORNIA SUR, MEXICO

[IDENTIFICACIÓN Y CARACTERIZACIÓN DE *Eimeria* spp. DURANTE LA INFECCIÓN NATURAL TEMPRANA EN CABRITOS EN BAJA CALIFORNIA SUR, MÉXICO]

Ramón Cepeda-Palacios¹, Angélica González¹, Alberto López¹, Juan M. Ramírez-Orduña¹, Rafael Ramírez-Orduña¹, Felipe Ascencio³, Philippe Dorchies², Carlos Angulo^{3*}

¹Laboratorio de Sanidad Animal, Universidad Autónoma de Baja California Sur, Carr. Sur km. 5.5., Col. Mezquitito, La Paz, B.C.S. 23080, Mexico (rcepeda@uabcs.mx)

²Ecole Nationale Vétérinaire de Toulouse, 23 Chemin des Capelles, 31076, Toulouse Cedex 03, France.(p.dorchies@envt.fr)

³Grupo de Inmunología & Vacunología. Centro de Investigaciones Biológicas del Noroeste, SC. Instituto Politécnico Nacional 195, Playa Palo de Santa Rita Sur, La Paz, B.C.S. C.P. 23096, México. Email: eangulo@cibnor.mx.

.*Corresponding author

SUMMARY

The aim of this study was to characterize the natural infection by *Eimeria* spp. in goat kids, and to describe some pathophysiological responses to eimeriosis in kids under intensive rearing conditions in B.C.S., Mexico. Nineteen adult crossbred does naturally infected with mixed *Eimeria* spp. and 20 Anglo Nubian x Creole crossbred kids were used. Oocyst per gram of feces (OPG) and identification of *Eimeria* species were determined in does (during the pre-kidding and post-kidding periods) and kids. Clinical signs, hematocrit, hemoglobin and alkaline phosphatase activity in blood serum were evaluated. OPG (mean±SD) was significantly higher ($P<0.05$) in pre-kidding ($9,478\pm7,599$) than in post-kidding ($5,313\pm2,909$) period. Oocyst elimination in feces began at age 59 ± 9 days in kids. Eimerian species identified were *E. arloingi*, *E. jolchijevi*, *E. ninakohlyakimovae*, *E. hirci*, *E. christenseni* and *E. alijevi*. Kids were humanely sacrificed to evaluate pathological lesions. Intestinal lesions and lesion severity showed differences in duodenum, jejunum, ileum, cecum and colon, being more severe in duodenum. In conclusion, OPG increased during the late pregnancy in does which favored a doe-kid transmission mechanism. Our results support the notion of *Eimeria* reproduction rhythms during the late pregnancy period in goats, and this reproduction contribute to vertical transmission of *Eimeria* to the newborn. However, coccidian outbreaks are

developed and clinically observed only when stressing factors such as when weaning occur. Coccidia had devastating effects on the intestine of kids, which might cause long-term permanent malabsorption consequences.

Key words: *Eimeria*; infection; goat; kids; pathology lesions.

RESUMEN

El objetivo del estudio fue caracterizar la infección natural temprana por *Eimeria* spp. en cabritos, y describir respuestas fisiopatológicas en cabritos mantenidos bajo estabulación en B.C.S., México. Se utilizaron 19 cabras adultas cruzadas infectadas y 20 cabritos cruzados de Anglo-NubioxCriollo. Se determinó la cuenta de ooquistes por gramo de heces (OPG) y las especies de *Eimeria* en cabras (antes y después del parto) y en sus crías. Se registraron los signos clínicos, hematocrito, hemoglobina y actividad de fosfatasa alcalina en suero. Las cuentas de OPG (media±DE) fueron más altas ($P<0.05$) durante el periodo pre-parto ($9,478\pm7,599$) con parado con el post-parto ($5,313\pm2,909$). La eliminación de ooquistes en cabritos inició a la edad de 59 ± 9 d. Las especies de *Eimeria* identificadas en las madres y sus crías fueron *E. arloingi*, *E. jolchijevi*, *E. ninakohlyakimovae*, *E. hirci*, *E. christenseni* y *E. alijevi*. Las lesiones intestinales y su severidad mostraron diferencias en duodeno, yeyuno, ileon,

ciego y colon, siendo más severas en duodeno. En conclusión, nuestros resultados soportan la idea que los ritmos de reproducción de *Eimeria* durante el periodo de lactancia tardía en cabras, y que esta reproducción contribuye a la transmisión vertical de *Eimeria* al cabrito recién nacido. Sin embargo, los brotes de coccidia se desarrollan y se observan

clínicamente solo cuando factores estresantes ocurren como el destete ocurren. La coccidiosis tiene efectos serios sobre el intestino de los cabritos, que quizá tiene consecuencias de mala absorción a largo plazo.

Palabras clave: *Eimeria*; infección; cabras; cabritos; lesiones.

INTRODUCTION

Coccidiosis caused by *Eimeria* is a worldwide economically important parasitic disease with high prevalence in goats (Abo-Shehadeh and Abo-Farieha, 2003; Rocha *et al.*, 2012). It has been demonstrated that coccidiosis reduces seriously body weight gain, welfare, the general productive performance of goats, and in some cases, death may also occur if animals are not treated (Ramírez-Bibriesca *et al.*, 2001). Goat *Eimeria* species have different reproductive rate and pathogenicity according to the site of infection, which result in different host pathophysiological responses and histopathological lesions (Hoste, 2001; Dai *et al.*, 2006).

During the early weeks of kids life, Eimeriosis is acquired by suckling kids (Matthews, 2009). Adults are the source of infective oocysts under intensive conditions, from which pregnant does probably are the main oocyte-producers. However, this hypothesis has not been clearly demonstrated so far. Therefore the aims of the present study were (1) to characterize the early natural infection by *Eimeria spp.* in goat kids (2) to analyze the oocyst production from pregnant does, and (3) to describe some pathophysiological responses in kids naturally infected under intensive rearing conditions in Baja California Sur, México.

MATERIALS AND METHODS

Location

This study was conducted at the Universidad Autónoma de Baja California Sur, La Paz, B.C.S. in Northwestern México.

Animals and management

All coccidian infections were recorded in a dual purpose goat farm (milk and meat production) under intensive rearing conditions. Goats were naturally bred during October 2011 and kiddings occurred in pens by March 2012. Pregnant Saanen x Nubian does ($n=19$) were housed in an open pen measuring 8×6 m,

including a 5×3 m shaded area, earth floor and drinking trough. Goats diagnosed to be infected with mixed *Eimeria spp.* were randomly selected for *Eimeria* sampling.

Nineteen Saanen x Nubian crossbred kids were used. All kids were reared together with the dams and suckled naturally until they reached 10 kg body weight (age 45 d on the average), then they were weaned.

Feeding and hygiene in housing pens

Does were fed with 1.5 kg/head/day. Alfalfa hay was offered using feeders to ensure to minimize the risk of infection of the kids. Additionally, adult goats were supplemented with 300 g of concentrate with 20% crude protein. At 30 days of age kids received a supplement with alfalfa:concentrate (60:40) in a creep-feeding crate. Fresh water and mineral blocks were offered *ad libitum*. At two weeks intervals, feces, forage residues, and detritus found on the pen ground were removed and replaced with a clean sand bed 5 cm thick.

Analysis of *Eimeria* infection

The does were sampled for feces, which were collected directly of rectum (3 g). Weekly samplings initiated two weeks before kidding until 70 d post kidding. Kids were sampled weekly, beginning at seven days post birth and until they were 70 d old. Procedures for oocyst presence determination (in fresh coproparasitoscopies), oocyst count (McMaster modified technique), and *Eimeria* species identification (sporulation and morphometry) in feces were performed as previously described (Gordon and Whitlock, 1939; MAFF, 1986; da Costa, 1987).

Clinical signs development

Both, does and kids were checked daily in the morning at 08:00 for clinical signs associated to *Eimeria spp.* The presence of clinical signs of the disease such as diarrhea, anorexia, depression and weakness were visually registered.

Intestinal lesions

At the end of the study, six kids infected with *Eimeria* were humanely slaughtered. Lesion location (i.e. duodenum, jejunum, ileum, cecum and colon) frequency and severity scoring were recorded at necropsy. Severity of the pathological lesions due to *Eimeria* was classified according to the following scoring: 0= no lesion; 1= slight, 2 =moderate, 3= severe.

Blood parameters

Blood samples were collected in kids (before and after fecal oocyst production was detected). For this purpose, experimental kids were fasted during 12 h. Blood samples were obtained by jugular vein venipuncture and collected in heparinized tubes. Hematocrit, total hemoglobin and total alkaline phosphatase activity in blood serum were determined by triplicate as described elsewhere (Bowers and McComb, 1975; Voigt and Swist, 2011; Randox Laboratories Ltd., Ardmore, Crumlin, UK).

Statistical analysis

Descriptive analysis of *Eimeria* spp. oocyst presence in does and kids was performed for samplings, as well for age progression in kids. A one-way analysis of variance was used to compare egg counts recorded in does prior and after kidding. The model applied was:

$$Y_{ij} = \mu + P_i + \varepsilon_{ij}$$

where

Y was egg count which was transformed to Log_{10} scale in order to stabilize the variance for comparison of egg counts. P was the effect of the period pre and post kidding and ε_{ij} was the variation due to sampling error.

Student t test was used to compare the blood parameters of kids prior vs. after the *Eimeria* infection. All data were analyzed using the Statistica software (Statsoft, 1998).

RESULTS

Dynamics of *Eimeria* spp. infection

All adult goats (100%) were found infected during the pre- and post-kidding periods. OPG (mean \pm SD) was significantly higher ($P<0.05$) in pre-kidding ($9,478 \pm$

$7,599$) than in post-kidding ($5,313 \pm 2,909$) goats. Oocyst elimination in kid feces was firstly observed at age 59 ± 9 d (Figure 1).

Eimeria spp identification and frequency

Both, does and kids hosted mixed infections of *Eimeria*. In does (Figure 2), the main species of *Eimeria* identified were *E. arloingi* 36.8%, *E. jolchijevi* 15.5%, *E. ninakohlyakimovae* 14.67 %, *E. hirci* 13.6 %. Similarly, (data not showed in figures) *E. arloingi* 36.8%, *E. jolchijevi* 14.0%, *E. ninakohlyakimovae* 19.1%, *E. hirci* 8.7%; also, *E. christenseni* (9.4%) and *E. alijevi* (7.0%) were found in kids.

Development of clinical signs and intestinal lesions

Adult goats did not show any apparent clinical signs during pre- and post- kidding periods. In kids, no diarrhea signs before weaning were observed, however, four kids with high oocyst burdens showed signs of anorexia, depression and weakness (data not shown).

Lesions found at necropsy examinations were more frequent in duodenum (33.3%), jejunum (26.0%) and ileum (27.1%) and in a lesser extent in cecum (1.04%) and colon (12.5%). Severity of lesions showed significant differences according to the anatomical localization (Table 1). Most lesions caused by *Eimeria* infection were considered as slight (44.8%), followed by moderate (34.37%) and severe (20.83%). The number and type of lesion also varied with localization (Table 1). In duodenum, catarrhal enteritis and petechia were more frequent. In jejunum, petechia and suffusions were more often found, while catarrhal enteritis and petechia were mostly observed in ileum. On the other hand, suffusions were more important in cecum as catarrhal enteritis was in colon. Metaplasia foci were generally not frequent in the digestive tract, except in duodenum and jejunum.

Blood parameters

No statistical differences ($P>0.05$) were observed prior and after oocyst elimination in hematocrit (mean = 32.5%) and hemoglobin levels (8.73 g/dL and 6.64 g/dL, respectively) in kids. By contrast, alkaline phosphatase was found reduced ($P<0.01$) in oocyst excreting (77 ± 74 IU/L) compared to non-excreting (584 ± 439) kids.

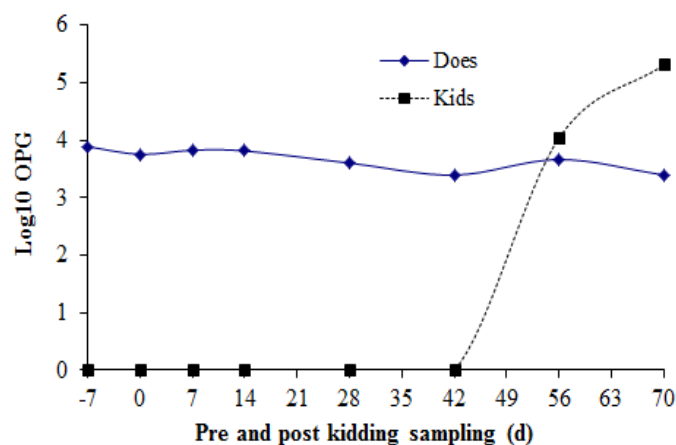


Figure 1. Log transformed mean fecal oocyst counts of *Eimeria* spp. in does and kids during the pre- and post-kidding periods under intensive conditions in Baja California Sur, Mexico.

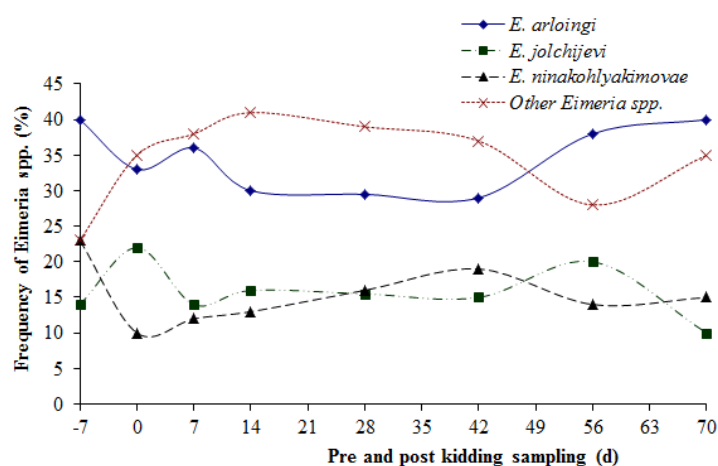


Figure 2. Relative frequency of *Eimeria* species in the feces of adult goats during the pre- and post-kidding periods under intensive conditions in Baja California Sur.

Table 1. Severity¹, location and frequency of lesions found in digestive tract of goat kids infected with *Eimeria* spp. under intensive conditions in Baja California Sur.

Lesion	Anatomic location				
	Duodenum	Jejunum	Ileum	Cecum	Colon
Mean of severity (S.D.)	1.7(0.78)	1.8(0.80)	2.0(0.77)	2(0.0)	1.2(0.38)
Metaplasias (%)	18	20	0	0	0
Catharral enteritis (%)	28	24	35	0	58
Petequiae (%)	28	28	35	0	25
Sufussions (%)	26	28	30	100	17
Total	100	100	100	100	100
n by location	32	25	26	1	12

¹Lesion severity was classified according to the following scoring: 0=no lesion, 1= slight, 2 =moderate, 3= severe.

DISCUSSION

In the first study, it was found that both does and kids were infected with *Eimeria spp.* Adult goats showed a moderate and variable intensity of infection (average ~5300 and ~9500 OPG), during the pre- and post-kidding periods, respectively. It has been pointed out that OPG variation in adult goats depends on many factors (Koudela and Boková, 1998; Ruiz *et al.*, 2006). Although the level of OPG observed at the end of the pregnancy of does was similar, the rapid increase of OPG levels in feces of kids after kidding seems to be related to the risk of kids to acquire the infection and develop coccidiosis during the first weeks of life (Ramírez-Bibriesca *et al.*, 2001). These findings agree with our results since *Eimeria ssp.* oocyst elimination began about eight-week old in kids. *Eimeria* infection analysis showed the highest frequency for *E. arloingi*, followed by *E. jolchijevi*, *E. ninakohlyakimovae* and *E. hirci* in both does and kids. A high relative abundance of *E. arloingi*, *E. ninakohlyakimovae* and *E. hirci* as well as a lower presence of *E. caprina*, *E. caprovina*, *E. alijevi*, *E. aspheronica* and *E. christenseni* has been commonly observed in goats under different environment (Abo-Shehadeh and Abo-Farieha, 2003; Rocha *et al.*, 2012), and probably it may be related to differences in *Eimeria* species virulence. Interestingly, the most pathogenic species in goats *E. arloingi* and but mainly *E. ninakohlyakimovae*, which cause severe clinical signs (Koudela and Boková, 1998; Ruiz *et al.*, 2013) were found in our first study. The diarrhea, anorexia, weakness and weight loss were only observed in the highest parasitic infected kids. As it is known, clinical signs (and eventually dead) are also reflecting the severity of lesions caused by species of *Eimeria* in infected kids (Dai *et al.*, 2006; Matthews, 2009). In our study (with exception of duodenum), results were similar to those reported by Tafti and Mansourian (2008) in which lesions were mainly observed in the jejunum and ileum, and often in cecum. According to Dai *et al.* (2006), such damages reflect epithelial cell loss, absorptive epithelium atrophy, enteritis from weak to subacute with multifocal infiltration of lymphocytes in the small and large intestines, as well as lymphoid hyperplasia in mesenteric lymphatic nodules and colicistitis. Those lesions may destroy huge areas of intestinal epithelium, causing loss of blood and secondary infections that finally might provoke death of goats (Young *et al.*, 2011). Lesions caused by *Eimeria* were in close association with the appearance of developing oocysts in the intestinal epithelium. These developing oocysts could be easily observed under the light microscope. By contrast, the absence of oocysts in feces was not always related with the progression of an infection process, nor the OPG

burden was always related with the severity of clinical signs showed by the kids. Thus, it would appear that the sampling protocol is important in order to have a better idea of the coccidial infection status of the animal. Sampling the feces twice a day during 3-5 days appears to be necessary to gain a better understanding of the infection process in kids. On the other hand, package cell volume remained unaffected before or after beginning fecal oocyst elimination; however, hemoglobin was reduced suggesting the beginning of development of anemia in infected kids (Dauguschies and Najdrowski, 2005; Voigt and Swist, 2011). In addition, alkaline phosphatase activity during *Eimeria spp.* infection in kids was reduced, which coincides with previous reports in cattle and goats (Dauguschies and Najdrowski, 2005; Dai *et al.*, 2006).

CONCLUSIONS

Our results support the notion of *Eimeria* reproduction rhythms during the late pregnancy period in goats, and this reproduction contribute to vertical transmission of *Eimeria* to the newborn. However, coccidian outbreaks are developed and clinically observed only when stressing factors such as when weaning occur. *Coccidia* had devastating effects on the intestine of kids, which might cause long-term permanent malabsorption consequences.

Acknowledgement

The authors are grateful with Technician Ana E. Valverde Onofre for valuable assistance in field and laboratory work.

REFERENCES

- Abo-Shehadeh, M., Abo-Farieha, H. 2003. Prevalence of *Eimeria* species among goats in Northern Jordan. Small Ruminant Research. 49:109-113.
- Bowers, G.N., McComb, R.B. 1975. Measurement of total alkaline phosphatase in human serum. Clinical Chemistry. 21:1988-1995.
- da Costa, A.J. 1987. Diagnóstico laboratorial em parasitologia. I. Helminthologia. UNESP. Brasil.
- Dai, Y.B., Liu, X.Y., Liu, M., Tao, J.P. 2006. Pathogenic effects of the coccidium *Eimeria ninakohlyakimovae* in goats. Veterinary Research Communications. 30:149-160.
- Dauguschies, A., Najdrowski, M. 2005. Eimeriosis in cattle: Current understanding. Journal of Veterinary Medicine. 52:417-427.
- Gordon, H.M., Whitlock, H.V. 1939. A New technique for Counting Nematode Egg in Faeces. Journal

- of the Council for Scientific and Industrial Research. 12:50-52.
- Hoste H. 2001. Adaptive physiological processes in the host during gastrointestinal parasitism. *International Journal of Parasitology*. 31:231-244.
- Koudela, B., Boková, A. 1998. Coccidiosis in goats in the Czech Republic. *Veterinary Parasitology*. 76:261-267.
- Ministry of Agriculture, Fisheries and Food, UK (MAFF). 1986. *Manual of Veterinary Parasitological Laboratory Techniques*. Reference book 418. Her Majesty's Stationery Office. UK.
- Matthews, J. 2009. *Diseases of the goats*. 3rd Ed. Wiley-Blackwell. UK.
- Ramírez-Briebesca, J.E., Tórtora, J.L., Hernández, L.M., Huerta, M. 2001. Main causes of mortalities in dairy goat kids from the Mexican plateau. *Small Ruminant Research*. 41:77-80.
- Rocha, C.A.C., Teixeira, M., Monteiro, J.P., Gomes, L.C.W. 2012. *Eimeria* species in dairy goats in Brazil. *Veterinary Parasitology*. 183:356-358.
- Ruiz, A., González, J.F., Rodríguez, E., Martín, S., Hernández, Y.I., Almeida, R., Molina, J.M. 2006. Influence of climatic and management factors on *Eimeria* infections in goats from semi-arid zones. *Journal of Veterinary Medicine B*. 53:399-402.
- Tafti, A.K., Mansourian M., 2008. Pathologic lesion of naturally occurring coccidiosis in sheep and goats. *Comparative Clinical Pathology*. 17:87-91.
- Voigt, G.L., Swist, S.L. 2011. *Hematology Techniques and Concepts for veterinary technicians*. Wiley-Blackwell. USA.
- Young, G., Alley, M.L., Foster, D.M., Smith, G.W. 2011. Efficacy of amprolium for the treatment of pathogenic *Eimeria* species in Boer goat kids. *Veterinary Parasitology*. 178:346-349.

Submitted February 20, 2013 – Accepted December 08, 2015